

Original Article

Clinical effect of sports rehabilitation on postoperative recovery of anterior cruciate ligament injury caused by motion

Cao Yang^{1,2}, Jeho Song², Haibin Xiao^{1,2}, Maolin Yang^{1,2}, Tian Cheng^{1,2}

¹Shangrao Normal University, Shangrao, Jiangxi, China; ²Department of Sports Science, Wonkwang University, Iksan-si, Republic of Korea

Received May 6, 2020; Accepted July 11, 2020; Epub October 15, 2020; Published October 30, 2020

Abstract: Objective: To clinically investigate the effect of sports medicine rehabilitation combined with traditional Chinese medicine on the recovery of anterior cruciate ligament injury after arthroscopic reconstruction. Methods: A total of 80 patients who underwent arthroscopic reconstruction of the anterior cruciate ligament in the knee were divided into the control group (CG, n=40) and the observation group (OG, n=40) by randomization. The CG received rehabilitation training only, while the OG received rehabilitation training + Chinese medicine treatment. The pain intensity of both groups was measured before the operation, and again at 3 d, 7 d, 14 d and 3 months after operation by a visual analogue scale, joint swelling was measured at 3 d, 4 d and 17 d after operation by joint cavity puncture and extraction, knee joint function was measured before and 3 months after operation by Lysholm, as well as motor ability, symptoms, and knee function were assessed before and after 3 months of operation by the 2000 scoring system from the International Knee Documentation Committee. Results: Compared with the CG, the OG had lower pain scores in both motion and at rest, 3 d, 7 d and 14 d after operation ($P<0.05$). The joint range motion in the OG was 95.13 ± 6.13 and 138.16 ± 7.61 at 7 d and 3 months after operation, respectively, which was higher than 86.99 ± 7.09 and 121.80 ± 8.02 in the CG ($P<0.05$). Little difference was found in terms of knee joint function between the two groups at 3 d, 7 d and 14 d after operation ($P>0.05$). Three months after operation, both groups reported higher scores for symptoms, athletic ability and knee function, and those in the OG were significantly better than the CG ($P<0.05$). Conclusion: Rehabilitation training combined with traditional Chinese medicine after arthroscopic reconstruction of the anterior cruciate ligament can effectively reduce patients' pain, swelling, and improve the function in the knee.

Keywords: Anterior cruciate ligament, rehabilitation training, exercise therapy, traditional Chinese medicine

Introduction

Anterior cruciate ligament injury of the knee can reduce the stability of the knee joint, which easily causes damage to the meniscus and articular cartilage injury if not treated in time; this can lead to the occurrence of osteoarticular diseases [1]. The anterior cruciate ligament is the most vulnerable part of the knee. Clinically, anterior cruciate ligament injuries along with strain and laceration are common in competitive sports [2]. In the knee joint, the anterior cruciate ligament connects the tibia and the femur to protect the tibia from sudden displacement and helps it align with other surrounding structures to ensure normal movement of the knee joint [3].

At present, minimally invasive surgery is most often used in the treatment of anterior cruciate ligament injury. Postoperative rehabilitation training is controversial. Although arthroscopic reconstruction of the anterior cruciate ligament has significant clinical effects, some patients suffer from postoperative pain and joint swelling. Rehabilitation therapy is therefore often applied to improve knee joint function and relieve pain [4].

In recent years, China's rehabilitation medicine has developed rapidly. Postoperative rehabilitation training, especially in early stages, can effectively improve clinical efficacy and prognosis [5]. Early rehabilitation training can effectively prevent articular dyskinesia caused by

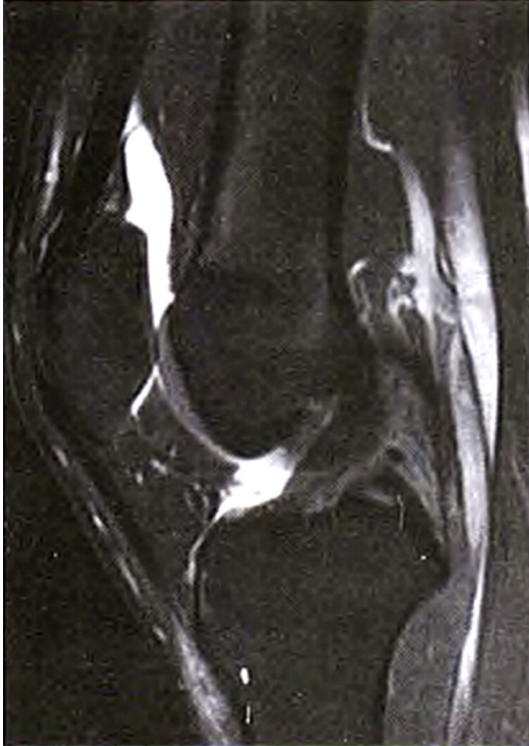

Figure 1. MRI showed anterior cruciate ligament rupture.

joint capsule contracture or fibrosis, and reduce postoperative complications. Acupuncture with traditional Chinese medicine (TCM) can improve the knee joint function and reduce inflammation [6]. This study aimed to investigate the clinical effects of rehabilitation training combined with TCM in the treatment of anterior cruciate ligament injury.

Materials and methods

Materials

A total of 80 patients with anterior cruciate ligament injury admitted to the Sports Science Department of Wonkwang University from November 2018 to November 2019 who underwent arthroscopic reconstruction of the knee in our hospital were enrolled; including 48 males and 32 females aged 20-67 years (average of 39.12 ± 7.65 years), with the course of disease of 2 d-3.5 years. The patients were randomly divided into the observation group (OG) and the control group (CG). The OG included 29 males and 11 females, with an average age of (39.11 ± 7.54) years, while the CG included 22 males and 18 females, with an average age of (39.10

± 7.61) years. Inclusion criteria: The subjects or their family members signed an informed consent form and each subject met the diagnostic criteria for sports training injury [7]. Exclusion criteria: Patient with simultaneous fractures surrounding the anterior and posterior cruciate ligament of the knee, or patients in pregnancy, or patients with dislocation of knee joint with meniscus injury or cartilage injury of the knee were excluded.

Methods

Operation: Patients of both groups were placed in a supine position with the lower limbs straightened or flexed before spinal anesthesia or epidural anesthesia. Aimed at the arthroscopic reconstruction of anterior cruciate ligament in the knee using autologous hamstring tendons (single or split beam), an incision of 2 cm from the tubercle of tibia was made to expose the gracilis and semitendinosus. Then the tendon tissues were separated. The instruments used for anterior cruciate ligament reconstruction were purchased from Smith & Nephew PLC. Tibia formation was synchronous to anterior cruciate ligament injury cleaning by conventional method in clinical practices. The graft was implanted into the established bone tunnel and fixed with screws. The medial cord bent at 60° to tighten the graft before reconstruction, while, for the same reason, the lateral cord bent at 30° after reconstruction. At the end of the operation, the grafted bone needs to be protected from intercondylar impact under arthroscopy and then dressed with a compression bandage (**Figures 1-3**).

Rehabilitation: CG: Postoperative ankle pump training was designed. From the 2^d of surgery, the patients were training to straighten and raise their legs. On the 3rd day, ankle pump training was performed in addition to quadriceps and hamstring muscle training and passive flexion of the knee joint in a range of motion $<60^\circ$. On the 4th day, apart from the trainings above, activities were carried out for knee flexion in a range of motion $>60^\circ$, weight-bearing and balance exercises were allowed, and patients with two crutches begin to stand upright and walk straight for 10 m without weight-bearing. At 5 days after operation, rehabilitation measures were increased to allow the patients to autonomously control the lower legs; activities for knee flexion were increased

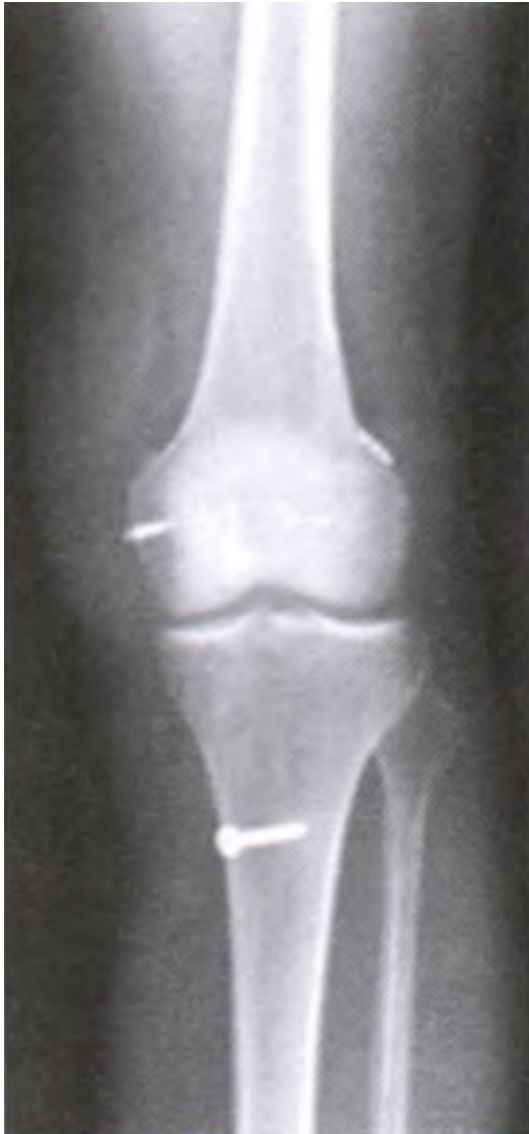

Figure 2. X-ray film showed that medial collateral ligament and anterior cruciate ligament were firmly fixed 1 d after operation.

to a range of motion up to 90°; patients with two crutches can stand upright and walk straight for 20 m, without bearing weight. At 6d after operation, patients with crutches stand on the floor twice a day, 5 min in each; and antibiotics were discontinued. From the 7th day to 3 weeks after operation, activities for knee flexion continued with range of motion of 90°; patients were allowed to straighten the knee, holding the crutches and walk for less than 50 m. The stitches were removed 2 weeks after surgery when the wound was healed. The rehabilitation training continued 4-7 weeks after

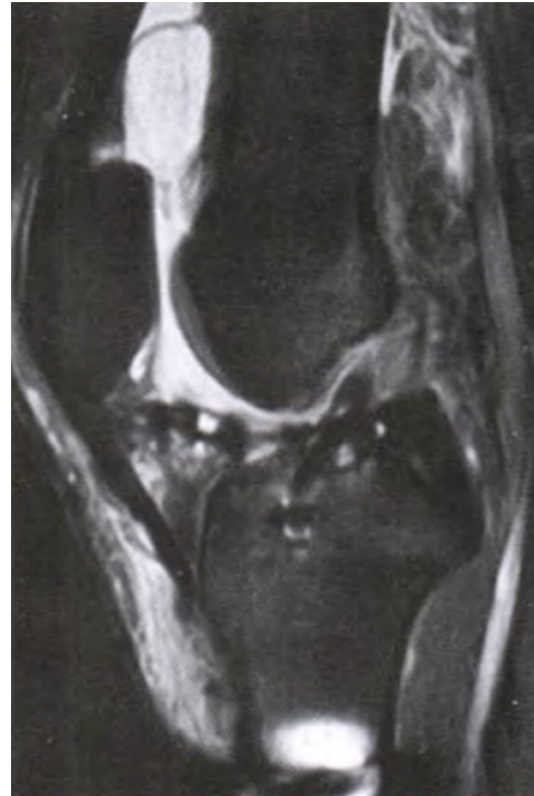

Figure 3. Sagittal MRI showed uniform and continuous anterior cruciate ligament signal, satisfactory bone marrow tract and repair site.

surgery. Furthermore, the range of motion of knee flexion was increased to 120°; patients were instructed to walk on crutches, ride bicycles, climb stairs, etc. From 8 to 12 weeks after surgery, muscle strength exercises were used to help walk without crutches and stride laterally with the range of motion increased to 140°; the affected leg was flexed or extended by 45° for 4 times a day, 5 min each time. From 12 weeks to 6 months after surgery, the patients flexed and/or extended the affected limbs to ensure that the knee was as healthy as the unaffected one so as to continue regular activities such as jogging, jumping, lateral jumps and knee extension and flexion. Measured by Cybex dynamometer, once the myodynamia was 65%-75% of normal, patients were allowed to run.

OG: In addition to the same rehabilitation training as mentioned in the CG, TCM treatment was also used. Patients in the OG were administered oral drugs to promote blood circulation and remove blood stasis, decoction of four ingredients including peach kernel and safflower, and,

Effect of sports rehabilitation combined with traditional Chinese medicine

Table 1. Basic clinical data of the two groups of patients

Group	n	M/F	Age (year)	Course of disease (d)	Hospital stays (d)
OG	20	29/11	39.11 ± 7.54	86.5 ± 120.7	17.50 ± 5.04
CG	20	22/18	39.10 ± 7.61	95.8 ± 116.6	18.66 ± 6.58
t			0.576	7.612	9.024
P			>0.05	<0.05	<0.05

Table 2. Subjective pain observed in the two groups of patients after operation ($\bar{x} \pm s$)

Group	N		Preoperative	Postoperative			3 months after operation
				3 d	7 d	14 d	
OG	40	At rest	5.14 ± 2.29	3.12 ± 1.55	1.04 ± 1.15 ^a	0.36 ± 0.49	0.10 ± 0.25
		In motion	8.78 ± 1.41	3.88 ± 1.12	3.64 ± 1.26 ^a	1.79 ± 1.01 ^a	1.04 ± 0.43
CG	40	At rest	5.51 ± 2.03	5.18 ± 1.21	2.14 ± 1.29	0.62 ± 0.48	0.31 ± 0.13
		In motion	8.53 ± 2.00	6.21 ± 1.87	5.84 ± 2.00	3.11 ± 1.00	1.24 ± 0.29
F			2.23	9.70	8.65	7.14	8.61
P			>0.05	<0.05	<0.05	<0.05	<0.05

Note: ^aP<0.05 as compared with the OG.

if effusion existed, phaseolus calcaratus, cortex moutan, rheum officinale, corydalis yanhusuo and/or cassia twig were given since the 2nd day after surgery. Two weeks later, the treatment focused on expelling wind-damp while tonifying the kidney and the liver by angelicae pubescentis and loranthi decoction orally twice a day, 1/2 dose, for 3-4 weeks. Starting from the 2nd day after surgery, the treatment lasted for 7 weeks.

Outcome measures

Visual analogy scale was applied to quantify the pain in the knee joint during activity and at rest before and at 3 d, 7 d, 14 d and 3 months after surgery: 10 = severe pain, 0 = no pain. Joint swelling was detected with knee joint puncture and extraction at 3 d, 4 d and 17 d after surgery. Joint motion was measured using bone protractor before and at 7 d, 14 d and 3 months after operation. Lysholm was used to assess knee joint function before and 3 months after operation with respect to joint stability (25 points), pain (25 points), interlocking (15 points), swelling (10 points), difficulty with stairs going up and down (10 points), claudication (5 points), difficulty in squatting (5 points), and support required standing up (5 points). The total score is 100 points. A higher score indicates better joint function. Post-operative motor ability, symptoms and knee function in both groups were evaluated by the 2000 scoring system of the International Knee Documentation Committee.

Statistical analysis

SPSS 16.0 software was used for data analysis. Measurement data were expressed as mean ± standard deviation ($\bar{x} \pm s$) and evaluated with t test. Enumeration data were expressed in (%) with analysis by chi-squared test. P<0.05 indicated a statistically significant difference.

Results

General information

Little difference was reported between the two groups in terms of gender, age, course of disease, or hospital stay (P>0.05). They were comparable, as shown in **Table 1**.

Subjective pain observed in both groups after operation

Visual analogy scale showed that the OG showed lower pain scores at 3 d and 7 d after operation during activities or at rest as compared with the CG (P<0.05). At 14 d after operation, pain occurring during activities in patients in the CG was more noticeable than in the OG (P<0.05), as shown in **Table 2**.

Changes in joint motion observed in both groups after operation

Joint motion in patients in the OG at 7 d, 14 d, and 3 months after operation was significantly better than that in the CG (P<0.05), as shown in **Table 3** and **Figure 4**.

Table 3. Changes in motion of joint in the two groups of patients after operation [n=40 ($\bar{x} \pm s$)]

Group	Preoperative	Postoperative		3 months after operation
		7 d	14 d	
OG	113.61 ± 18.82	94.12 ± 6.82	107.72 ± 12.66	137.15 ± 6.59 ^a
CG	115.39 ± 26.58	85.88 ± 7.08	94.21 ± 11.16	120.79 ± 7.01
T	0.635	9.691	9.523	8.894
P	>0.05	<0.05	<0.05	<0.05

Note: ^aP<0.05 as compared with the OG.

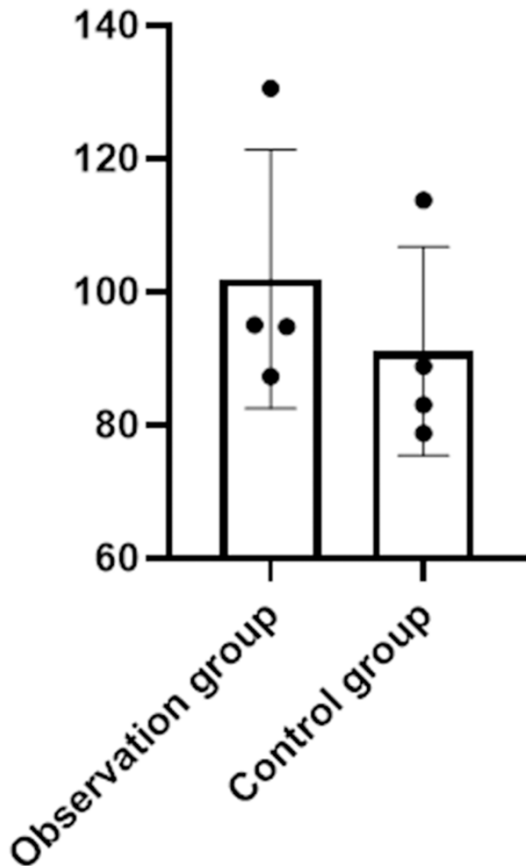


Figure 4. Changes in joint activity after operation in the two groups of patients. At 7 d and 14 d after operation, significantly improved changes in joint motion were observed in the OG, compared with those in the CG ($P<0.05$); both groups reported improved joint activities ($P<0.05$); At 3 months after operation, the results in the OG were better compared with the CG ($P<0.05$).

Swelling of the joint observed in both groups after operation

Joint swelling observed at 3 d, 7 d and 14 d after operation in the OG was less than that in the CG, with significant differences ($P<0.05$), as shown in **Table 4** and **Figure 5**.

Lysholm scores for knee function in both groups after operation

Lysholm scores of knee function in the OG were superior to those in the CG at 3 months after operation ($P<0.05$), and both groups reported higher scores as compared with those before rehabilitation training ($P<0.05$), as shown in **Table 5** and **Figure 6**.

Scores of athletic ability, knee function and symptoms after operation

With the 2000 scoring system of the International Knee Documentation Committee, the scores recorded at 3 months after operation in the OG were much better than those in the CG ($P<0.05$), as shown in **Table 6** and **Figure 7**.

Discussion

Anterior cruciate ligament injury is common in sports. Once the anterior cruciate ligament in the knee is lacerated and the knee joint becomes unstable, delay of therapy and treatment may also worsen knee function [8-10]. Studies have found that the incidence of anterior cruciate ligament injury among American football players is 60/100,000 per year, and 0.43% in China. These injuries are mainly caused by sports, accounting for about 70% of all anterior cruciate ligament injuries. Traffic or other accidents account for 27% [11, 12]. For anterior cruciate ligament injury, arthroscopic reconstruction is commonly used, but postoperative joint adhesion, muscle atrophy, pain and swelling often occur [13-15].

Early postoperative rehabilitation training can improve knee joint function, reduce pain and swelling, and prevent joint adhesion. Arthroscopic reconstruction of the anterior cruciate ligament of the knee involves tissue repair

Table 4. Postoperative joint swelling in the two groups of patients ($\bar{x} \pm s$)

Group	n	Postoperative		
		3 d	7 d	14 d
OG	40	27.28 ± 17.16	14.11 ± 10.57	8.45 ± 5.78
CG	40	30.19 ± 18.18	19.53 ± 10.67	11.01 ± 4.85
t		3.634	7.558	7.142
P		<0.05	<0.05	<0.05

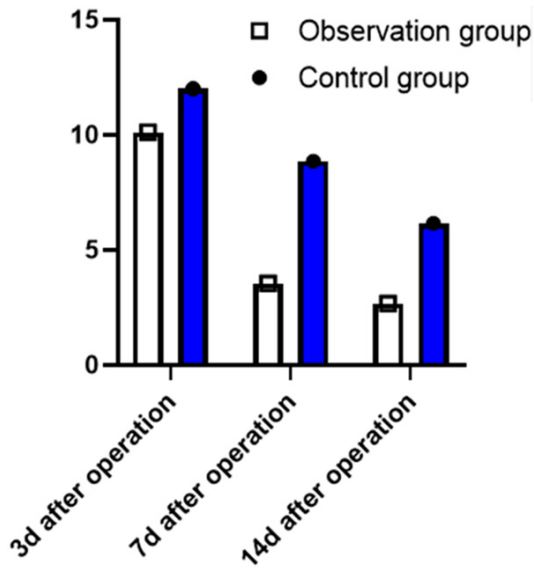


Figure 5. Postoperative joint swelling observed in the two groups. Joint swelling observed as of 3 d, 7 d and 14 d after operation in the OG was much less than in the CG ($P < 0.05$).

Table 5. Postoperative Lysholm scores for knee functioning

Group	n	Preoperative	3 months after operation
OG	40	14.49 ± 11.76	82.11 ± 19.13 ^{a,b}
CG	40	15.67 ± 14.21	69.53 ± 17.11 ^a
t		0.433	9.366
P		>0.05	<0.05

Note: ^a $P < 0.05$ compared with that preoperative; ^b $P < 0.05$ compared with that in OG.

without blood supply, and the reconstructed ligament is in a state of ischemic necrosis with significantly reduced biomechanical properties that, if subjected to stress early or excessively, are prone to cause fracture or elongate tissue [16-18]. Although some studies indicated that premature rehabilitation training after reconstruction may increase the incidence of complications and affect the recovery, scholars

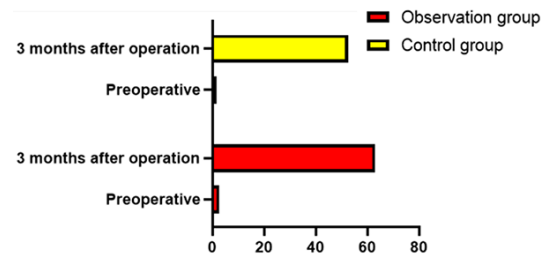


Figure 6. Lysholm scores for knee functioning of the two groups of patients after operation. Lysholm scores for knee functioning of patients in the OG were significantly higher than those in the CG at 3 months after operation ($P < 0.05$). For both groups, the scores improved compared with those before operation ($P < 0.05$).

believe that reconstruction of the anterior cruciate ligament in the muscoli semimembranosus and semitendinosus after 2-6 months of rehabilitation therapy can show positive clinical effects [19, 20]. In this study, early rehabilitation training after the arthroscopic reconstruction of the anterior cruciate ligament in the knee can shorten the hospital stay of patients, promote the recovery of knee function, and reduce traumatic reactions, pain, swelling or joint adhesion [21, 22].

The pain reported in the OG after rehabilitation training at 3 d, 7 d and 14 d after operation was significantly less than that in the CG ($P < 0.05$), suggesting that rehabilitation training improved joint motion and swelling. Many types of operations including arthroscopy may cause damage to muscles and bones of the joint, leading to blood loss outside of arteries and veins. The blood outside the vasculature combined with what is referred to as “damp evil” in TCM, forms blood stasis to block the veins and steeps in the joints. Injured vital energy causes pain, while other tissue damage gives rise to swelling. Stagnation of vital energy and blood blocks the veins and induces pain. That is why patients experience severe pain in the knee after opera-

Table 6. Scores for postoperative exercise capacity, knee function and symptoms in the two groups of patients ($\bar{x} \pm s$)

Group	n	Preoperative	3 months after operation
OG	40	19.13 ± 10.24	53.65 ± 9.11
CG	40	18.83 ± 11.15	48.12 ± 8.46
t		0.476	7.831
P		>0.05	<0.05

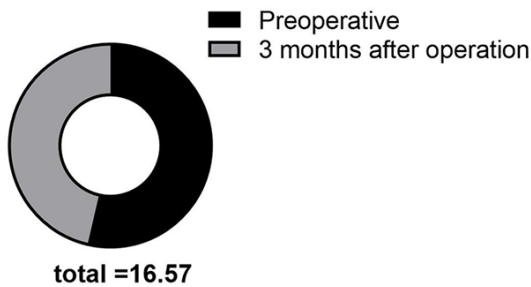


Figure 7. Scores for postoperative exercise ability, knee functioning and symptoms. At 3 months after operation, both groups reported significantly better scores for exercise ability, knee function and symptoms, with significant differences ($P < 0.05$), and those in the OG were superior to the scores in the CG ($P < 0.05$).

tion. Damp evil remains in the joints and interlocks with blood spilled outside, leading to joint effusion, hematoma, and swelling [23-25]. Early oral administration of decoction of four ingredients including peach kernel and safflower plays a role in activating blood circulation and removing stasis in the collaterals. In the OG, postoperative rehabilitation training combined with TCM reduced joint swelling as compared with the CG ($P < 0.05$). This could be explained by the fact that the TCM inhibits synovitis, prevents the synovial membrane from releasing inflammatory substances, and reduces the incidence of fibrosis adhesion so as to improve the systemic microcirculation. In the later period, limited joint motion is mainly due to the attack of external factors including wind, cold, damp and pathogens, according to TCM. Asthenia in origin and excess in superficiality, radix angelicae pubescentis should be used to dispel wind-damp and tonify the liver and the kidney. The postoperative joint mobility observed in the OG proved the prescription to be effective in activating blood and dissolving stasis. The 2000 scoring system and Lysholm scale indicated that rehabilitation training com-

bined with TCM treatment improves patients' activity of daily living and knee function as well.

In summary, early rehabilitation training combined with TCM after arthroscopic reconstruction of the anterior cruciate ligament of the knee can effectively reduce pain and swelling in joints and improve knee function.

Acknowledgements

This paper was supported by Wonkwang University in 2020.

Disclosure of conflict of interest

None.

Address correspondence to: Jeho Song, Department of Sports Science, Wonkwang University, 344-2 Office, Shinyong-Dong, Iksan, Jeonbuk, Republic of Korea. Tel: +82-63-850-6895; E-mail: jehottt@163.com

References

- [1] Gulbahar S, Akgün B, Karasel S, Baydar M, El ö, Pinar H, Tatari H, Karaođlan O and Akalın E. The effect of anterior knee pain on strength, functional tests, proprioception and balance after anterior cruciate ligament reconstruction/On capraz bag rekonstruksiyonu sonrasi gelisen diz onu agrisinin kas gucu, fonksiyonel skorlar, denge ve proprioepsiyon uzerine etkisi. Turk J Phys Med Rehabil 2013; 59: 90-96.
- [2] Bregenhof B, Jørgensen U, Aagaard P, Nissen N, Creaby MW, Thorlund JB, Jensen C, Torfing T and Holsgaard-Larsen A. The effect of targeted exercise on knee-muscle function in patients with persistent hamstring deficiency following ACL reconstruction - study protocol for a randomized controlled trial. Trials 2018; 19: 75.
- [3] Lian J, Diermeier T, Meghpara M, Popchak A, Smith CN, Kuroda R, Zaffagnini S, Samuelsson K, Karlsson J, Irrgang JJ and Musahl V. Rotatory knee laxity exists on a continuum in anterior cruciate ligament injury. J Bone Joint Surg Am 2020; 102: 213-220.
- [4] Zhang L, Qi J, Zeng Y, Zhang S, Fu S, Zhou X, Ping R and Li Y. Proprioceptive changes in bilateral knee joints following unilateral anterior cruciate ligament injury in cynomolgus monkeys. Med Sci Monit 2018; 24: 105-113.
- [5] Takahashi T, Kondo E, Yasuda K, Miyatake S, Kawaguchi Y, Onodera J and Kitamura N. Effects of remnant tissue preservation on the tendon graft in anterior cruciate ligament re-

Effect of sports rehabilitation combined with traditional Chinese medicine

- construction: a biomechanical and histological study. *Am J Sports Med* 2016; 44: 1708-1716.
- [6] Wang H, Chen YQ and Chen YD. Effects of balance acupuncture combined with external application of traditional Chinese medicine on 20 cases of knee joint injury. *China Modern Doctor* 2019; 057: 134-137.
- [7] Liu F. Course composition and innovation in sports training teaching: comments on sports training science. *Journal of the Chinese Society of Education* 2017; 135.
- [8] Hamrin Senorski E, Svantesson E, Spindler KP, Alentorn-Geli E, Sundemo D, Westin O, Karlsson J and Samuelsson K. Ten-year risk factors for inferior knee injury and osteoarthritis outcome score after anterior cruciate ligament reconstruction: a study of 874 patients from the swedish national knee ligament register. *Am J Sports Med* 2018; 46: 2851-2858.
- [9] Janssen RP, du Mée AW, van Valkenburg J, Sala HA and Tseng CM. Anterior cruciate ligament reconstruction with 4-strand hamstring autograft and accelerated rehabilitation: a 10-year prospective study on clinical results, knee osteoarthritis and its predictors. *Knee Surg Sports Traumatol Arthrosc* 2013; 21: 1977-1988.
- [10] Janssen R, van Melick N, Mourik J, Reijman M and Rhijn L. Similar clinical outcome between patellar tendon and hamstring tendon autograft after anterior cruciate ligament reconstruction with accelerated, brace-free rehabilitation: a systematic review. *Journal of ISAKOS: Joint Disorders & Orthopaedic Sports Medicine* 2017; jisakos-2016.
- [11] van Tol FR, Kernkamp WA, van der Wal RJP, Swen JA, Van de Velde SK and van Arkel ERA. The occurrence of meniscal and chondral injury in two-stage revision anterior cruciate ligament reconstruction: a consecutive case series. *J Knee Surg* 2020; 33: 223-227.
- [12] Arumugam A, Strong A, Tengman E, Røijezon U and Häger CK. Psychometric properties of knee proprioception tests targeting healthy individuals and those with anterior cruciate ligament injury managed with or without reconstruction: a systematic review protocol. *BMJ Open* 2019; 9: e027241.
- [13] Li Y, Li L and Jiang S. Effects of enriched environment and rehabilitation training on the recovery of neural function of rats with traumatic brain injury. *Chinese Journal of Rehabilitation Medicine* 2013; 28: 393-397.
- [14] Kızılgöz V, Sivrioğlu AK, Ulusoy GR, Yıldız K, Aydın H and Çetin T. Posterior tibial slope measurement on lateral knee radiographs as a risk factor of anterior cruciate ligament injury: a cross-sectional study. *Radiography (Lond)* 2019; 25: 33-38.
- [15] Smith ID, Irfan A, Huntley JS and Spencer SJ. What is the best treatment for a child with an acute tear of the anterior cruciate ligament? *J Paediatr Child Health* 2018; 54: 1037-1041.
- [16] Ekås GR, Laane MM, Larmo A, Moksnes H, Grindem H, Risberg MA and Engebretsen L. Knee pathology in young adults after pediatric anterior cruciate ligament injury: a prospective case series of 47 patients with a mean 9.5-year follow-up. *Am J Sports Med* 2019; 47: 1557-1566.
- [17] Shim JK, Choi HS and Shin JH. Effects of neuromuscular training on knee joint stability after anterior cruciate ligament reconstruction. *J Phys Ther Sci* 2015; 27: 3613-3617.
- [18] Ihara H and Kawano T. Can MR Appearance performed a few days after injury predict the morphological recovery of the anterior cruciate ligament treated by early protective motion? *Orthopedics & Traumatology* 2011; 60: 184-187.
- [19] Heijne A, Axelsson K, Werner S and Biguet G. Rehabilitation and recovery after anterior cruciate ligament reconstruction: patients' experiences. *Scand J Med Sci Sports* 2008; 18: 325-335.
- [20] Zhou MW, Gu L, Chen YP, Yu CL, Ao YF, Huang HS and Yang YY. Factors affecting proprioceptive recovery after anterior cruciate ligament reconstruction. *Chin Med J (Engl)* 2008; 121: 2224-2228.
- [21] Myklebust G, Holm I, Maehlum S, Engebretsen L and Bahr R. Clinical, functional, and radiologic outcome in team handball players 6 to 11 years after anterior cruciate ligament injury: a follow-up study. *Am J Sports Med* 2003; 31: 981-989.
- [22] Katagiri H, Miyatake K, Nakagawa Y, Otabe K, Ohara T, Shioda M, Sekiya I and Koga H. The effect of a longitudinal tear of the medial meniscus on medial meniscal extrusion in anterior cruciate ligament injury patients. *Knee* 2019; 26: 1292-1298.
- [23] Chen F. Effect of traditional chinese medicine treatment combined with rehabilitation training on early knee function after arthroscopic anterior cruciate ligament reconstruction. *The Journal of Medical Theory and Practice* 2016; 207-209.
- [24] Yang J. Effect of Qixue Burongjin decoction combined with fumigation and washing on meniscal injury and postoperative recovery after arthroscopy. *Journal of New Chinese Medicine* 2015; 047: 91-93.
- [25] Xu M, Du F and Chu X. Perioperative nursing of arthroscopic anterior cruciate ligament reconstruction. *The Journal of Traditional Chinese Orthopedics and Traumatology* 2014; 76.