

## Original Article

# Effects of intra-abdominal pressure in rat lung tissues after pneumoperitoneum

Julio Cezar Mendes Brandao, Carla Andria Dato, Vanessa Coelho Gaspar, Luciana Cristina Teixeira, Masashi Munechika Masashi, David Ferez, Luiz Fernando dos Reis Falco, Itamar Souza Oliveira Junior

*Discipline of Anesthesia, Pain and Critical Care Medicine, Department of Surgery, Federal University of São Paulo (UNIFESP), Brazil*

Received May 2, 2019; Accepted July 5, 2019; Epub July 15, 2019; Published July 30, 2019

**Abstract:** Background: Laparoscopic surgery requires pneumoperitoneum, achieved by pressure-controlled insufflation with carbon dioxide into the peritoneal cavity. This condition changes the respiratory metabolism, promoting lung damage. Purpose: The aim of the present study was to compare the effects of different levels of intra-abdominal pressure (IAP) in a ventilated rat model with normal lungs. Methods: Forty-eight Wistar rats were selected at random. Eight rats were assigned to each of the groups. The Sham group was subjected to a sham operation without pneumoperitoneum. The remaining groups were subjected to CO<sub>2</sub> pneumoperitoneum with 5, 8, 10, 12, or 14 mmHg intra-abdominal pressure for 60 minutes. All animals were mechanically ventilated. At the end of the experiment, the animals were euthanatized. Their lungs were removed for analysis. Lipid peroxidation, myeloperoxidase activity, measurements of cytokines, and histopathological analysis were performed. Results: In the IAP5 group, all levels were lower, compared with those of other groups. TNF-alpha, IL-1beta, IL-6, lipid peroxidation, and myeloperoxidase activity were higher in groups IAP10, IAP12, and IAP14, compared with those of groups IAP5 and IAP8. Present results were supported by histopathological examinations. Conclusion: Present findings suggest that high-pressure increases oxidative stress and inflammatory-induced lung damage after pneumoperitoneum.

**Keywords:** Laparoscopy, experimental, pneumoperitoneum, cytokines, oxidative stress, lung Injury

## Introduction

Laparoscopic procedures are important in the era of modern surgery. They have been used in the diagnosis and treatment of a large number of specialties. Laparoscopy brings many advantages. However, it also requires special care because of transient physiologic changes promoted by the insufflation of gases in the abdominal cavity [1-6].

Laparoscopic surgeries require pneumoperitoneum (PNP), usually achieved by pressure-controlled insufflation of carbon dioxide into the peritoneal cavity. In clinical practice, this gas is used with inflation pressures above 10 mmHg in adults. Although PNP is a complex event, it is well-tolerated with a pathophysiological condition characterized by increased intra-abdominal pressure (IAP) with low perfusion in abdominal organs. Re-establishment of flow (reperfusion) occurs with deflation of the abdominal

cavity with significant hemodynamic and respiratory effects, as well as specific changes in intra-abdominal organs. This condition of "ischemia-reperfusion" (IR) leads to important effects, including hemodynamic, respiratory, and oxidative stress. Thus, intra-abdominal pressure during laparoscopic surgery can cause injuries, affecting local and distant tissues [7-10]. Despite the clear advantages of laparoscopic surgery in terms of patient outcomes, increased intra-abdominal pressure (IAP) may give rise to significant organ ischemia in the splanchnic organs, even in remote organs, such as the lungs [11]. This IR process leads to the production of reactive oxygen species (ROS). This can cause oxidative cell damage, as well as activation of inflammatory mediators, initiated immediately after reperfusion. This can last for a few hours [12-18].

In summary, intra-abdominal insufflation with CO<sub>2</sub> elevates the diaphragm. This condition

## Pneumoperitoneum with high pressure and lung injuries

increases intrathoracic pressure, decreasing respiratory system compliance associated with hypoxemia, atelectasis, edema, and barotrauma [19, 20]. Recruitment maneuvers for reduction at the atelectasis area increase lung stress. These may contribute to postoperative pulmonary dysfunction [21-24].

Based on the above issues, it was hypothesized that high IAP would promote more pulmonary lesions, increasing inflammatory cytokines and reactive oxygen species production in the lungs. The aim of the current study was to evaluate the implications of PNP with different pressure levels of CO<sub>2</sub>, examining the effects on lung morphological and biochemical parameters.

### Materials and methods

All animal care and manipulations were approved by the Institutional Research Committee of the Federal University of São Paulo, in accordance with National Institute of Health (NIH) guidelines regarding animal experimentation, along with guidelines of the 3R's (Council Directive 86/609/EEC and new limits for the use of animals in experiments by the European Parliament in 2010).

The current study was performed on adult male Wistar albino rats (n = 8/group, weighing 200-250 g; 3 to 4-months-old). These animals were obtained from the Federal University of São Paulo (UNIFESP, SP, Brazil) and were housed in the vivarium under a controlled temperature ( $\pm 22^{\circ}\text{C}$ ) and photoperiod (12-hour light/dark period), with free access to water and food. A 2-week acclimatization period was conducted before experimental manipulations were initiated. Aiming to avoid interference factors related to circadian rhythms, all studies were performed between 8 and 10 am.

#### *Anesthetic and ventilatory procedures*

The rats were anesthetized with intramuscular (IM) injections of ketamine (40 mg/kg; Cetamin™, Syntec, Brazil) and xylazine (10 mg/kg; Anasedan™, Seva, Brazil). They were placed in the supine position on a thermostatically regulated heating pad (36.7-37°C). The abdomens were shaved and washed with 10% povidone iodine. Muscular relaxation was performed with IM injections of 2 mg/kg of neuromuscular

blocking (Pancuron™, Cristália, Brazil), following tracheostomy (16 G cannula) procedures for mechanical ventilation (Inspira ASV, Harvard Apparatus, MA, United States) in the volume-controlled ventilation mode. Tidal volume (VT) of 6 mL/kg, respiratory rate (RR) of 70 incursions/min, PEEP of 2 cmH<sub>2</sub>O, and inspired oxygen fraction ratio (FiO<sub>2</sub>) of 0.21 were maintained to end-tidal CO<sub>2</sub> at 30-35 mmHg.

#### *Pneumoperitoneum*

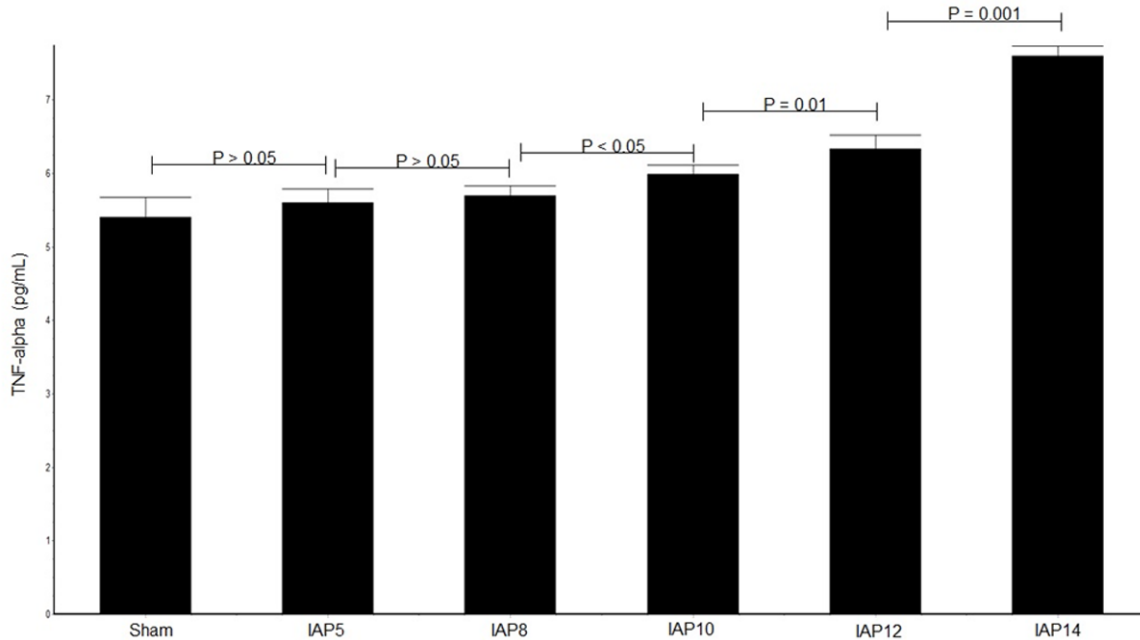
The animals were randomized using a specific program (random.org) and divided into 6 groups (n = 8/group), using the three R's rules (reduce, reuse, and recycle), as follows: 1) Sham: Only the angiocatheter (18-G cannula) was positioned in the peritoneal cavity without insufflation (zero pressure); 2) IAP5: Intra-abdominal insufflation with 5 mmHg of CO<sub>2</sub>; 3) IAP8: Intra-abdominal insufflation with 8 mmHg of CO<sub>2</sub>; 4) IAP10: Intra-abdominal insufflation with 10 mmHg of CO<sub>2</sub>; 5) IAP12: Intra-abdominal insufflation with 12 mmHg of CO<sub>2</sub>; and 6) IAP14: Intra-abdominal insufflation with 14 mmHg of CO<sub>2</sub>. After experimentation and gradual decompression, pH concentrations in arterial blood gas were analyzed. The animals were euthanized using high anesthetic doses (1 mL/100 g of weight) of T-61 euthanasia solution (Hoechst & Roussel, USA).

Capnoperitoneum was performed for 60 minutes using an electronic laparoflator insufflator (Karl Storz GmbH, Germany). Immediately after euthanasia, thoracotomy procedures were performed and the lungs were removed. The right lungs were divided. One part (right cranial lobe) was homogenized in ice-cold potassium chloride solution (1.5%, pH 7.4; Desruptor Ultrasonic, Thorton, Brazil), yielding 10% (w/v). It was centrifuged (2,500 rpm for 10 minutes, at 4°C; VitchLab, DAIKI, Model DTR 16000, SP, Brazil) and supernatants were stored at -20°C until analysis. Biochemistry analysis was performed using a spectrophotometer (Genesys™, Thermo Scientific, USA). The other part was used for histological analysis.

#### *ELISA for myeloperoxidase activity (MPO), malondialdehyde (MDA), and cytokines*

MPO activity and malondialdehyde (MDA) were measured, evaluating oxidative stress. Levels were determined using an ELISA kit (Zen™

## Pneumoperitoneum with high pressure and lung injuries



**Figure 1.** Effects of CO<sub>2</sub> pneumoperitoneum at different IAPs on tissue TNF-alpha concentrations. TNF-alpha levels were not significantly different between Sham and IAP-5 groups. Significant differences were observed comparing the Sham group with all other groups, IAP8 with IAP10, IAP10 with IAP12, and IAP12 with IAP14. TNF-alpha, tumor necrosis factor-alpha; IAP, intra-abdominal pressure.

Myeloperoxidase ELISA Kit, Sigma-Aldrich, EUA) and an OxiSelect™ MDA Adduct ELISA kit (Cell Biolabs, Inc., USA), according to manufacturer instructions.

ELISA kits specific for rats TNF- $\alpha$  (KAP1751), IL-1 $\beta$  (KAP1211), and IL-6 (KAP1261) (Dia-Source, Belgium) were used to determine concentrations of cytokines in tissue homogenates, according to manufacturer recommendations.

### *Histological examinations*

The other parts of the lungs (right caudal lobe) were dipped in 10% formalin, embedded in paraffin, and cut into sections of 4  $\mu$ m. The slides were stained with hematoxylin and eosin (H&E) and interpreted under an optical microscope (Zeiss Axion Image A2™, Germany). They were used for descriptive analysis, conducted by two blinded pathologists. Damaged levels in these sections were described according to the extent of interstitial cellular infiltration, alveolar protein exudation, and tissue hemorrhaging.

### *Statistical analysis*

Mean (M)  $\pm$  standard deviation (SD) was used to analyze present data. Biochemistry data

were compared using Graph Pad PRISM via one-way analysis of variance with Dunn's least significant difference tests.  $P < 0.05$  indicates statistical significance.

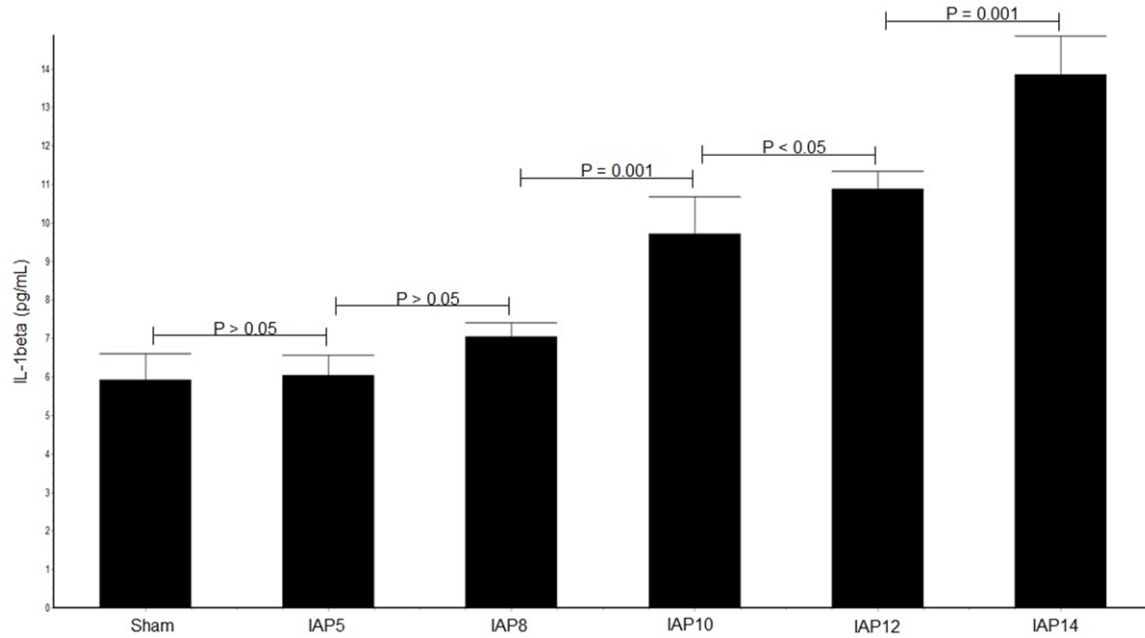
### **Results**

No animals died during the experimental procedures. Acidosis was most observed in the IAP14 group (6.827 $\pm$ 0.1464). Levels were higher compared with other groups ( $p < 0.05$ ). No differences were observed between the Sham group and IAP5 (7.29 $\pm$ 0.045) and IAP8 (7.281 $\pm$ 0.029), IAP8 with IAP10 (7.11 $\pm$ 0.057), and IAP10 with IAP12 (7.01 $\pm$ 0.051).

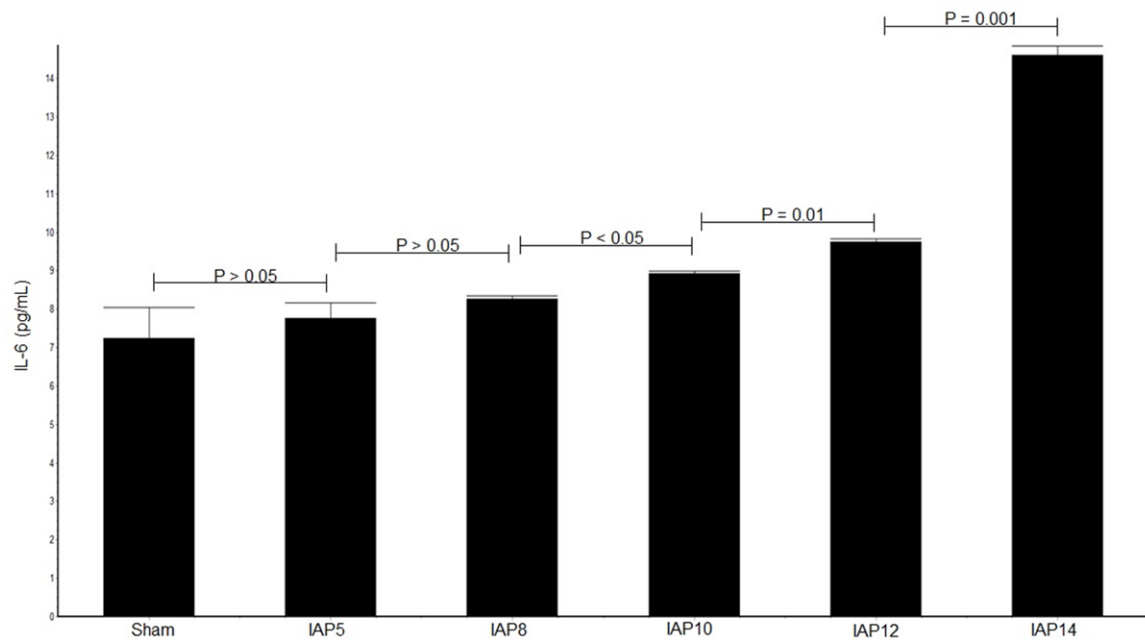
**Figures 1-5** shows the average for all parameters analyzed, including TNF-alpha, IL-1beta, IL-6, MDA, and MPO, respectively, as well as results of histological analyses with illustrative images of the changes.

TNF-alpha (**Figure 1**) values were significantly higher for all experiments, compared with those of the Sham group ( $p = 0.001$ ), except for comparisons between the experimental group IAP5 and Sham group and between IAP5 and IAP8 experimental groups.

## Pneumoperitoneum with high pressure and lung injuries



**Figure 2.** Effects of CO<sub>2</sub> pneumoperitoneum at different IAPs on tissue IL-1b concentrations. IL-1b levels were not significantly different between Sham, IAP-5, and IAP8 groups. Significant differences were observed comparing the Sham group with all other groups and comparing IAP8 with IAP10, IAP10 with IAP12, and IAP12 with IAP14. IL1b, interleukin-1beta; IAP, intra-abdominal pressure.



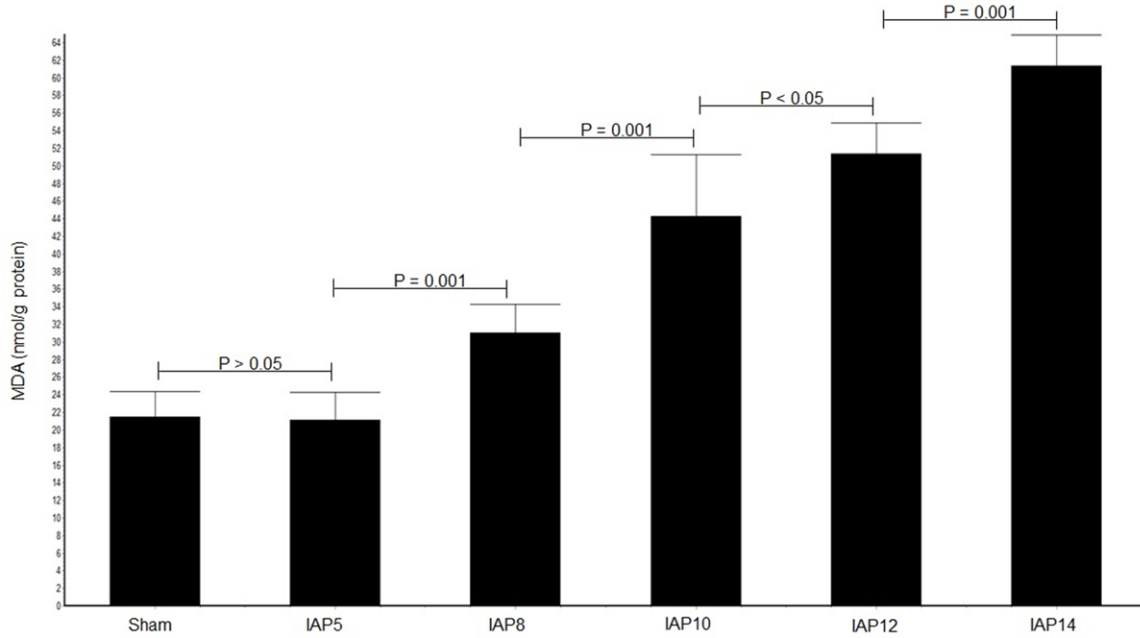
**Figure 3.** Effects of CO<sub>2</sub> pneumoperitoneum at different IAPs on tissue IL-6 concentrations. IL-6 levels were not significantly different between Sham and IAP-5 groups and between the IAP5 and IAP8 groups. Significant differences were observed comparing groups IAP8 with IAP10, IAP10 with IAP12, and IAP12 with IAP14.

Regarding IL-1beta (**Figure 2**), there were significant differences for all comparisons between the control group and other experimental groups ( $p = 0.001$ ), except for comparisons between the experimental group IAP5 and

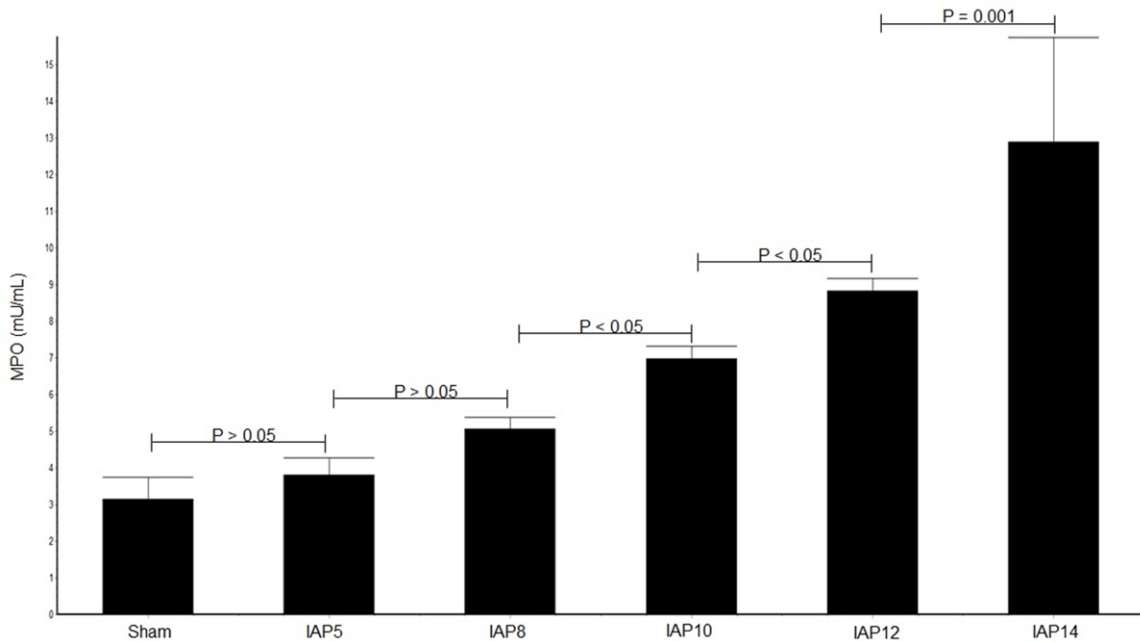
Sham group and IAP5 and IAP8 experimental groups.

IL-6 levels (**Figure 3**) were significantly higher for all comparisons between the control group

## Pneumoperitoneum with high pressure and lung injuries



**Figure 4.** Effects of CO<sub>2</sub> pneumoperitoneum at different IAPs on tissue MDA concentrations. MDA levels were significantly higher in groups IAP8, IAP10, IAP12, and IAP14 than in Sham and IAP5 groups. No differences were observed between Sham and IAP5 groups.



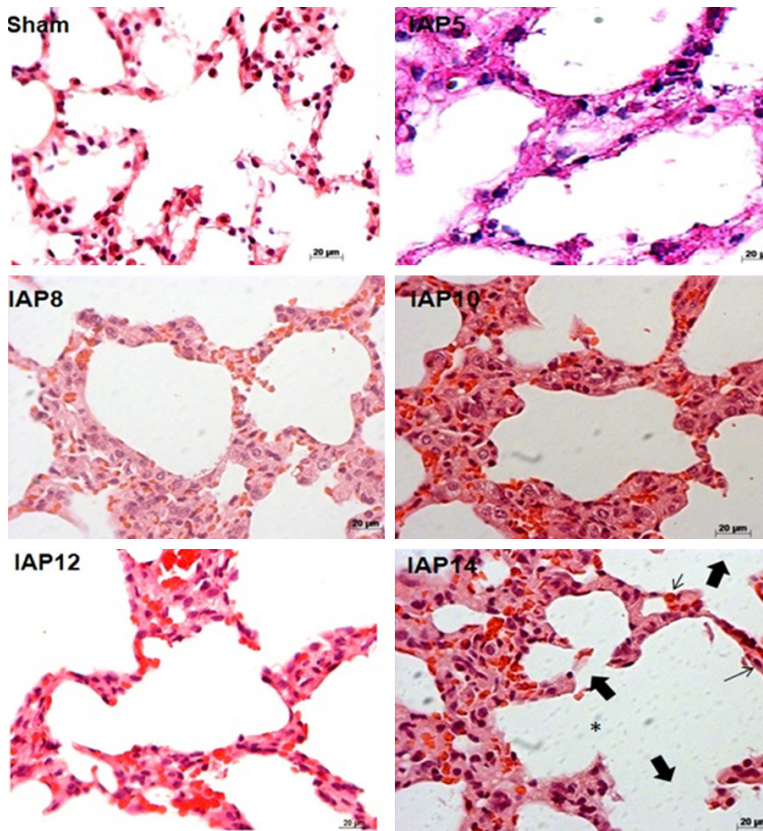
**Figure 5.** Effects of CO<sub>2</sub> pneumoperitoneum at different IAPs on tissue MPO concentrations. MPO levels were significantly higher in groups IAP8, IAP10, IAP12, and IAP14, compared with those of the Sham group. There were no statistical differences between the Sham and IAP5 and IAP8. MPO groups, myeloperoxidase activity; IAP, intra-abdominal pressure.

(Sham) and other experimental groups ( $p = 0.001$ ).

Tissue analysis showed increased MDA concentrations (**Figure 4**) in the lungs for groups

IAP8, IAP10, IAP12, and IAP14, compared with the Sham and IAP5 groups ( $p = 0.001$ ). Rats subjected to CO<sub>2</sub> PNP with 8, 10, 12, and 14 mmHg showed significant differences, comparing IAP8 with other groups ( $p = 0.001$ ), IAP10





**Figure 6.** Histological evaluations of the alveoli in group IAP14, showing wall thickening and rupture of the alveolar septum (thin full arrow), edema (asterisk), red blood cell (thin small arrow), and PMN influx (thin long arrow). Regarding the other groups, alterations in the alveolar structure were observed in lesser extension in the lower pressure groups, except for Sham and IAP5 groups.

with IAP12 and IAP14 ( $p = 0.001$ ), and IAP12 with IAP14 ( $p = 0.001$ ).

MPO levels (**Figure 5**) were significantly higher in group IAP14 than in other groups ( $p = 0.001$ ). However, there were no differences in MPO levels between groups IAP5, compared with IAP8.

According to histological evaluations, analyses of different groups showed histological changes more noticeable in the groups with major intra-abdominal pressure regimes. Differences were clearer when comparing extreme groups (Sham and lower pressures vs. higher pressures). In the group undergoing the regime of higher pressures (IAP14), there was markedly severe disruption of the alveolar septa, edema, diffuse bleeding, and presence of increased inflammatory infiltration. This can be seen in the comparative picture below. IAP10 and IAP12 groups showed changes in the cellular

architecture with swelling, rupturing of the septum, and inflammatory infiltration. However, these were at lower levels than the IAP14 group and clearly higher than the IAP8, IAP5, and Sham groups. Samples of lung tissues of the IAP8 group showed some changes in the architecture, alveolar damage, increased alveolar septum, and inflammatory infiltration, although to a lesser degree than the groups subjected to higher pressure regimes, as shown in **Figure 6**.

### Discussion

The current study was designed to determine the impact of different IAP on the lungs. Present findings were quite consistent and maintained a standard throughout the different groups, showing a direct relationship between the inflation pressure of the PNP and pulmonary changes, evaluating oxidative stress (MDA and MPO), inflammatory cytokines (TNF-alpha, IL-1beta, and IL-6), and histological findings. The current study

analyzed six different groups using five different levels of IAP to measure the consistency and magnitude of differences of pulmonary changes with respect to oxidative stress and inflammatory response. Most studies have used two to three different IAP regimes [25-28] and the used other gases (e.g. nitrous oxide, helium, or room air). However, the most used is CO<sub>2</sub> [29].

Reduction of the antioxidant defenses makes cells more susceptible to oxidative attacks [30]. After 30 minutes of abdominal deflation, reperfusion in the abdominal organs resulted in increased oxidative stress and lipid peroxidation [27]. Cevrioglu et al. reported increased plasma oxidative stress (MDA) and cytokine response (TNF-alpha and IL-6) in a group receiving 15 mmHg IAP [18]. The present study corroborated and expanded their results by analyzing MDA and cytokines in the lung tissues, find-

ing higher values for the IAP14 group, compared with those of the other groups ( $p < 0.05$ ).

In another study, Runck et al. observed decreased compliance of the respiratory system after increases of the IAP in mechanically ventilated mice [21]. The progressive increase of IAP promotes an inversely proportional reduction in respiratory compliance. The decrease in the compliance of the respiratory system implies an average increase in the inspiratory pressure values for compensation, leading to increased driving pressure, exposure of the respiratory system under physiological systems with higher pressures, and more inflammation and ROS production. To prevent atelectasis, hypoxemia, and pulmonary lesions, PEEP should not be neglected in counteracting IAP. Therefore, higher IAPs will lead to greater resistance in the respiratory system. This is directly associated with an increase of inflammatory markers [31, 32], in accordance with current results.

Pneumoperitoneum increases inflammation of cytokines, causing damage in cell structures, capillary endothelium, and pulmonary tissues, resulting in lung injuries [31]. During laparoscopy surgery, the production of TNF-alpha has been associated with the activity of peritoneal macrophages. After pneumoperitoneum, it has been associated with increased levels of IL-6 and TNF-alpha [18, 33-36]. Present results show an increase in inflammatory mediators in the lung tissues as IAP increased.

Strang et al. [37], in a porcine model, demonstrated the direct correlation between increased IAP pressure and atelectasis incidence. Different IAP CO<sub>2</sub> levels were applied to mechanically ventilated pigs in the supine position. The proportion of atelectasis was assessed after the application of PNP. The following results were found: Control group (without PNP inflation) presented 4% of atelectasis on average, group IAP8 showed 9%, group IAP12 had 12%, and group IAP16 presented 16% of atelectasis. Results showed a direct relationship between increases in PNP inflation pressure and the presence of atelectasis.

In the current study, histopathological examinations of the lung tissues were consistent with biochemical data analyses. Histological indicators showed significant tissue damage in the IAP12 and IAP14 groups. There was a clash of

pressure due to mechanical ventilation associated with intra-abdominal insufflations (PNP), likely leading to some pulmonary hypoperfusion. This is in accordance with previous studies. In contrast, low intra-abdominal pressure levels and reduced pulmonary damage were seen, confirming the beneficial effects of the use of lower intra-abdominal pressure levels for PNP inflation, in accord with other studies [38-42].

PNP induces oxidative stress systemically. The same occurs in lungs submitted to a regime of non-physiological pressure levels. This further accentuates the change in homeostasis. Inflammatory factors caused by surgery trauma, PNP pressure, and mechanical ventilation promote the formation of these ROS events, which are time-exposure dependent [39-43].

The current study, however, had several limitations. First, results of this study clearly showed no different ventilatory parameters when using different PNPs. Second, the position of the rats was not studied. This condition may have affected concentrations of oxidative stress and inflammatory mediators in the lungs. Moreover, this study was not able to differentiate changes in activity and expression of other analyses of anti-oxidative and anti-inflammatory mediators. Third, this study was conducted in healthy rats. Fourth, the current study did not evaluate the activity of lungs and peritoneal macrophages.

### Conclusion

In conclusion, the current study shows that lung inflammatory mediators and oxidative stress were increased with increased intra-abdominal pressure, confirmed by histological analysis. Although these findings are not transferrable to clinical practice, they highlight the future potential of the use of low intra-abdominal pressure during CO<sub>2</sub> pneumoperitoneum in laparoscopic surgery.

### Acknowledgements

The authors are grateful to the Sao Paulo Research Foundation (FAPESP; 14/12730-6) and to the Saul Goldemberg vivarium at the Federal University of São Paulo (UNIFESP) for the maintenance of the animals during the preoperative phase. The pilot study result was presented at

the ATS 2016 International Conference, May 13-18, 2016, San Francisco, California. The current study received a grant from Sao Paulo Research Foundation (FAPESP; 14/12730-6) as part of the Phd program research grant.

### Disclosure of conflict of interest

None.

**Address correspondence to:** Julio Cezar Mendes Brandao, Disciplina de Anestesia, R. Cláudio Batista, s/n - Cidade Nova, Aracaju - SE, 49060-108, Hospital Universitário da Universidade Federal de Sergipe (HU-UFS), Brazil. E-mail: juliobrand@hotmail.com

### References

- [1] Shabanzadeh DM, Sorensen LT. Laparoscopic surgery compared with open surgery decreases surgical site infection in obese patients: a systematic review and meta-analysis. *Ann Surg* 2012; 256: 934-945.
- [2] Nguyen KT, Marsh JW, Tsung A, Steel JJ, Gambelin TC, Geller DA. Comparative benefits of laparoscopic vs open hepatic resection: a critical appraisal. *Arch Surg* 2011; 146: 348-356.
- [3] Gurusamy KS, Samraj K, Fusai G, Davidson BR. Early versus delayed laparoscopic cholecystectomy for biliary colic. *Cochrane Database Syst Rev* 2008; CD007196.
- [4] Takata MC, Kebebew E, Clark OH, Duh QY. Laparoscopic bilateral adrenalectomy: results for 30 consecutive cases. *Surg Endosc* 2008; 22: 202-207.
- [5] Grace PA, Quereshi A, Coleman J, Keane R, McEntee G, Broe P, Osborne H, Bouchier-Hayes D. Reduced postoperative hospitalization after laparoscopic cholecystectomy. *Br J Surg* 1991; 78: 160-162.
- [6] Joris J, Cigarini I, Legrand M, Jacquet N, De Groote D, Franchimont P, Lamy M. Metabolic and respiratory changes after cholecystectomy performed via laparotomy or laparoscopy. *Br J Anaesth* 1992; 69: 341-345.
- [7] Schafer M, Sagesser H, Reichen J, Krahenbuhl L. Alterations in hemodynamics and hepatic and splanchnic circulation during laparoscopy in rats. *Surg Endosc* 2001; 15: 1197-1201.
- [8] Unsal MA, Imamoglu M, Cay A, Kadioglu M, Aydin S, Ulku C, Kesim M, Alver A, Bozkaya H. The acute alterations in biochemistry, morphology and contractility of the rat isolated urinary bladder induced by increased intra-abdominal pressure. *Gynecol Obstet Invest* 2006; 61: 179-187.
- [9] Unsal MA, Imamoğlu M, Kadioğlu M, Aydin S, Ulku C, Kesim M, Alver A, Bozkaya H. The acute alterations in biochemistry, morphology, and contractility of rat-isolated terminal ileum via increased intra-abdominal pressure. *Pharmacol Res* 2006; 53: 135-141.
- [10] Schilling MK, Redaelli C, Krähenbühl L, Signer C, Büchler MW. Splanchnic microcirculatory changes during CO<sub>2</sub> laparoscopy. *J Am Coll Surg* 1997; 184: 378-382.
- [11] Sammour T, Mittal A, Loveday BP, Kahokehr A, Phillips AR, Windsor JA, Hill AG. Systematic review of oxidative stress associated with pneumoperitoneum. *Br J Surg* 2009; 96: 836-850.
- [12] Hirvonen EA, Nuutinen LS, Kauko M. Hemodynamic changes and pneumoperitoneum during laparoscopic hysterectomy. *Acta Anaesthesiol Scand* 1995; 39: 949-955.
- [13] Walder AD, Aitkenhead AR. Role of vasopressin in the haemodynamic response to laparoscopic cholecystectomy. *Br J Anaesth* 1997; 78: 264-266.
- [14] Joris JL, Chiche JD, Canivet JL, Jaquet NJ, Legros JJ, Lamy ML. Hemodynamic changes induced by laparoscopy and their endocrine correlates: effects of clonidine. *J Am Coll Cardiol* 1998; 32: 1389-1396.
- [15] Szold A, Weinbroum AA. Carbon dioxide pneumoperitoneum related liver injury is pressure dependent: a study in an isolated perfused organ model. *Surg Endosc* 2008; 22: 365-371.
- [16] Unsal MA, Guven S, Imamoglu M, Aydin S, Alver A. The effect of CO<sub>2</sub> insufflation-desufflation attacks on tissue oxidative stress markers during laparoscopy: a rat model. *Fertil Steril* 2009; 92: 363-368.
- [17] Cay A, Imamoglu M, Unsal MA, Aydin S, Alver A, Akyol A, Sarihan H. Does anti-oxidant prophylaxis with melatonin prevent adverse outcomes related to increased oxidative stress caused by laparoscopy in experimental rat model? *J Surg Research* 2006; 135: 2-8.
- [18] Cevrioglu AS, Yilmaz S, Koken T, Tokyol C, Yilmazer M, Fenkci IV. Comparison of the effects of low intra-abdominal pressure and ischaemic preconditioning on the generation of oxidative stress markers and inflammatory cytokines during laparoscopy in rats. *Hum Reprod* 2004; 19: 2144-2151.
- [19] Rauh R, Hemmerling TM, Rist M, Jacobi KE. Influence of pneumoperitoneum and patient positioning on respiratory system compliance. *J Clin Anesth* 2001; 13: 361-365.
- [20] Gutt CN, Oniu T, Mehrabi A, Schemmer P, Kashfi A, Kraus T, Buchler MW. Microcirculatory and respiratory complications of carbon dioxide insufflation. *Dig Surg* 2004; 21: 95-105.
- [21] Runck H, Schumann S, Tacke S, Haberstroh J, Guttman J. Effects of intra-abdominal pres-



## Pneumoperitoneum with high pressure and lung injuries

- sure on respiratory system mechanics in mechanically ventilated rats. *Respir Physiol Neurobiol* 2012; 180: 204-210.
- [22] Chok KS, Yuen WK, Lau WH, Fan ST. Prospective randomized trial on low-pressure versus standard-pressure pneumoperitoneum in outpatient laparoscopic cholecystectomy. *Surg Laparosc Endosc Percutan Tech* 2006; 16: 383-386.
- [23] Hua J, Gong J, Yao L, Zhou B, Song Z. Low-pressure versus standard-pressure pneumoperitoneum for laparoscopic cholecystectomy: a systematic review and meta-analysis. *Am J Surg* 2014; 208: 143-150
- [24] Eleftheriadis E, Kotzampassi K, Papanotas K, Heliadis N, Sarris K. Gut ischemia, oxidative stress, and bacterial translocation in elevated abdominal pressure in rats. *World J Surg* 1996; 20: 11-16.
- [25] Biler A, Yucebilgin S, Sendag F, Akman L, Akdemir A, Ates U, Uyanikgil Y, Yilmaz-Dilsiz O, Sezer E. The effects of different intraabdominal pressure protocols in laparoscopic procedures on oxidative stress markers and morphology in rat ovaries. *Adv Clin Exp Med* 2014; 23: 885-892.
- [26] Yu T, Cheng Y, Wang X, Tu B, Cheng N, Gong J, Bai L. Gases for establishing pneumoperitoneum during laparoscopic abdominal surgery. *Cochrane Database Syst Rev* 2017; 6: CD009569.
- [27] Sies H. Strategies of antioxidant defense. *Eur J Biochem* 1993; 215: 213-219.
- [28] Ozmen MM, Zulfikaroglu B, Col C, Cinel I, Isman FK, Cinel L, Besler TH. Effect of increased abdominal pressure on cytokines (IL1b, IL6, TNFa), C-reactive protein (CRP), free radicals (NO, MDA), and histology. *Surg Laparosc Endosc Percutan Tech* 2009; 19: 142-147.
- [29] Rubini A, Monte DD, Catena V. Effects of the pneumoperitoneum and Trendelenburg position on respiratory mechanics in the rats by the end-inflation occlusion method. *Ann Thorac Med* 2012; 7: 205-209.
- [30] Schwenk W, Jacobi C, Mansmann U, Bohm B and Muller JM. Inflammatory response after laparoscopic and conventional colorectal resections - results of a prospective randomized trial. *Langenbecks Arch Surg* 2000; 385: 2-9.
- [31] Gupta A, Watson DI. Effect of laparoscopy on immune function. *Br J Surg* 2001; 88: 1296-1306.
- [32] Altindis M, Yilmaz S, Polat C, Serteser M. Sequential periods of preconditioning decrease laparoscopy-related elevations in hepatic TNF-alpha and IL-6 levels in rats. *J Laparosc Adv Surg Tech A* 2004; 14: 380-383.
- [33] Ates E, Yilmaz S, Ihtiyar E, Yasar B, Karahuseyinoglu E. Preconditioning-like amelioration of erythropoietin against laparoscopy-induced oxidative injury. *Surg Endosc* 2006; 20: 815-819.
- [34] Strang CM, Ebmeyer U, Maripuu E, Hachenberg T, Hedenstierna G. Improved ventilation-perfusion matching by abdominal insufflation (pneumoperitoneum) with CO<sub>2</sub> but not with air. *Minerva Anesthesiol* 2013; 79: 617-625.
- [35] Papparella A, Nino F, Coppola S. Peritoneal morphological changes due to pneumoperitoneum: the effect of intra-abdominal pressure. *Eur J Pediatr Surg* 2014; 24: 322-327.
- [36] Blobner M, Frick CG, Stauble RB, Feussner H, Schaller SJ, Unterbuchner C, Lingg C, Geisler M, Fink H. Neuromuscular blockade improves surgical conditions (NISCO). *Surg Endosc* 2015; 29: 627-636.
- [37] Biler A, Yucebilgin S, Sendag F, Akman L, Akdemir A, Ates U, Uyanikgil Y, Yilmaz-Dilsiz O, Sezer E. The effects of different intraabdominal pressure protocols in laparoscopic procedures on oxidative stress markers and morphology in rat ovaries. *Adv Clin Exp Med* 2014; 23: 885-892.
- [38] Yoshino O, Quail A, Oldmeadow C. The interpretation of intra-abdominal pressures from animal models: the rabbit to human example injury. *Int J Care Injured* 2012; 43: 169-173.
- [39] Avital S, Itah R, Szomstein S, Rosenthal R, Inbar R, Sckornik Y, Weinbroum A. Correlation of CO<sub>2</sub> pneumoperitoneal pressures between rodents and humans. *Surg Endosc* 2009; 23: 50-54.
- [40] Kontoulis TM, Pissas DG, Pavlidis TE, Pissas GG, Lalountas MA, Koliakos G, Topouridou K, Sakantamis AK. The oxidative effect of prolonged CO(2) pneumoperitoneum a comparative study in rats. *J Surg Res* 2012; 175: 259-264.
- [41] Aran T, Unsal MA, Guven S, Kart C, Cetin EC, Alver A. Carbon dioxide pneumoperitoneum induces systemic oxidative stress: a clinical study. *Eur J Obstet Gynecol Reprod Biol* 2012; 161: 80-83.
- [42] Yiannakopoulou E, Nikiteas N, Perrea D, Tsigris C. Minimally invasive surgery and oxidative stress response: what have we learned from animal studies? *Surg Laparosc Endosc Percutan Tech* 2013; 23: 25-28.
- [43] Sen MC, Turkyilmaz Z, Sonmez K, Karabulut R, Kaya Z, Yenicesu I, Gursel T, Basaklar AC. The effect of carbon dioxide insufflation applied at different pressures and periods on thrombotic factors. *Indian J Hematol Blood Transfus* 2016; 32: 87-91.