

Original Article

Right axillary straight incision with laryngeal mask airway for congenital heart disease in children

Yimin Liu^{1*}, Lei Ji^{2*}, Xin Zhao³, Yufeng Huo¹, Fen Zhao¹, Chao Liu¹, Wenyu Sun^{1*}, Yanwen Bi^{3*}

¹Department of Cardiovascular Surgery, Qilu Hospital of Shandong University, Qingdao 266000, China; ²Department of Cardiovascular Surgery, Qilu Children's Hospital of Shandong University, Jinan 250000, China; ³Department of Cardiovascular Surgery, Qilu Hospital of Shandong University, Jinan 250000, China. *Co-first authors.

Received April 5, 2017; Accepted September 4, 2017; Epub October 15, 2017; Published October 30, 2017

Abstract: Aim: To compare the efficacy of right axillary straight incision with laryngeal mask airway (LMA) and median sternotomy incision with tracheal intubation in treating children with congenital heart disease. Methods: Children with congenital heart disease were followed up for 1-3 years after surgery. There were 32 children using right axillary straight incision with LMA (minimally invasive group) and 36 children using median sternotomy incision with tracheal intubation (routine group). Surgical indicators and airway complications were compared. Results: No significant difference was found in preoperative indicators between groups ($P > 0.05$). The mean operating time, mean cardiopulmonary bypass time and mean aortic cross-clamp time were without significant difference ($P > 0.05$). The mean postoperative hospital stay time ($P < 0.001$), mean ICU stay time ($P < 0.001$), mean postoperative drainage ($P = 0.0067$), mean infusion amount of red blood cells ($P < 0.001$) and mean ventilation time ($P < 0.001$) were significantly lower in minimally invasive group than that in routine group. Airway complications caused by LMA was significantly lower ($P < 0.001$). In routine group, there were 5 cases of pigeon chest and 1 case of pectus excavatum. The scars were with ugly appearance. In minimally invasive group, chest deformity was not occurred and scars were with better appearance. Conclusions: Right axillary straight incision with LMA has less trauma and less airway complications. It should be promoted in children with congenital heart disease.

Keywords: Right axillary straight incision, laryngeal mask airway, median sternotomy incision, tracheal intubation, congenital heart disease

Introduction

Common treatment for patients with congenital heart disease is median sternotomy incision with tracheal intubation, which has been regarded as the gold standard for the treatment of congenital heart disease [1, 2]. But sternal malunion or deformity is often occurred along with this method [3], which may result in negative physiological impact on patients, especially on children with congenital heart disease [4, 5]. In addition, tracheal intubation is difficult to be performed and if an unsuccessful intubation (such as nasal mucosal bleeding) is not recognized, further airway complications would be occurred [6]. More importantly, the occurrence of airway complications will have negative impact on patients' recovery.

Over the past few decades, minimally invasive cardiac surgery techniques have been widely

used in patients with congenital heart disease, especially paediatric patients [7-9]. Right axillary straight incision is a minimally invasive technique. The scar caused by this method is hidden in the armpit without affecting the visual appearance. Previous studies have showed that deformity development, such as asymmetric development of the chest or breast, was not occurred by right axillary incision [10]. Also, it is worth noting that laryngeal mask airway (LMA), which is easy to perform even by an inexperienced clinicians, can effectively reduce the risk of airway complications [11], while it has not been widely used in pediatric patients [2].

So in this research, right axillary straight incision with LMA was used for the treatment of pediatric patients with congenital heart disease, with median sternotomy incision with tracheal intubation as the control treatment method. The clinical results of these two methods

Right axillary straight incision with LMA

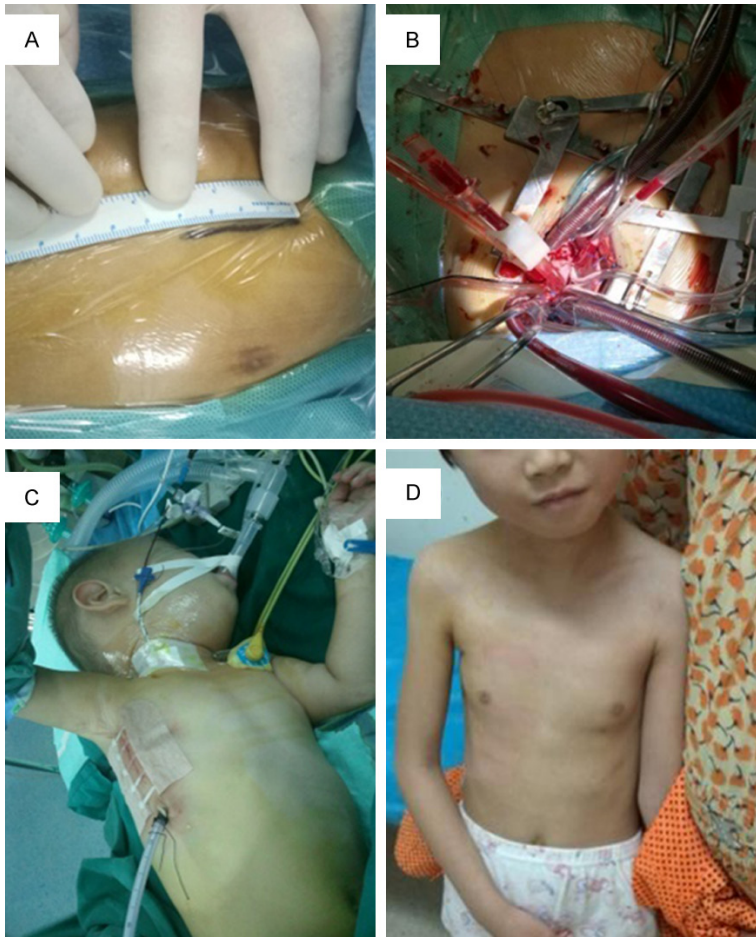


Figure 1. Surgical procedures of right axillary straight incision with LMA. A: The length and position of the skin incision. The midpoint of the incision was the intersection of the right nipple and the axillary midline. The incision length was 4-5 cm. B: The view of cardiopulmonary bypass. Ascending aortic cannulation, superior vena cava cannulation and inferior vena cava cannulation were performed to establish cardiopulmonary bypass. C: The photo of postoperative. Chest drainage tube was placed through the seventh intercostals in the right axillary midline. D: The photo of the patient chest one week after surgery. The incision scar was hidden below the right armpit. Asymmetry of the chest or breast was not occurred.

were compared to evaluate their efficacy. It was the first time that right axillary straight incision with LMA was applied in paediatric patients with congenital heart disease. It will provide an important guiding significance for the treatment of congenital heart disease in children.

Materials and methods

Patients

Inclusion criteria: Patients meeting the following criteria were included in the study: atrial septal defect (ASD) (type I membranous or perimembranous ventricular septal defect (VSD);

partial endocardial cushion defect (PECD); three-chamber heart; intracardiac total anomalous pulmonary venous drainage; body weight: 7-35 kg; patients who were not suitable for interventional closure according to cardiac color ultrasound or cardiac catheterization.

Exclusion criteria: Patients with the following complications were excluded: respiratory-tract infection; right thorax deformity; right pleura with severe adhesion due to right thoracic surgery or trauma history; pulmonary artery systolic pressure ≥ 70 mmHg; subarterial or muscular VSD; suprasternal or intracostal VSD; complex congenital heart disease; body weight < 7 kg or > 35 kg; serious deformity in mouth, pharynx and respiratory-tract.

Ultimately, 68 children with congenital heart disease (38 were male and 30 were female; age range: 7 months-12 years old; weight range: 7-35 kg) were enrolled in this retrospective study and they were divided into two groups according to the surgical methods. The 32 patients (11 cases of ASD, 17 cases of VSD, 3 cases of PECD and 1 case of three-chamber heart) who

underwent right axillary straight incision with LMA were named as minimally invasive group. The remaining 36 patients (9 cases of ASD, 23 cases of VSD, 4 cases of PECD) were treated by median sternotomy incision with tracheal intubation and they were designated as routine group. Patients in minimally invasive group were collected from October 2012 to May 2015 and routine group patients were collected from January 2010 to May 2015.

This study was approved by our hospital ethics committee and informed consent was obtained from patients and their families.

Right axillary straight incision with LMA

Table 1. Comparison of preoperative data of minimally invasive group and routine group (% , mean \pm sd)

| Clinical indicators | Minimally invasive group | Routine group | P value |
|--|--------------------------|-----------------|---------|
| Age (years) | 2.9 \pm 0.9 | 2.8 \pm 0.7 | 0.6087 |
| Body weight (kg) | 10.9 \pm 4.3 | 9.5 \pm 3.6 | 0.1488 |
| NYHA | 1.1 \pm 0.2 | 1.1 \pm 0.3 | > 0.05 |
| Left ventricular ejection fraction (%) | 63.2 \pm 6.4 | 62.3 \pm 5.3 | 0.5282 |
| Cardiothoracic ratio | 0.60 \pm 0.07 | 0.59 \pm 0.11 | 0.6608 |

NYHA: classification of cardiac function.

Methods

Anesthetic technique: After propofol intravenous induction (1-2 mg/kg), intravenous inhalation combined general anesthesia (sevoflurane combined with propofol) was performed during the entire surgical procedure. The same anesthetic technique was used by all patients. The LMA was used in minimally invasive group and nasal tracheal intubation was used in routine group.

Surgical methods: For minimally invasive group, patients were placed in the left lateral decubitus position after the induction of general anesthesia. The left armpit was raised to expand the right intercostal space, and the right arm was suspended over the head with a 90° bend between forearm and upper arm. The incision was started from the intersection of the right nipple and the axillary midline with a length of 4-5 cm (**Figure 1A**). Then the right thoracic cavity was accessed from the 4th intercostal space. Tissue scissors handle was used to temporarily retract the right lung and thymus was properly separated without resection. Then the pericardium was opened longitudinally along the space between the aorta and pulmonary artery, and when the incision was reached to the junction of the diaphragm, a transverse incision was made. Then a “⊥” type incision was presented. Pericardium around the aorta was hanged with sling suture for about 4-5 needles. Ascending aortic cannulation, superior vena cava cannulation and inferior vena cava cannulation were performed to establish cardiopulmonary bypass (**Figure 1B**). Right angle cannula was used as the superior vena cava cannula. It was also used as the inferior vena cava cannula for patients with inferior vena cava type ASD. Thus it was more easily to expose the lower edge of the ASD. Single purse-string suture was used for all cannulation.

Myocardial protection was performed by perfusion blood cardioplegia from the aortic root. Closure of the septal defect was accomplished by utilizing a patch of bovine pericardium after a right atriotomy was performed. Cardiopulmonary bypass was ended after the right atrium incision suture was completed. Protamine and heparin were injected through central ve-

nous and then pericardial longitudinal incision was sutured. Chest drainage tube was placed through the seventh intercostals in the right axillary midline. At last, the right axillary straight incision was closed layer by layer with the conventional method (**Figure 1C**).

For routine group, the patients were placed in the supine position and a median sternotomy incision was made. The main surgical procedures were similar to those used in the minimally invasive group. A patch of bovine pericardium was also used to closure the septal defect. The difference was that mediastinal drainage was used during postoperative drainage period.

Patients in both groups were followed up for 1-3 years after surgery.

Statistical analysis

All data were analyzed by SPSS 17.0. Measurement data were expressed as mean \pm standard deviation (SD). Continuous variables were analyzed by independent sample t-test. Count data, which were recorded as percentage, were compared by χ^2 -test. $P < 0.05$ was considered statistically significant.

Results

Demographic characteristics and preoperative indicators

The demographic characteristics and preoperative indicators of the two groups were detailed in **Table 1**. There was no significant difference in the mean age and the average weight between the two groups ($P > 0.05$). At the same time, no significant difference was found in NYHA, left ventricular ejection fraction and cardiothoracic ratio between the two groups ($P > 0.05$).

Table 2. Comparison of postoperative data of minimally invasive group and routine group (% , mean \pm sd)

| Clinical indicators | Minimally invasive group | Routine group | P value |
|--|--------------------------|-------------------|---------|
| Surgery time (min) | 155.9 \pm 45.6 | 176.5 \pm 50.1 | 0.0825 |
| Cardiopulmonary bypass time (min) | 54.9 \pm 30.9 | 69.1 \pm 28.0 | 0.0515 |
| Aortic cross-clamp time (min) | 25.7 \pm 8.4 | 29.6 \pm 8.5 | 0.0619 |
| Postoperative hospital stay (d) | 6.1 \pm 1.84 | 7.9 \pm 1.66 | < 0.001 |
| Postoperative drainage (mL/kg) | 7.5 \pm 4.1 | 11.2 \pm 6.4 | 0.0067 |
| Infusion amount of red blood cells (U) | 0.8 \pm 0.6 | 1.8 \pm 0.7 | < 0.001 |
| Ventilation time (h) | 2.2 \pm 1.1 | 4.8 \pm 2.1 | < 0.001 |
| ICU stay (h) | 48.36 \pm 18.24 | 72.00 \pm 23.84 | < 0.001 |

ICU: Intensive Care Unit.

Intraoperative and postoperative results

The intraoperative and postoperative results in either group were listed in **Table 2**. The differences in the mean operating time ($P = 0.0825$), mean cardiopulmonary bypass time ($P = 0.0515$) and mean aortic cross-clamp time ($P = 0.0619$) between the two groups were not significant. However, the mean postoperative hospital stay time of patients in minimally invasive group (6.1 \pm 1.84 days) was significantly shorter than that of routine group (7.9 \pm 1.66 days) ($P < 0.001$). Moreover, significantly shorter mean ICU stay time was found in minimally invasive group (48.36 \pm 18.24 h) when compared to routine group (72.00 \pm 23.84 h) ($P < 0.001$). In addition, the mean postoperative drainage (7.5 \pm 4.1 mL/kg vs. 11.2 \pm 6.4 mL/kg, $P = 0.0067$), mean infusion amount of red blood cells (0.8 \pm 0.6 U vs. 1.8 \pm 0.7 U, $P < 0.001$) and mean ventilation time (2.2 \pm 1.1 h vs. 4.8 \pm 2.1 h, $P < 0.001$) were also significantly lower in minimally invasive group than that of routine group.

Incidence of airway complications

The incidence of airway complications was significantly lower in minimally invasive group (12.5%) than that of routine group (47.2%) ($P = 0.002$). In minimally invasive group, 4 patients occurred airway complications, including 3 cases of heart rate fluctuations and 1 case of nasal endotracheal tube balloon leakage, while a total of 17 patients occurred airway complications in routine group, including 5 cases of heart rate fluctuations, 2 cases of tracheal intubation failure at the first time, 3 cases of airway mucosal bleeding, 2 cases of leakage phenomenon, 3 cases of hoarse voice, 1 cases of

laryngeal edema and 1 cases of excessive tracheal intubation insertion depth. But no fetal complication was occurred in these two groups. During follow-up, no patient suffered long-term airway complications (**Table 3**).

Deformity development and wound healing

During follow-up, asymmetric development of chest or breast was not occurred in minimally invasive group (**Figure 1D**). The incision scar was hidden below the right armpit without affecting the visual appearance. However, long-term follow-up results also showed that 5 cases were occurred pigeon chest and 1 case was with pectus excavatum in routine group. The scars were also with ugly appearance. All wounds of patients in minimally invasive group were healed well than that of routine group.

Discussion

In this research, the efficacy of right axillary straight incision with LMA and median sternotomy incision with tracheal intubation in treating children with congenital heart disease were compared. The results indicated that right axillary straight incision with LMA was more conducive to patients' postoperative recovery with much lower airway complications incidence. Moreover, asymmetric development of chest or breast was also not occurred by this method, while 6 patients undergoing median sternotomy incision with tracheal intubation were occurred chest deformity, illustrating that right axillary straight incision with LMA was more conducive to the long-term development of patients, especially pediatric patients. It was a more secure and reliable method than median sternotomy incision with tracheal intubation.

Median sternotomy, which can meet the demand of a variety cardiac surgery, is considered as the classic method of cardiac surgery [3, 12]. However, sternal bone scaffolds are destroyed and the continuity of the thorax is changed by this method, which will lead to form pigeon chest or pectus excavatum after surgery

Right axillary straight incision with LMA

Table 3. Incidence of adverse events of artificial airway (%)

| Clinical indicators | Minimally invasive group (number; rate/%) | Routine group (number; rate/%) |
|---|--|-----------------------------------|
| Heart rate fluctuations | 3; 9.38% | 5; 13.89% |
| Tracheal intubation failure at the first time | 0; 0% | 2; 5.56% |
| Airway mucosal bleeding | 0; 0% | 3; 8.33% |
| Leakage phenomenon | 1; 3.12% | 2; 5.56% |
| Hoarse voice | 0; 0% | 3; 8.33% |
| Laryngeal edema | 0; 0% | 1; 2.78% |
| Excessive tracheal intubation insertion depth | 0; 0% | 1; 2.78% |
| Total rate of adverse event | 12.5% | 47.2% |

and further result in negative physiological effects to patients, especially pediatric patients [4, 5]. In addition, anterior mediastinal tissue is severely damaged because the sternum is longitudinal incised, which will not only increase the amount of intraoperative and postoperative bleeding, but also affect the function of thymus in children.

Right axillary straight incision, of which incision is located in the axillary line, is not damage the breast and pectoralis muscle. The integrity of the thorax is maintained and the development of breast and muscle tissue is not affected. The satisfactory surgical field exposure is achieved by appropriate pericardial suspension and the incision scar is hidden below the right armpit without affecting the visual appearance. Previous study also showed that patients didn't develop asymmetric development of the chest or breast by right axillary straight incision [10]. Our study results were consistent with this result. In addition, surgical trauma may be associated with postoperative pain and discomfort. Right axillary straight incision greatly reduces the trauma caused by surgery, which helps to facilitate faster recovery of patients. All of these advantages make this method a preferred therapy for patients with congenital heart disease, especially pediatric patients and it provides a good access for a safe repair of cardiac defects [13]. Patients with right axillary straight incision will have a higher quality of life after surgery [14]. It appears to be a safe and effective alternative to median sternotomy [15, 16].

The conventional artificial airway for congenital heart disease surgery is tracheal intubation [13]. However, the tissue mucosa of pediatric patient is always delicate, and tracheal intuba-

tion is more likely to cause tissue damage, even glottic edema [6, 17]. These defects make it more difficult to perform in pediatric patients. The incidence of airway complications is also very serious. The most common laryngeal lesions are vocal cord paralysis, granuloma, cartilage dislocation and hematoma. Tracheal intubation has been unable to avoid these airway complications. However, LMA is easy to operate and it can be quickly learnt by inexperienced personnel [18, 19]. Those airway complications caused by tracheal intubation can be effectively avoided by LMA. Significantly reduced airway complications are also conducive to patients' postoperative rehabilitation. Our findings also confirmed this viewpoint. It is more secure and effective than tracheal intubation. In this study, the minimally invasive artificial airway was established by using the LMA, which was the first time for children with congenital heart disease to use the LMA as the ventilation strategy, which had important clinical significance.

In conclusion, it is the first time for children with congenital heart disease to use right axillary straight incision with LMA, which is more safe and reliable than median sternotomy incision with tracheal intubation. The minimally invasive incision is hidden below the armpit without affecting the visual appearance. More importantly, it does not destroy the continuity of the bony thorax and main muscles of the chest. Complications caused by tracheal intubation are also effectively avoided by using LMA, which can help patients' recovery as soon as possible. In addition, this method is easy to operate and does not require special equipment and instruments, which should be popularized clinically.

Disclosure of conflict of interest

None.

Address correspondence to: Wenyu Sun, Department of Cardiovascular Surgery, Qilu Hospital of Shandong University, Qingdao 266000, China. Tel: +86-0531-82166581; Fax: +86-0531-82166581; E-mail: sunwenyu1ghg@21cn.com; Yanwen Bi, Department of Cardiovascular Surgery, Qilu Hospital of Shandong University, No.107 Culture West Road, Jinan 250000, China. Tel: +86-0531-82166581; Fax: +86-0531-82166581; E-mail: biyanwen369@163.com

References

- [1] Abdel-Rahman U, Wimmer-Greinecker G, Matheis G, Klesius A, Seitz U, Hofstetter R, Moritz A. Correction of simple congenital heart defects in infants and children through a minithoracotomy. *Ann Thorac Surg* 2001; 72: 1645-9.
- [2] Blevin AE, McDouall SF, Rechner JA, Saunders TA, Barber VS, Young JD, Mason DG. A comparison of the laryngeal mask airway with the facemask and oropharyngeal airway for manual ventilation by first responders in children. *Anaesthesia* 2009; 64: 1312-1316.
- [3] Hu CX, Tan J, Chen S, Ding H, Xu ZW. Comparison of clinical outcomes and postoperative recovery between two open heart surgeries: minimally invasive right subaxillary vertical thoracotomy and traditional median sternotomy. *Asian Pac J Trop Med* 2014; 7: 625-629.
- [4] Yang X, Wang D, Wu Q. Repair of atrial septal defect through a minimal right vertical infra-axillary thoracotomy in a beating heart. *Ann Thorac Surg* 2001; 71: 2053-4.
- [5] Yaliniz H, Topcuoglu MS, Gocen U, Atalay A, Keklik V, Basturk Y, Gunes Y, Turktan M, Salihi OK. Comparison between minimal right vertical infra-axillary thoracotomy and standard median sternotomy for repair of atrial septal defects. *Asian J Surg* 2015; 38: 199-204.
- [6] Katz SH, Falk JL. Mislplaced endotracheal tubes by paramedics in an urban emergency medical services system. *Ann Emerg Med* 2001; 37: 32-7.
- [7] Seipelt RG, Popov A, Danner B, Paul T, Tirilomis T, Schoendube FA, Ruschewski W. Minimally invasive partial inferior sternotomy for congenital heart defects in children. *J Cardiovasc Surg (Torino)* 2010; 51: 929-933.
- [8] Gil-Jaurena JM, Zabala JI, Conejo L, Cuenca V, Picazo B, Jiménez C, Castillo R, Ferreiros M, de Mora M, Gutiérrez de Loma J. Minimally invasive pediatric cardiac surgery. Atrial septal defect closure through axillary and submammary approaches. *Rev Esp Cardiol* 2011; 64: 208-12.
- [9] Yan L, Zhou ZC, Li HP, Lin M, Wang HT, Zhao ZW, Gao QY, Ge JJ. Right vertical infra-axillary mini-incision for repair of simple congenital heart defects: a matched-pair analysis. *Eur J Cardiothorac Surg* 2013; 43: 136-41.
- [10] Prêtre R, Kadner A, Dave H, Dodge-Khatami A, Bettex D, Berger F. Right axillary incision: a cosmetically superior approach to repair a wide range of congenital cardiac defects. *J Thorac Cardiovasc Surg* 2005; 130: 277-281.
- [11] Timmermann A, Cremer S, Heuer J, Braun U, Graf BM, Russo SG. [Laryngeal mask LMA supreme. Application by medical personnel inexperienced in airway management]. *Anaesthetist*. 2008; 57: 970-5.
- [12] Fukunaga N, Yuzaki M, Shomura Y, Fujiwara H, Nasu M, Okada Y. Clinical outcomes of open heart surgery in patients with atopic dermatitis. *Asian Cardiovasc Thorac Ann* 2012; 20: 137-140.
- [13] Prêtre R, Kadner A, Dave H, Dodge-Khatami A, Bettex D, Berger F. Right axillary incision: a cosmetically superior approach to repair a wide range of congenital cardiac defects. *J Thorac Cardiovasc Surg* 2005; 130: 277-281.
- [14] Iribarne A, Easterwood R, Chan EY, Yang J, Soni L, Russo MJ, Smith CR, Argenziano M. The golden age of minimally invasive cardiothoracic surgery: current and future perspectives. *Future Cardiol* 2011; 7: 333-46.
- [15] Badhwar V, Anastacio MM, Wei LM. Video-assisted minimally invasive mitral valve surgery: transitioning from sternotomy to mini-thoracotomy. *Multimed Man Cardiothorac Surg* 2013; 2013: mmt016.
- [16] Umakanthan R, Petracek MR, Leacche M, Solenkova NV, Eagle SS, Thompson A, Ahmad RM, Greelish JP, Ball SK, Hoff SJ, Absi TS, Balaguer JM, Byrne JG. Minimally invasive right lateral thoracotomy without aortic cross-clamping: an attractive alternative to repeat sternotomy for reoperative mitral valve surgery. *J Heart Valve Dis* 2010; 19: 236-43.
- [17] Cook TM, Hommers C. New airways for resuscitation? *Resuscitation* 2006; 69: 371-87.
- [18] MMorse Z, Sano K, Kageyama I, Kanri T. The relationship of placement accuracy and insertion times for the laryngeal mask airway to the training of inexperienced dental students. *Anesth Prog* 2002; 49: 9-13.
- [19] Brimacombe J, Keller C. Insertion of the LMA-Unique with and without digital intraoral manipulation by inexperienced personnel after manikin-only training. *J Emerg Med* 2004; 26: 1-5.