

Case Report

Deep vein thrombosis and intraperitoneal hemorrhage after thrombolysis: rare complication of laparoscopic varicocelectomy

Zhirong Zhu, Shouhua Pan

Department of Urology, Shaoxing People's Hospital, Shaoxing Hospital of Zhejiang University, Shaoxing, Zhejiang, China

Received April 30, 2016; Accepted August 6, 2016; Epub October 15, 2016; Published October 30, 2016

Abstract: A rare case of a patient who had an uncommon complication of deep vein thrombosis (DVT) and intraperitoneal hemorrhage after thrombolysis following laparoscopic Varicocelectomy (LV) is reported in this paper. The patient was a 31-year-old man, experienced the treatment with bilateral LV because of infertility. Color Doppler Ultrasound (CDU) showed DVT, and then percutaneous implantation of inferior vena cava filter (IVCF) and catheter directed thrombolysis (CDT) were performed during the treatment. After the urokinase thrombolytic therapy, the patient was diagnosed intraperitoneal hemorrhage and was treated with laparoscopic exploration. The patient recovered favorably, being discharged by oral anticoagulation therapy and supported by compression elastic bandages for 6 months. It is concluded that DVT following LV should be paid more attention and it is also critical to have a high index of suspicion for intraperitoneal hemorrhage after thrombolysis. Laparoscopic exploration should be used as a minimally invasive approach because of its clear advantages over open surgery.

Keywords: Deep vein thrombosis, hemorrhage, laparoscopy, varicocelectomy

Introduction

Varicoceles have been associated with impaired semen quality and decreased Leydig cell function, and this impairment has been shown to be progressive in nature [1]. The management of varicoceles in the adolescent male is a controversial topic. While the indications for intervention can be debated, effective treatment options are available when intervention is deemed appropriate [2]. Now, LV is recognized as the most commonly performed surgical procedure for varicoceles.

Venous thrombosis and pulmonary embolism (VTE) are known to occur in major pelvic surgeries which last for more than 2 hours. Clinically significant VTE rarely happens following urological surgery in the absence of malignancy, prolonged surgical anesthesia or hypercoagulable factors. LV is considered to be less invasive, with the possible of early ambulation. Therefore, DVT rarely occurs after the LV. However, a case of DVT following LV leading to intraperitoneal

hemorrhage after thrombolysis in a young man occurred in our hospital, and the symptoms and treatment process are described and analyzed here. To the best of our knowledge, this complication is extremely unique, which has not been reported before.

Case report

A 31-year-old man was admitted to our hospital because of infertility. On physical examination, bilateral varicoceles were large enough to be detected without the Valsalva maneuver. CDU revealed that the left spermatic vein of the patient was 3.04 mm and the right one was 2.92 mm in diameter (**Figure 1**). The spermogram of him showed that he had oligoasthenospermia (1.8×10^6 sperms/ml). The patient referred to swelling of the right leg the day after total LV operation which was completed in 32 minutes. CDU showed proximal DVT involving the right external iliac vein and femoral vein, and the D-dimer testing was positive (38.7 $\mu\text{g/ml}$). The patient did not have any symptoms of

Deep vein thrombosis after laparoscopic varicocelectomy

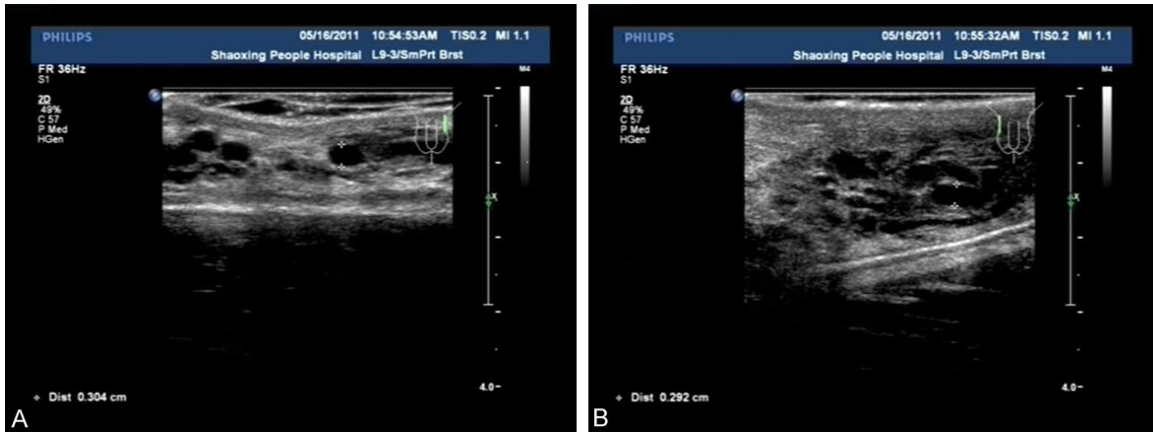


Figure 1. (A) CDU showing 3.04 mm in diameter of the left spermatic vein and (B) 2.92 mm in diameter of the right spermatic vein.

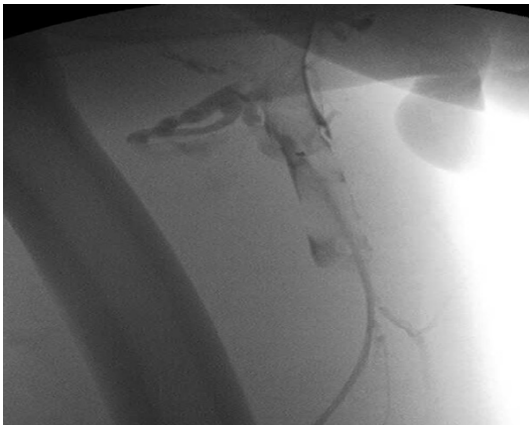

Figure 2. Digital subtraction angiography (DSA) showing DVT.

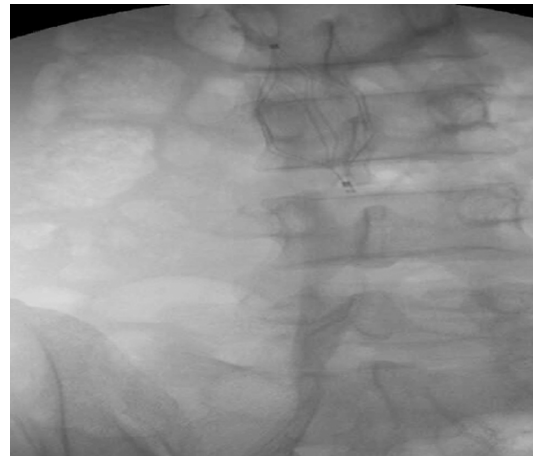


Figure 3. The treatment of IVCF implantation.

pulmonary embolism. He was of medium build, medium nutrition, without medical history, and his body mass index (BMI) was 23 kg/m².

The patient was transferred to the department of vascular surgery immediately, submitted to the treatment of IVCF implantation and CDT (Figures 2, 3). He had been given low molecular weight heparin (Fraxiparin 0.4 ml twice daily) subcutaneously and micro pump maintenance of urokinase infusion. After 2 days, the patient noticed the pain in the right abdomen. The CDU revealed that there was free liquid in the hepatorenal recess and the pelvic cavity, which was considered as intraperitoneal hemorrhage. Laparoscopic surgery was performed to explore the reason of bleeding at once, and 2000 cc abdominal blood and crassamatum in the right trocar acanthopore

were found during the operation. A drainage tube was set in abdominal cavity after hemo-peritoneum removing. Ten days later, the IVCF on the patient was removed and exchanged with anticoagulation therapy (Rivaroxaban 10 mg once daily) (Figure 4). He was advised to have oral anticoagulation and compression elastic bandages for the next 6 months to prevent the recurrent venous thrombosis.

Discussion

DVT, with low incidence, is a serious complication after urological operation which often occurs after urological neoplasm surgery or transurethral resection of the prostate, but rarely following LV. The typical symptoms of DVT include obviously limb swelling, pain and tenderness. Diagnosis of common image me-

Deep vein thrombosis after laparoscopic varicocelectomy

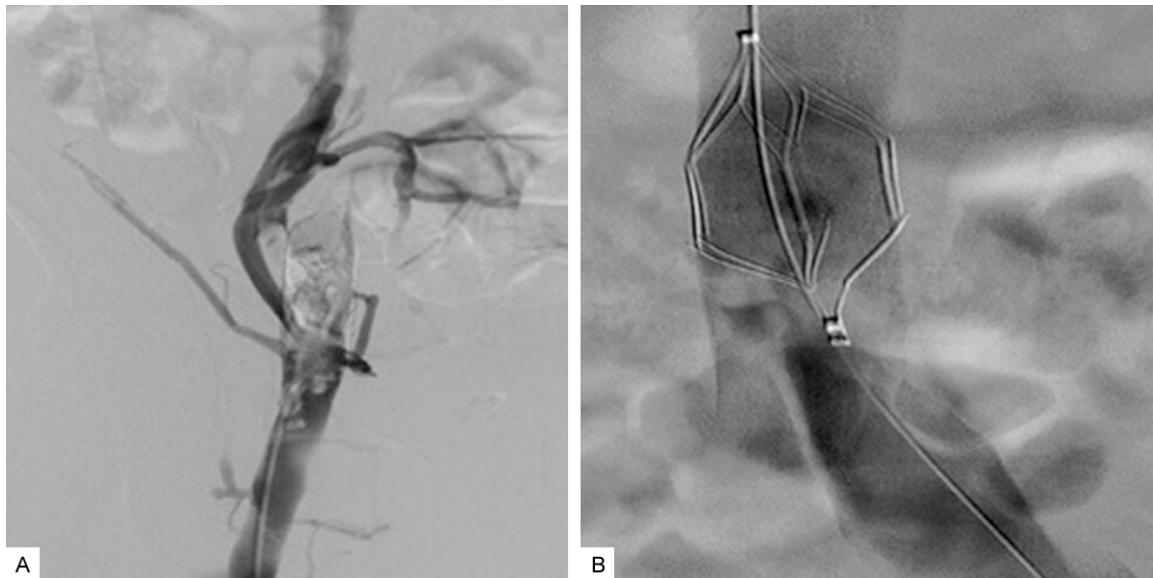


Figure 4. (A) DSA showing the continuous flow of right lower extremity deep vein and (B) the removal of IVCF after CDT.

thods consist of CDU, Multi-slice spiral CT angiography (MSCTA), Magnetic resonance imaging (MRA), and digital subtraction angiography (DSA), among which DSA is considered to be the best diagnostic strategy [3]. D-dimer has positive correlation with thrombus volume [4]. Although it has low specificity, which will increase in the inflammation, malignancy, operation, trauma and empyrosis. It can be used as a diagnosis and curative effect index of DVT, to help for the prognosis of patients.

The exact mechanism of DVT after LV is unclear. The Virchow triad describes thrombosis related to three factors: alteration in venous flow, endothelial injury and hypercoagulability. Laparoscopy is regarded as a moderate risk for DVT, CO₂ pneumoperitoneum and reversed Trendelenburg position reduce lower limbs venous return, provokes venous stasis, and consequently increases the risk of venous thrombosis [5]. In LV, it has been speculated that i. Endothelial injury and explosion of collagen fiber which are caused by ligation of varicoceles, lead to hypercoagulability. ii. CO₂ Pneumoperitoneum, which directly presses the iliac vein and the inferior vena cava to block the backing of the lower venous blood, leads to alteration in venous flow. iii. Hypercapnia, which is also caused by CO₂, leads to dysfunction of endothelial, such as the increas-

ing of endothelin secretions causes strong contraction of blood vessels that accelerate thrombosis. iv. Slow blood flow is caused by anesthesia.

As reported by some literatures, the risk factors of DVT include obesity (Triglyceride (TG)>1.75 g/l, BMI>30 kg/m²), age (over 65 years), major surgeries of cardiovascular, orthopedic, neurosurgical and pelvic nature which last for several hours, poor anaesthetic status, trauma, hospital or nursing home confinement, malignancy, deep vein catheterization and varicose veins [6]. DVT is predominantly a disease of middle age and the elderly [7]. It is very rare before the age of 20 years and rare before 40 years [8]. However, in this case, the patient was a young man, whose BMI was 23 kg/m², without history of malignancy and one day confinement post-operation. Therefore, it can be concluded that factor such as the laparoscopic pelvic vascular surgery may play a crucial role, which should be paid more attention. Van Rij et al. reported that the incidence of DVT following varicose vein surgery was higher than previously thought [9]. Xu et al. revealed that the levels of endothelin and thromboxane in spermatic vein of patients with varicocele were high, which were related to venous thrombosis [10]. In consequence, it is supposed that patient with varicocele may be easily complicated by DVT after surgery. According to the literature review, there are

limited reports introduced spontaneous spermatic vein thrombosis, which is a very uncommon clinical entity [11]. However, the onset of it should be considered as a possible event in patients with inguinal and scrotal pain after varicocelectomy [12]. Coban et al. felt that the endothelial dysfunction that initiates the intravascular thrombosis in the group of patients with varicocele could be associated with Mean platelet volume (MPV) elevation [13]. Although cases of pulmonary embolism associated with spermatic vein thrombosis were reported [14], it is unclear whether our patient with spermatic vein thrombosis after LV or not, which may have an influence on the pathogenesis of his DVT condition. Nevertheless, one or both of these factors played a key role in this process, and further studies are required to solidify this conclusion. It is supposed that the suspicion of this entity is crucial for a prompt diagnosis.

Currently, the main treatments for DVT are: IVCF implant, CDT and Percutaneous Venous Thrombectomy etc [15]. The IVCF implantation has become the effective prevention of venous thrombosis which leads to lethal PE and it is more and more popular in interventional therapy. As the most common and effective approach, CDT can significantly reduce the dosage and treatment time, prevent complications. CaVenT Study's research showed that CDT could significantly improve the venous patency rate and the life quality of patients compared with simply anticoagulant therapy. The effectiveness and reliability of CDT in treating DVT was also validated [16]. Nevertheless, bleeding as a complication of CDT deserves our vigilance. Alesh et al. reported that the bleeding rates for CDT were higher than the other methods [17]. The variable of thrombolytic agents and the duration of therapy may all have effects on the outcome. In order to decreasing the risk of bleeding, percutaneous mechanical thrombectomy is a safe and effective treatment for acute massive DVT [18]. In our case, the complicated intraperitoneal hemorrhage after thrombolysis following LV of the patient may be caused by the puncture vascular injury, doses of thrombolytic agents or other factors. In order to minimize the adverse consequences, we managed to take measures on the intraperitoneal hemorrhage which was recognized as a serious complication of laparoscopic surgery. Laparoscopic exploration, which has been advocated as one

of the best minimally invasive techniques for intraperitoneal hemorrhage, can easily identify the bleeding. The obtained satisfactory result in this case is the best proof.

Conclusions

DVT following laparoscopic pelvic vascular surgery which last less than 2 hours, such as LV, should be paid more attention even if the patient may be young, has no obese, no hospital confinement and no history of malignancy. CDU is a diagnostic approach and D-dimer testing plays a confirmatory role by providing additional information, both of which should be performed in all suspected cases in order to provide the patients suitable treatment option without any delay. There is still a high risk of intraperitoneal hemorrhage after thrombolysis following laparoscopic surgery and it is necessary to counsel the patient regarding rare potential situation. If intraperitoneal hemorrhage happens, laparoscopic exploration as a minimally invasive approach is highly recommended because of its clear advantages over open surgery.

Disclosure of conflict of interest

None.

Address correspondence to: Department of Urology, Shaoxing People's Hospital, Shaoxing Hospital of Zhejiang University, 568 Zhongxing North Road, Shaoxing 312000, Zhejiang, China. Tel: 086137-35373006; Fax: 086057588229252; E-mail: zhzl-4485@163.com

References

- [1] Lipshultz RI, Thomas JR, Khera M. Surgical management of male Infertility in: Campbell-Walsh Urology. 9th edition. Philadelphia: Saunders; 2007. pp. 20-198.
- [2] Vander Brink BA, Palmer LS, Gitlin J, Levitt SB, Franco I. Lymphatic-Sparing Laparoscopic Varicocelectomy versus Microscopic Varicocelectomy: Is There a Difference? *Urology* 2007; 70: 1207-1210.
- [3] Goodacre S, Stevenson M, Wailoo A, Sampson F, Sutton AJ, Thomas S. How should we diagnose suspected deep-vein thrombosis? *QJM* 2006; 99: 377-388.
- [4] Kurklinsky AK, Kalsi H, Wysokinski WE, Mauck KF, Bhagra A, Havyer RD, Thompson CA, Hayes SN, McBane RD 2nd. Fibrin D-dimer concentration, deep vein thrombosis symptom dura-

Deep vein thrombosis after laparoscopic varicocelectomy

- tion, and venous thrombus volume. *Angiology* 2011; 62: 253-256.
- [5] Catheline JM, Turner R, Gaillard JL, Rizk N, Champault G. Thromboembolism in laparoscopic surgery: risk factors and preventive measures. *Surg Laparosc Endosc Percutan Tech* 1999; 9: 135-139.
- [6] Obalum DC, Giwa SO, Adekoya-Cole TO, Ogo CN, Enweluzo GO. Deep vein thrombosis: risk factors and prevention in surgical patients. *West Afr J Med* 2009; 28: 77-82.
- [7] Sotunmbi PT, Idowu AT, Akang EEU, Aken'Ova YA. Prevalence of venous thromboembolism at post-mortem in an African population: a cause for concern. *Afr J Med Med Sci* 2006; 35: 345-348.
- [8] Van Ommen CH, Heijboer H, Buller HR, Hiras-ing RA, Heijmans HS, Peters M. Venous thromboembolism in childhood: a prospective two-year registry in The Netherlands. *J Pediatr* 2001; 139: 676-681.
- [9] Van Rij AM, Chai J, Hill GB, Christie RA. Incidence of deep vein thrombosis after varicose vein surgery. *Br J Surg* 2004; 91: 1582-1585.
- [10] Xu QQ, Zhu JC, Jiang H, et al. Study of the changes of endothelin and thromboxane in varicocele. *Zhonghua Nan Ke Xue* 2001; 7: 38-39.
- [11] Kleinclaus F, Della NE, Martin M, Bernardini S, Bittard H. Spontaneous thrombosis of left varicocele. *Prog Urol* 2001; 11: 95-96.
- [12] Zampieri N, Castellani R, Mantovani A, Scirè G, Peretti M, Zampieri G, Camoglio FS. Thromboses of the pampiniform plexi after subinguinal varicocelectomy. *Pediatr Surg Int* 2014; 30: 441-444.
- [13] Coban S, Keleş I, Bıyık I, Güzelsoy M, Türkoğlu AR, Özgünay T, Ocak N. Is there any relationship between mean platelet volume and varicocele? *Andrologia* 2015; 47: 37-41.
- [14] Castillo OA, Diaz M, Vitagliano GJ, Metrebian E. Pulmonary thromboembolism secondary to left spermatic vein thrombosis: a case report. *Urol Int* 2008; 80: 217-218.
- [15] Kearon C, Kahn SR, Agnelli G, Goldhaber S, Raskob GE, Comerota AJ. Antithrombotic therapy for venous thromboembolic disease: American college of chest physicians evidence-based clinical practice guidelines (8th Edition). *Chest* 2008; 133: 454S-545S.
- [16] Enden T, Haig Y, Kløw NE, Slagsvold CE, Sandvik L, Ghanima W, Hafsaht G, Holme PA, Holmen LO, Njaastad AM, Sandbæk G, Sandset PM; CaVenTStudy Group. Long-term outcome after additional catheter-directed thrombolysis versus standard treatment for acute iliofemoral deep vein thrombosis (the CaVenT study): a randomised controlled trial. *Lancet* 2012; 379: 31-38.
- [17] Alesh I, Kayali F, Stein PD. Catheter-directed thrombolysis (intrathrombus injection) in treatment of deep venous thrombosis: a systematic review. *Catheter Cardiovasc Interv* 2007; 70: 143-148.
- [18] Shi HJ, Huang YH, Shen T, Xu Q. Percutaneous mechanical thrombectomy for acute massive lower extremity deep venous thrombosis. *Surg Laparosc Endosc Percutan Tech* 2011; 21: 50-53.