

Original Article

The protective effect of intraperitoneal medical ozone preconditioning and treatment on hepatotoxicity induced by methotrexate

Arif Aslaner¹, Tuğrul Çakır¹, Betül Çelik², Uğur Doğan¹, Cebirail Akyüz³, Ahmet Baştürk⁴, Cemal Polat⁵, Umut Gündüz¹, Burhan Mayır¹, Ahmet Özer Şehirli^{6,7}

Departments of ¹General Surgery, ²Pathology, Antalya Education and Research Hospital, Antalya, Turkey; ³Department of Gastroenterologic Surgery, Haydarpaşa Training and Research Hospital, Istanbul, Turkey; ⁴Department of Pediatric Gastroenterology, Akdeniz University, Antalya, Turkey; ⁵Department of Biochemistry, Public Health Laboratory, Kütahya, Turkey; ⁶Department of Pharmacology, Marmara University, Istanbul, Turkey; ⁷Near East University Faculty of Denstry, Nicosia, North Cyprus

Received June 17, 2015; Accepted August 5, 2015; Epub August 15, 2015; Published August 30, 2015

Abstract: The aim of this study is to determine the effects of medical ozone preconditioning and treatment on the methotrexate acute induced hepatotoxicity in rats that has not reports elsewhere. Eighteen rats were randomly assigned into three equal groups; control, Mtx and Mtx with ozone. Hepatotoxicity was performed with a single dose of 20 mg/kg Mtx to group 2 and group 3 at the fifteenth day. The medical ozone preconditioning was administered intraperitoneally in group 3 for fifteen days and more five days after inducing Mtx. The other rats of the group 1 and 2 received saline injection. At the twentyfirst day the blood and the liver tissue samples were obtained to measure the levels of liver enzymes ALT and AST, proinflammatory cytokines TNF- α , IL-1 β , malondialdehyde, glutathione and myeloperoxidase. And the histopatological examination was evaluated for injury score. In our study Mtx administration caused a significant increase on the liver enzymes ALT and AST, the tissue MDA and MPO activity and significant decrease in the tissue GSH. Moreover the both pro-inflammatory cytokines were significantly increased in the Mtx group. Medical ozone preconditioning and treatment reversed all these biochemical parameters and histopathological changes of the hepatotoxicity induced by Mtx. We conclude that medical ozone ameliorates Mtx induced hepatotoxicity in rats.

Keywords: Methotrexate, liver, hepatotoxicity, medical ozone, preconditioning

Introduction

Methotrexate (mtx), analogue of folic acid is an effective cytotoxic chemotherapeutic drug and has been widely used in many malignancies [1, 2] and inflammatory diseases [3-6]. Long-term mtx use or its usage in high doses may cause hepatic steatosis, cholestasis, fibrosis and cirrhosis [7]. According to the hepatotoxicity due to mtx should be the reason for the delay in the treatment.

Medical Ozone is described as three atom molecules of oxygen known as O₃. Ozone is applied in medical therapy using a gas mixture composed of oxygen and ozone. Ozone therapy has been found useful in the treatment of various diseases including gastroduodenal ulcers, peritonitis, colitis and chronic skin ulcers [8-10].

Repeated ozone administration at nontoxic doses provide an adaptation of tissues to oxidative stress by induction of enzymes or activating the metabolic pathways maintaining an equilibrated redox balance such as increase on glutathione levels and decrease on lipid peroxidation [11]. Furthermore the effect of O₃ on Mtx induced hepatotoxicity has not been studied before. In this present study we aimed to evaluate whether O₃ preconditioning and treatment has any effects on Mtx-induced hepatotoxicity in rats.

Material and methods

Eighteen Wistar albino rats of male gender of 250-300 g were used in this study. The experimental procedures were reviewed and approved by Akdeniz University Local Committee on

Effect of ozone on methotrexate induced hepatotoxicity

Table 1. Ozone effect on biochemical parameters in the serum of control, Mtx, Mtx-Ozone groups. Each group was consisting of 6 rats. Groups of data were compared with an analysis of variance (ANOVA) followed by Tukey's multiple comparison tests

	Control	Mtx	Mtx-Ozone
TNF- α (pg/ml)	12.33 \pm 3.07	29.50 \pm 2.73**	18.16 \pm 2.04*.**
IL-1 β (pg/ml)	12.50 \pm 1.87	29.16 \pm 2.63**	17.16 \pm 1.16*.**
ALT (IU/L)	1.71 \pm 0.14	15.20 \pm 0.96**	3.56 \pm 0.59*.**
AST (IU/L)	2.55 \pm 0.28	18.08 \pm 1.61**	4.68 \pm 0.63*.**

Data are mean \pm SD. * P <0.01, ** P <0.001 compared to control group. ** P <0.001 compared to Mtx group.

Animal Research Ethics (2015.02.07). The rats maintained at a constant temperature (22°C) with a 12-h light-dark cycle and randomly divided into three equal groups. Group 1 was the control group receiving only physiological saline. Group 2 was the Methotrexate group receive a single 20 mg/kg dose of Mtx (Oncotain; Faulding Pharmaceuticals Plc, Leamington Spa, UK) intraperitoneally for induce hepatotoxicity at the end of fifteenth day and receiving 5 mL of saline intraperitoneally everyday for twenty days. Group 3 was the Methotrexate-medical ozone group preconditioned with 5 mL of medical ozone everyday for fifteen days and receiving a single dose of Mtx at the sixteenth day and also treated with 5 mL medical ozone (OM-302, Ozone generator, Sedecal, Spain) intraperitoneally everyday for more five days at dose of 25 mcg/mL. At the end of the twenty-first day the rats were sacrificed with decapitation after ether anesthesia and the blood samples and liver tissues were obtained. The levels of tumour necrosis factor-alpha (TNF- α) and interleukin-1-beta (IL-1 β) from blood and the levels of malondialdehyde (MDA), glutathione (GSH) and myeloperoxidase (MPO) from liver tissue samples were analysed. Histopathological analysis and the liver tissue injury score was performed by an expert pathologist under a light microscope.

Analysis of TNF- α and IL-1 β

TNF- α and IL-1 β from plasma were analysed by the enzyme-linked immunosorbent assay (ELISA) kits (Biosource International, Nivelles, Belgium).

Analysis of ALT and AST

The liver enzymes ALT and AST plasma concentrations were measured in accordance with the

diagnostic methods in samples obtained from all groups of rats serum. Activities were expressed as IU/L.

Measurement of malondialdehyde and glutathione levels

The liver tissue samples were homogenized in ice cold 150 mm KCl. The MDA levels (nmol MDA/g tissue) were assayed for the products of lipid peroxidation [12]. The GSH levels (nmol GSH/g tissue) were measured using the method of Elman [13]. GSH is reacted with 5,5-ithiobis-2-nitrobenzoic acid resulting in the formation of a product which has a maximal absorbance at 410 nm.

Measurement of myeloperoxidase activity

Measurement of the tissue-associated MPO (U MPO/g tissue) activity according to the Hillegas et al. [14] procedure. Liver tissue samples were homogenized in 50 mm potassium phosphate buffer (PB, pH 6.0) and homogenates were centrifuged at 41 400 g for 10 min; pellets were suspended in 50 mm PB containing 0.5% hexadecyltrimethylammonium bromide. After three cycles of freezing and thawing, with the sonication between the cycles, liver samples were centrifuged at 41 400 g for 10 min. Volumes of 0.3 ml were added to 2.3 ml of reaction mixture containing 50 mm PB, o-dianisidine, and 20 mm H₂O₂ solution. One unit of enzyme activity was defined as the amount of MPO that caused a change in the absorbance measured at 460 nm for 3 min.

Histopathological analysis

Liver specimens were fixed in 10% buffered formaldehyde. One horizontal section from each liver was embedded in paraffin, cut at 3 micrometers and stained with hematoxylin-eosin (H&E) and Periodic Acid-Schiff-diastase (D/PAS). Histopathological analysis was performed by an expert pathologist who was blinded to the experiment. For each tissue, semi-quantitative scales used in the liver were as follows; (1) vascular congestion, (2) degeneration and dilatation of the sinusoids, (3) hydropic degeneration (cellular swelling), (4) vacuolar degeneration of hepatocytes, (5) increase in the number of activated Kupffer cells, (6) portal inflammatory cell infiltration.

Effect of ozone on methotrexate induced hepatotoxicity

Table 2. The comparison of MDA, GSH and MPO levels in liver tissue of control, Mtx and Mtx-Ozone groups. Each group was consisting of 6 rats. Groups of data were compared with an analysis of variance (ANOVA) followed by Tukey's multiple comparison tests

	Control	Mtx	Mtx-Ozone
MDA (nmol/g tissue)	29.83±3.43	57.83±3.86***	30.83±3.71***
GSH (nmol/g tissue)	1816.00±113.72	1547.33±82.26*	1965.33±175.37*
MPO (U/g tissue)	23.66±2.16	45.33±2.06***	29.33±2.16 **.*

Data are mean ± SD. * $P < 0.01$, ** $P < 0.001$, *** $P < 0.0001$ compared to control group. * $P < 0.01$, ** $P < 0.001$, *** $P < 0.0001$ compared to Mtx group.

The whole microscopic area was examined to score each specimen. Tissue injury was scored using a scoring system. Scores were given as 0 = none, 1 = mild, 2 = moderate and 3 = severe. [15].

Statistical analysis

Statistical analysis was performed by GraphPad Prism 3.0 (GraphPad Software, San Diego, USA). The data were expressed as mean ± standard error of the mean (SEM). Group comparisons were performed with the analysis of variance (ANOVA) followed by Tukey's tests. The $P < 0.05$ was considered as statistically significant.

Results

In the Mtx group, proinflammatory cytokine TNF- α levels were found significantly increased 29.50±2.73 pg/mL ($P < 0.001$) when compared to control (12.33±3.07 pg/mL), while this Mtx-induced rise in serum TNF- α level was abolished 18.16±2.04 pg/mL ($P < 0.01$) with preconditioning with O₃. In the Mtx group when compared to control 12.50±1.87 pg/mL ($P < 0.001$) IL-1 β was also found as increased 29.16±2.63 pg/ml ($P < 0.001$). After preconditioning with O₃ following Mtx, IL-1 β was also decreased to 17.16±1.16 pg/ml ($P < 0.01$) (Table 1). The liver enzymes ALT and AST were also found as increased in Mtx group but both were diminished after O₃ preconditioning.

In accordance with these findings the mean level of MDA, which is a major degradation product of lipid peroxidation seen as increased in all tissues (57.83±3.86 nmol/g tissue) after Mtx administration when compared with the control group (29.83±3.43 nmol/g tissue) ($P < 0.001$), while preconditioning with O₃ to the Mtx group came back to control MDA levels

30.83±3.71 nmol/g tissue ($P < 0.001$, Table 2; Figure 1).

The major cellular antioxidant GSH levels of liver samples in Mtx group were found lower significantly (1547.33±82.26 nmol/g tissue) ($P < 0.01$). On the other hand, preconditioning with O₃ to Mtx group (1965.33±175.37 nmol/g tissue) restored the GSH levels to control levels (1816.00±113.72 nmol/g tissue) in all liver samples ($P < 0.01$, Table 2; Figure 1).

Indicator of neutrophil infiltration Myeloperoxidase has significantly higher activity in the liver samples of the Mtx group (45.33±2.06 U/g tissue) when compared to control (23.66±2.16 U/g tissue) ($P < 0.0001$). On the other hand, preconditioning with O₃ in Mtx group significantly decreased all MPO activity level (29.33±2.16 U/g tissue) ($P < 0.001$, Table 2; Figure 1).

Histopathological evaluation and average degree of injury scores of the groups in medi-ans were shown in Table 3. Liver sections from the control group were normal in histological appearance. The liver sections from the Mtx group showed some histopathological changes such as inflammation around portal vein and lymphoplasmacytic inflammation (Figure 2). Ozone preconditioning reduced the histopathological damage score in the Mtx+O₃ group in comparison to the control and Mtx groups. In this group, liver sections showed perivenular sinusoidal dilatation (Figure 3).

Discussion

According to literature search, this is the first study investigating the effect of preconditioning and treatment of medical ozone on experimental Mtx-induced hepatotoxicity in rats. Findings from our study revealed that liver injury ameliorated by intraperitoneal medical ozone administration, while with antioxidant effect the ozone prevented the lipid peroxidation and neutrophil infiltration of the rat liver tissues. The decreasing on tissue MDA levels and MPO activities with an increasing on levels of GSH revealed that ozone preconditioning prevented

Effect of ozone on methotrexate induced hepatotoxicity

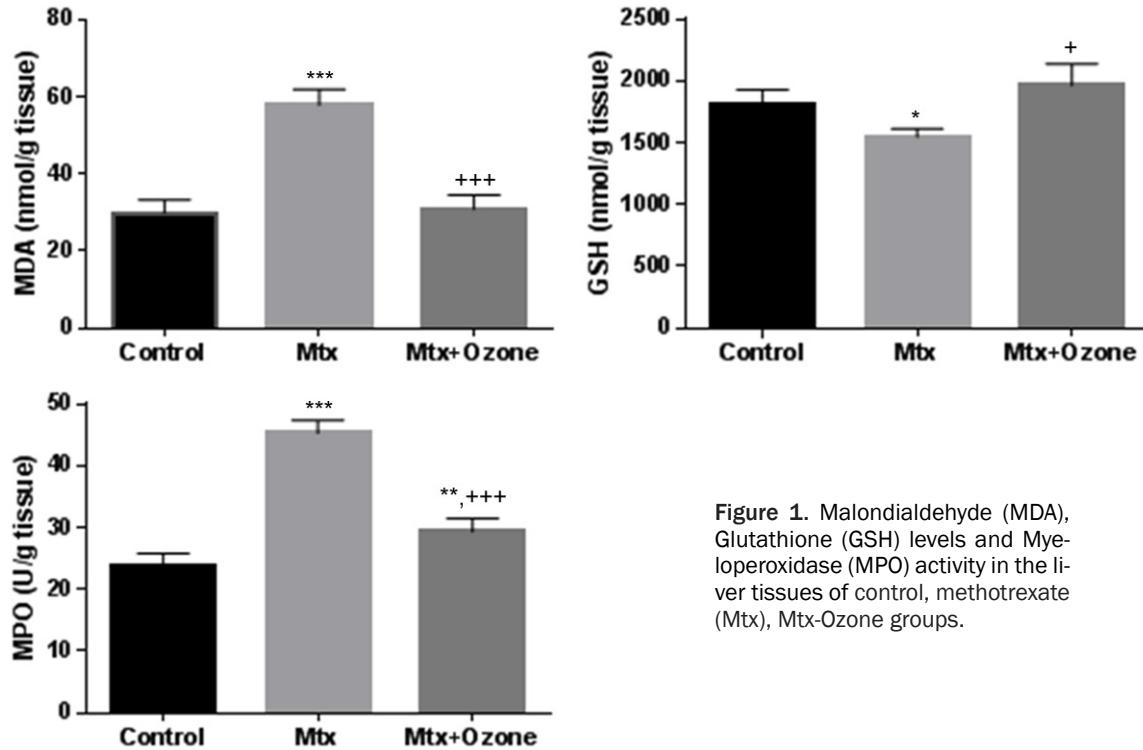


Figure 1. Malondialdehyde (MDA), Glutathione (GSH) levels and Myeloperoxidase (MPO) activity in the liver tissues of control, methotrexate (Mtx), Mtx-Ozone groups.

Table 3. The average degree of histopathologic damage was expressed as medians within each liver section of groups were shown

Parameters	Control	Mtx	Mtx-Ozone
Vascular congestion	0	2	1
Degeneration and dilatation of the sinusoids	0	2	2
Hydropic degeneration (cellular swelling)	0	2	1
Vacuolar degeneration of hepatocytes	0	2	1
Increase in the number of activated Kupffer cells	0	2	1
Portal inflammatory cell infiltration	0	3	2
Total score	0	13	8

liver tissue from oxidative stress. Also ozone preconditioning was significantly improved the changes on liver tissue caused by mtz in rats by decreasing the plasma cytokines and liver enzymes ALT and AST.

Methotrexate is an antimetabolite that competitively inhibits the folic acid metabolism thus impairs the DNA synthesis. 7-hydroxymethotrexate is the major extracellular metabolite of Mtx that is metabolized in the liver by an enzymatic system [7]. With the use of Mtx intracellular amount of polyglutamate increases on the other hand folic acid levels decreased that leads to necrosis of hepatocyte [16]. Hepatotoxic effect of mtz was caused by an

increase of its polyglutamate form intracellularly. The hepatotoxic effects of mtz have been reported in many studies [1, 17, 18].

Ozone preconditioning was investigated in many studies on animal models of hepatotoxicity and according to these findings showed ozone as able to induce an adaptation to oxidative stress and promote oxidative preconditioning through the increase and preservation of antioxidant endogenous systems which can be induced by CCl₄. It also can produce protection against hepatic and renal ischemia reperfusion injury [19-21]. In a recent study, ozone investigated to provide a protective effect against radiation-induced oxidative damage in the liver [22]. A controlled number and dose of ozone treatments conferred protection against different physiopathological processes mediated by ROS was reported [19].

Ozone preconditioning prevented and thus decreased the serum ALT and AST enzyme activities which are the liver injury indicators induced by Mtx administration. On the other hand, ozone probably prevented liver necrosis

Effect of ozone on methotrexate induced hepatotoxicity

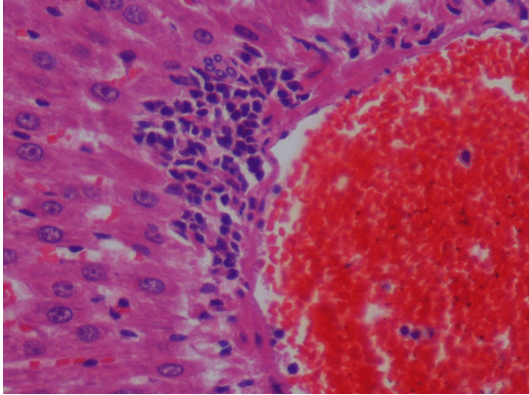


Figure 2. Mtx group; Portal inflammation. Lymphoplasmacytic inflammation and a small biliary ductule is seen in the inset (X10, H/E, inset: X40, H/E).

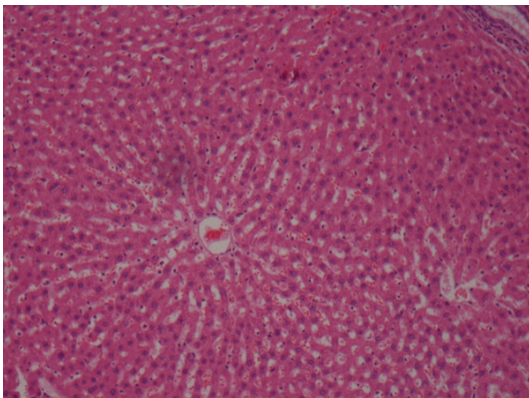


Figure 3. Mtx+O₃ group; In this picture, perivenular (Zone III) area shows sinusoidal dilatation. Liver has the appearance of a nutmeg. Compare sinusoids with the upper right. (X10, H/E).

by modulating the antioxidant defense system, improving oxygen delivery and increasing the release of vascular nitric oxide [23]. In a previous study it was reported that ozone exposure altered the levels of inflammatory cytokines, such as tumor necrosis factor [24], transforming growth factor [25], interferon [26] and interleukin [27]. In our study systemic inflammatory response indicators; plasma TNF- α and IL-1 β levels were also found increased due to mtx administration but decreased by ozone preconditioning.

Lipid peroxidation by free oxygen radicals is an important cause of destruction and oxidative damage to cell membranes these containing unsaturated fatty acids, nucleic acids and proteins. It can result with methotrexate induced tissue damage [7, 12, 18, 28]. The decreasing on tissue MDA levels revealed that ozone pre-

conditioning prevented liver tissue from oxidative damage.

At previous studies reported that stimulation of antioxidant enzyme activities such as glutathione by ozone prepared the tissue against the reactive oxygen species effects [29, 30]. GSH plays a particularly important role in the maintenance and regulation of the thiol-redox status of the cell [31]. Tissue GSH depletion is one of the primary factors permitting liver tissue damage is associated with oxidative stress caused by mtx in our study. O₃ was previously reported to increase glutathione levels in erythrocytes and it may show the same action in hepatocytes, thus increasing the detoxification capacity of these cells [32]. In our study preconditioning with ozone reversed the levels of GSH into normal levels.

It was expected that free oxygen radicals plays an important role in mtx induced liver toxicity [33, 34]. It triggers the leukocytes accumulation in tissue and activates neutrophils to secrete enzymes. And this leads to further tissue damage. Therefore, this MPO an enzyme secreted by neutrophils plays role in oxidant production [35, 36]. In our study MPO activity which is an index of polymorphonuclear leukocyte infiltration and accumulation was found increased. Increased activities of MPO indicate that contributes to Mtx induced oxidative liver injury in rats. Intraperitoneal ozone preconditioning decreased the MPO activity.

In our study as a result preconditioning with intraperitoneal ozone was significantly reduced the liver enzymes ALT and AST, plasma TNF- α and IL-1 β levels, MDA levels and MPO activity, increase the GSH levels while histological changes was observed decreased in liver tissue.

Conclusion

In conclusion, preconditioning and treatment with O₃ intraperitoneally ameliorate the liver injury induced by methotrexate in rats.

Acknowledgements

We acknowledge to Dr. Başar ŞENYÜZ from Ozonklinik for ozone supply.

Disclosure of conflict of interest

None.

Effect of ozone on methotrexate induced hepatotoxicity

Address correspondence to: Dr. Arif Aslaner, Department of General Surgery, Antalya Training and Research Hospital, Varlık Mahallesi, Kazım Karabekir Caddesi Soğuksu, Antalya 07100, Turkey. Tel: +90 242 2494400-3387, +90 531 4309987; Fax: +90242 2494462; E-mail: arifaslaner@gmail.com

References

- [1] Bleyer WA. Methotrexate: clinical pharmacology, current status and therapeutic guidelines. *Cancer Treat Rev* 1977; 4: 87-101.
- [2] Widemann BC, Balis FM, Kempf-Bielack B, Bielack S, Pratt CB, Ferrari S, Bacci G, Craft AW, Adamson PC. High-dose methotrexate-induced nephrotoxicity in patients with osteosarcoma. *Cancer* 2004; 100: 2222-32.
- [3] Braun J, Rau R. An update on methotrexate. *Curr Opin Rheumatol* 2009; 21: 216-23.
- [4] Kose E, Sapmaz HI, Sarihan E, Vardi N, Turkoz Y, Ekinci N. Beneficial effects of montelukast against methotrexate-induced liver toxicity: a biochemical and histological study. *Scientific World Journal* 2012; 2012: 987508.
- [5] Soliman ME. Evaluation of the possible protective role of folic acid on the liver toxicity induced experimentally by methotrexate in adult male albino rats. *Egypt J Histol* 2009; 32: 118-28.
- [6] Dalaklioglu S, Genc GE, Aksoy NH, Akcıt F, Gumuslu S. Resveratrol ameliorates methotrexate-induced hepatotoxicity in rats via inhibition of lipid peroxidation. *Hum Exp Toxicol* 2013; 32: 662-71.
- [7] Chládek J, Martínková J, Sispera L. An in vitro study on methotrexate hydroxylation in rat and human liver. *Physiol Res* 1997; 46: 371-9.
- [8] Bulynin VI, Glukhov AA. Treatment of peritonitis using ozone and hydropressive technology. *Khirurgiia (Mosk)* 1999; 7: 9-11.
- [9] Zamora Z, González R, Guanche D, Merino N, Menéndez S, Hernández F, Alonso Y, Schulz S. Ozonized sunflower oil reduces oxidative damage induced by indomethacin in rat gastric mucosa. *Inflamm Res* 2008; 57: 39-43.
- [10] Knoch HG, Klug W. Ozone-oxygen therapy in proctology. *Ter Arkh* 1990; 62: 93-8.
- [11] Leon OS, Menendez S, Merino N, Castillo R, Sam S, Perez L, Cruz E, Bocci V. Ozone oxidative preconditioning: a protection against cellular damage by free radicals. *Mediators Inflamm* 1998; 7: 289-94.
- [12] Buege JA, Aust SD. Microsomal lipid peroxidation. *Methods Enzymol* 1978; 52: 302-10.
- [13] Beutler E. Glutathione in Red Blood Cell Metabolism. *A Manual of Biochemical Methods*. New York: Grune & Stratton; 1975. pp. 112-4.
- [14] Hillegass LM, Griswold DE, Brickson B, Albrightson-Winslow C. Assessment of myeloperoxidase activity in whole rat kidney. *J Pharmacol Methods* 1990; 24: 285-95.
- [15] Gul M, Kayhan B, Elbe H, Dogan Z, Otlu A. Histological and biochemical effects of dexmedetomidine on liver during an inflammatory bowel disease. *Ultrastruct Pathol* 2015; 39: 6-12.
- [16] Kamen BA, Nysten PA, Camitta BM, Bertino JR. Methotrexate accumulation and folate depletion in cells as a possible mechanism of chronic toxicity to the drug. *Br J Haematol* 1981; 49: 355-60.
- [17] Sener G, Ekşioğlu-Demiralp E, Cetiner M, Ercan F, Yeğen BC. Beta-glucan ameliorates methotrexate-induced oxidative organ injury via its antioxidant and immunomodulatory effects. *Eur J Pharmacol* 2006; 542: 170-8.
- [18] Uz E, Oktem F, Yilmaz HR, Uzar E, Özgüner F. The activities of purine-catabolizing enzymes and the level of nitric oxide in rat kidneys subjected to methotrexate: protective effect of caffeic acid phenethyl ester. *Mol Cell Biochem* 2005; 277: 165-70.
- [19] León OS, Menéndez S, Merino N, Castillo R, Sam S, Pérez L, Cruz E, Bocci V. Ozone oxidative preconditioning: a protection against cellular damage by free radicals. *Mediators Inflamm* 1998; 7: 289-94.
- [20] Chen H, Xing B, Liu X, Zhan B, Zhou J, Zhu H, Chen Z. Similarities between ozone oxidative preconditioning and ischemic preconditioning in renal ischemia/reperfusion injury. *Arch Med Res* 2008; 39: 169-78.
- [21] Ajamieh H, Merino N, Candelario-Jalil E, Menéndez S, Martinez-Sanchez G, Re L, Giuliani A, Leon OS. Similar protective effect of ischaemic and ozone oxidative reconditionings in liver ischaemia/reperfusion injury. *Pharmacol Res* 2002; 45: 333-9.
- [22] Gultekin FA, Bakkal BH, Guven B, Tasdoven I, Bektas S, Can M, Comert M. Effects of ozone oxidative preconditioning on radiation-induced organ damage in rats. *J Radiat Res* 2013; 54: 36-44.
- [23] Bocci VA. Scientific and medical aspects of ozone therapy. State of the art. *Arch Med Res* 2006; 37: 425-35.
- [24] Paulesu L, Luzzi E, Bocci V. Studies on the biological effects of ozone: 2. Induction of tumor necrosis factor (TNF-alpha) on human leukocytes. *Lymphokine Cytokine Res* 1991; 10: 409-12.
- [25] Bocci V. A reasonable Approach for the Treatment of HIV Infection in the Early Phase with Ozonotherapy (Autohaemotherapy). How 'Inflammatory' Cytokines may have A therapeutic Role. *Mediators Inflamm* 1994; 3: 315-21.
- [26] Bocci V, Paulesu L. Studies on the biological effects of ozone 1. Induction of interferon gamma

Effect of ozone on methotrexate induced hepatotoxicity

- ma on human leucocytes. *Haematologica* 1990; 75: 510-5.
- [27] Bocci V, Valacchi G, Corradeschi F, Fanetti G. Studies on the biological effects of ozone: 8. Effects on the total antioxidant status and on interleukin-8 production. *Mediators Inflamm* 1998; 7: 313-7.
- [28] Bludovská M, Kotyzová D, Koutenský J, Eybl V. The influence of alpha-lipoic acid on the toxicity of cadmium. *Gen Physiol Biophys* 1999; 18: 28-32.
- [29] Bocci V. Is it true that ozone is always toxic? The end of a dogma. *Toxicol Appl Pharmacol* 2006; 216: 493-504.
- [30] Bocci V. Does ozone therapy normalize the cellular redox balance? Implications for therapy of human immunodeficiency virus infection and several other diseases. *Med Hypotheses* 1996; 46: 150-4.
- [31] Ballatori N, Krance SM, Notenboom S, Shi S, Tieu K, Hammond CL. Glutathione dysregulation and the etiology and progression of human diseases. *Biol Chem* 2009; 390: 191-214.
- [32] Bocci V, Luzzi E, Corradeschi F, Paulesu L, Rossi R, Cardaioli E, Di Simplicio P. Studies on the biological effects of ozone: 4. Cytokine production and glutathione levels in human erythrocytes. *J Biol Regul Homeost Agents* 1993; 7: 133-8.
- [33] Jahovic N, Cevik H, Sehirli AO, Yeğen BC, Sener G. Melatonin prevents methotrexate-induced hepatorenal oxidative injury in rats. *J Pineal Res* 2003; 34: 282-7.
- [34] Jahovic N, Sener G, Cevik H, Ersoy Y, Arbak S, Yeğen BC. Amelioration of methotrexate-induced enteritis by melatonin in rats. *Cell Biochem Funct* 2004; 22: 169-78.
- [35] Donnahoo KK, Meng X, Ayala A, Cain MP, Harken AH, Meldrum DR. Early kidney TNF-alpha expression mediates neutrophil infiltration and injury after renal ischemia-reperfusion. *Am J Physiol* 1999; 277: 922-9.
- [36] Winterbourn CC, Vissers MC, Kettle AJ. Myeloperoxidase. *Curr Opin Hematol* 2000; 7: 53-8.