

## Original Article

# Comparison of two different circular-stapler techniques for creation of gastrojejunostomy anastomosis in bariatric Roux-en Y gastric bypass

Ilhan Ece, Huseyin Yilmaz, Husnu Alptekin, Serdar Yormaz, Bayram Colak, Mustafa Sahin

Department of Surgery, Faculty of Medicine, Selcuk University, Konya 42075, Turkey

Received May 25, 2015; Accepted July 12, 2015; Epub July 15, 2015; Published July 30, 2015

**Abstract:** *Background:* Circular-stapled anastomosis with trans-oral anvil insertion is one of the most commonly used methods for the creation of the gastrojejunostomy in laparoscopic Roux-en-Y gastric bypass (LRYGB). We present a retrospective analysis of laparoscopic gastric bypass by comparing 2 techniques of circular-stapled gastrojejunostomy; Orvil™ and hand-made Orvil. *Methods:* Patients who were subjected to LRYGB without any concomitant procedures were observed over a 13-months period at the “Obesity clinic of a University”. A total of 94 patients with morbid obesity were subjected to LRYGB. Gastrojejunostomy with circular-stapler and Orvil™ (CS-O) was performed to 58 patients and 36 patients underwent through the surgery with circular-stapler and hand-made Orvil (CS-HMO). Demographics, clinic, intraoperative data, postoperative complications, and the length of hospital stay were evaluated. *Results:* Ninety-four patients with mean age of 37.2 years and average body mass index of 58.1 kg/m<sup>2</sup> underwent laparoscopic Roux-en-Y gastric bypass. Laparoscopic surgeries of all patients were successful and major intraoperative complications were not reported. Demographic data and complication rates were similar in both groups. The operative time in group CS-HMO was significantly higher ( $P=0.03$ ) when compared to group CS-O. There was no anastomotic leak in both groups. *Conclusion:* The use of hand-made Orvil is a technically feasible and safe method for performing the gastrojejunostomy. This technique can be successfully used in case of difficulties for obtaining the Orvil™ or reducing the operational costs.

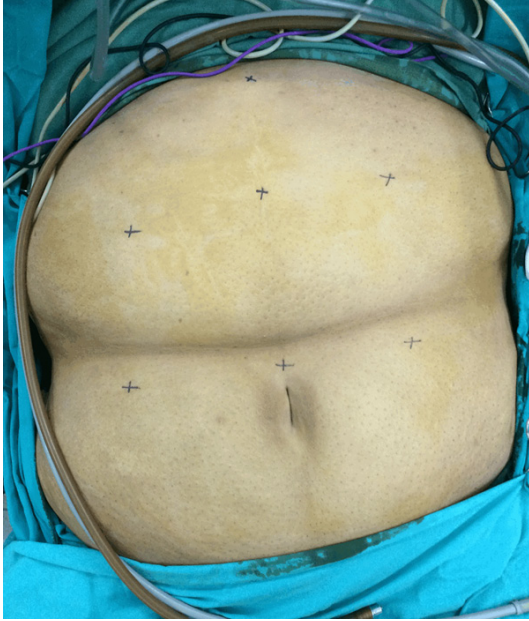
**Keywords:** Orvil, gastrojejunostomy, laparoscopic gastric bypass, morbid obesity

## Introduction

Laparoscopic gastric bypass (LRYGB) was first described by Wittgrove et al [1]. In the original technique, a 21-mm circular-stapler was used with the anvil placed transorally. A guide wire was used to pull and position the anvil in the gastric pouch. The major difficulty in the transoral technique is passage of the round anvil through the upper esophageal sphincter. Correspondingly, hypopharyngeal injury due to the transoral placement of the anvil has been reported [2]. Therefore, most bariatric surgeons transferred to the transabdominal technique for placement of the anvil due to the technical difficulties of the transoral method [3]. In this technique, the 21-mm circular-stapler anvil is placed transabdominally through a port site, passes through a gastrostomy on the lateral aspect of the gastric pouch, and positions on

the posterior gastric wall. Then, the gastrostomy is closed with a linear-stapler. Due to the difficulties for manipulation of anvil in the abdomen, linear-stapled gastrojejunostomy (GJ) was recognized [4]. However, the use of the linear-stapler may be technically difficult for small gastric pouch in reoperative bariatric surgical procedures. Recently, a pre-tilted anvil (Orvil, Covidien, Mansfield, MA, USA) was manufactured for the purpose of transoral delivery. In recent years, esophagojejunostomy and gastrojejunostomy has been performed successfully with Orvil™ [5-7]. The additional costs resulted from Orvil™ can be a problem in some countries. Therefore, in our clinic we are using the hand-made Orvil technique to decrease the costs.

The aim of the present study was to evaluate our two operative techniques; circular stapled



**Figure 1.** Trocar placement for LRYGB.

GJ with Orvil™ and manually tilted head of the anvil (hand-made Orvil).

### Materials and methods

Between April 2013 and May 2014, 94 patients underwent LRYGB consecutively for morbid obesity. For fifty-eight patients, GJ was performed by 25-mm circular-stapler and Orvil™ (CS-O), and 36 operations were performed by 25-mm circular-stapler and hand-made Orvil (CS-HMO). After institutional review board approval and obtaining written informed consent of the patient follow-up data of patients was obtained from hospital charts and office records. Patients with previous bariatric procedures and conversions to laparotomy were excluded. The data included age, gender, body mass index (BMI), American Society of Anesthesiologists (ASA) classification, operative time, co-morbidities, length of hospital stay, operative complications, and short-term outcomes was evaluated.

### Operative technique

We performed all LRYGBs by using a seven-trocar technique after preoperative antibiotic (Cefazoline 2 g iv) and thromboembolism (LMWH) prophylaxis. Pneumoperitoneum was established by insertion of first supra-umbilical 10-mm trocar after lifting the abdominal wall

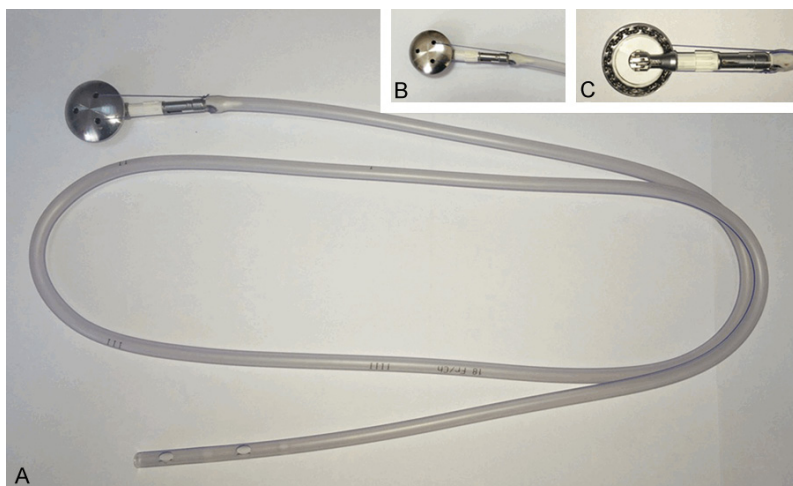
with towel clamps, and a second 10-mm trocar was inserted 10 cm above laparoscope trocar for clear visualization of gastric pouch. Two 12-mm trocars were placed in the right and left region of the epigastrium and a 5-mm trocar was placed in the subxiphoid area for the liver retractor. Additional two 10-mm trocars were inserted from the 15-cm right and left side of the umbilicus to facilitate the jejunojunction anastomosis. Trocar placement can be seen in the **Figure 1**. The greater omentum was routinely divided from the middle of the transverse colon to the stomach in order to lessen the tension in the GJ. The gastric pouch was constructed using 2 Endo GIA™ staplers (Covidien, Mansfield, MA, USA).

In the hand-made Orvil technique, a 25-mm circular-stapler (Covidien, Autosuture, Mansfield, MA, USA) anvil was used to prepare the Orvil. The head of anvil was manually tilted to facilitate the passage through the upper esophageal sphincter. The tilted anvil was sutured to the end of a nasogastric tube; thus, the orvil was created (**Figure 2**). The gastric pouch was punctured with electrocautery (**Figure 3A**), and the oral gastric tube was laparoscopically withdrawn from the gastric pouch (**Figure 3B**). Afterwards, the anvil was pulled transorally and positioned within the gastric pouch. During the passage, it is important for the anesthesiologist to ensure the deflation of the endotracheal tube balloon for facilitating the passage of anvil. The suture attaching the anvil to the orogastric tube was cut and the tube was disconnected (**Figure 3C, 3D**). A circular-stapler was inserted from the right epigastrum trocar place; then the spike was connected to the anvil to create a GJ anastomosis. The tilted anvil head was automatically tilted back into the flat position when the circular-stapler was attached to the anvil, and the GJ was performed. The stump of distal jejunum was intracorporeally sutured by Endo-GIA.

In the Orvil technique, the same procedure was followed except for the preparation of hand-made Orvil.

### Statistical analysis

Data collection was performed on Microsoft Excel 2007 (Microsoft, Redmond, WA, USA) and statistical analysis was performed using SPSS 16.0 (SPSS Inc., Chicago, IL, USA).



**Figure 2.** Creation of handmade orvil (A), front (B), and rear (C) view.

patient's neck were applied in all patients, and this application facilitated the passage of the anvil through the esophageal sphincter. The stricture rate was 5.1% in the CS-O group while it was 5.5% in the CS-HMO group. The strictures were identified an average of 32 days (range, 21 to 63) after the surgical operation. One of these patients required dilatation only once. Each of the remaining patients needed between 2 to 3 dilatations.

### Discussion

Demographic data and perioperative data were compared using Student's test for continuous variables, and univariate analysis was conducted using Fisher's exact test for categorical data. All values were given as mean  $\pm$  SD. The value  $P < 0.05$  was considered to be significant.

### Results

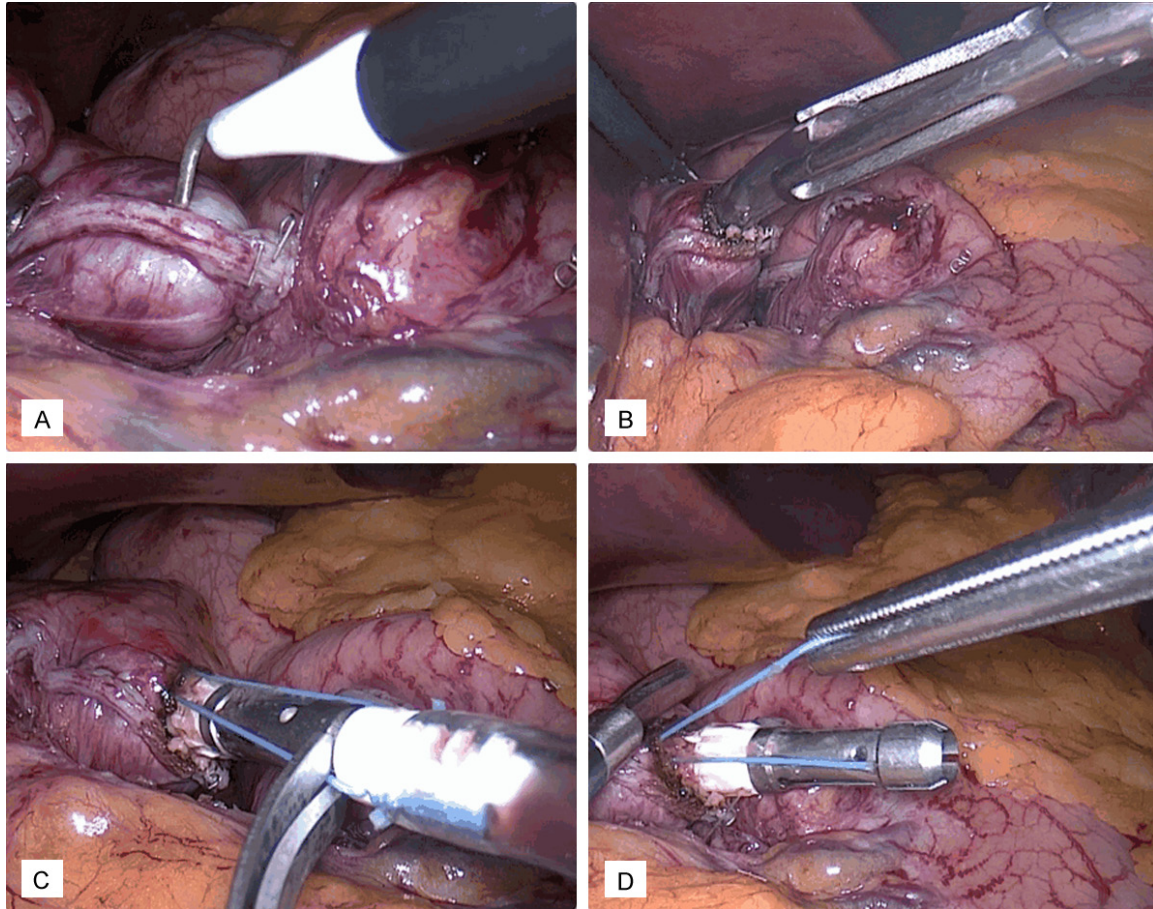
In this study, 71 women and 23 men with a mean age of 37 years (range, 28-59 years) were subjected to LRYGB. The mean body mass index was 58.1 kg/m<sup>2</sup> (range 48-75 kg/m<sup>2</sup>). The patients in this study had also significant co-morbidities with an ASA class of 3 (range, 2-4).

The mean estimated blood loss was 90 ml (range, 20-200 ml), and operative time was 116 min (range, 80-225 min). The patients discharged from the hospital after an average of 7 days. (range, 5-13 days). There were no incisional hernias, anastomotic leaks, or deaths in a mean of 9 months follow-up period.

There were 36 patients in the CS-HMO group and 58 patients in the CS-O group. There were no statistically significant differences between the two groups with regarding to age, gender ratio, ASA class, BMI, additional diseases (**Table 1**), estimated blood loss, and postoperative complications (**Table 2**). The operative times were 107 $\pm$ 24 and 135 $\pm$ 22 minutes in CS-O and CS-HMO groups respectively ( $P < 0.05$ ). The practice of deflation of the cuff of the endotracheal tube and extension of the

Morbid obesity has become a common epidemic in developed countries and has been slowly spreading to the entire world. Over the last decade, laparoscopic approach to the surgical treatment of morbid obesity has been developed and increasingly accepted. The LRYGB is one of the most frequently performed procedure for the treatment of morbid obesity. Laparoscopic gastric bypass can provide the loss of excessive weight approximately about 80% by the first year, and over 95% of the significant preoperative comorbidities can be controlled [8]. However, it is a technically challenging operation. Since Wittgrove et al. introduced the first laparoscopic gastric bypass, many variations of the original technique have been reported [1, 9-11]. The most recognized techniques among the technical variations in the LRYGB are the GJ techniques including the circular-stapled anastomosis, linear-stapled anastomosis, and hand-sewn anastomosis. In the original technique, a 21-mm circular-stapler was used, and the anvil was placed trans-orally. A guide wire was attached to the tip of the anvil, and the anvil was pulled trans-orally and positioned within the gastric pouch. The major difficulty in the trans-oral technique was the passage of the mushroom-like shaped anvil head through the oropharynx. Esophageal or hypopharyngeal injury with the trans-oral placement of the anvil was one of the most important problems. Nguyen and Scott was reported esophageal injury which occurred during the transoral anvil placement technique [2, 12]. Multiple mechanical maneuvers have been

## Gastrojejunostomy anastomosis in bariatric Roux-en Y gastric bypass



**Figure 3.** The gastric pouch was punctured with electrocautery (A), and the oral gastric tube was laparoscopically withdrawn from the gastric pouch (B). The anvil was positioned within the gastric pouch. The suture attaching the anvil to the orogastric tube was cut (C) and the tube was disconnected (D).

**Table 1.** Characteristics and complicated diseases of the patients

	CS-O n=58	CS-HMO n=36	<i>p</i> value
Age (years)	38.1±10.5	35.8±9.8	0.434
Gender (M/F)	14/44	9/27	0.726
ASA	3	3	0.330
BMI (kg/m <sup>2</sup> )	58.8±7.4	56.2±9.2	0.373
Hypertension (n, %)	8, 13.7	6, 16.6	0.290
Coronary artery disease (n, %)	1, 1.7	0, 0	0.061
Type 2 diabetes (n, %)	13, 22.4	10, 27.7	0.286
Glucose tolerance (n, %)	5, 8.6	2, 5.5	0.353
Impairment (n, %)			
Dyslipidemia	16, 27.5	11, 30.5	0.301
Sleep apnea syndrome	8, 13.7	4, 11.1	0.442
Degenerative joint disease	6, 10.3	4, 11.1	0.605

ASA: American Society of Anesthesiology Class; BMI: Body mass index; CS-O: Circular stapler-Orvil™; CS-HMO: Circular stapler-Hand made orvil.

used to facilitate the transoral delivery of the anvil. However, technical difficulties and risk of esophageal injury could not be eliminated. Gagner and colleagues mechanically tilted the head of the anvil and attached it to an oral gastric tube. In so doing, anvil geometry has allowed the passage with a minimal risk of esophageal injury. However, this technique has the disadvantage that the head of the anvil cannot be tilted back into the flat position while tightening the stapler. In 2 of patients in our study, the anvil was tilted back with the assistance of an additional endograsper. The anvil is now available pre-tilted and attached to an orogastric tube and named as Orvil™ by the manufacturer. The Orvil™ can be used for a variety of gastric anastomosis and provides a reliable and reproducible anastomosis in technically challenging situations. Jeong et al. performed

## Gastrojejunostomy anastomosis in bariatric Roux-en Y gastric bypass

**Table 2.** Operative data and complications

	CS-O	CS-HMO	<i>p value</i>
	n=58	n=36	
Blood loss (ml)	92±42	88±52	0.642
Operative time (min)	107±24	135±22	0.034
Complications (n, %)	10, 17.5	7, 19.4	
-Bleeding	3	2	0.361
-Stricture	3	2	0.361
-Leak	0	0	-
-Wound infection	5	4	0.194

CS-O: Circular stapler-Orvil™, CS-HMO: Circular stapler-Hand made orvil.

16 esophagojejunostomies using Orvil™ and circular-stapler [13]. An intra-abdominal abscess has developed in only 1 patient. In the study of Chong-Wei et al, Orvil™ was used successfully in 34 patients without any major complications [14]. Takata et al. concluded that the use of a 21-mm CS was the only independent predictor of a gastrojejunostomy stricture in 379 patients who underwent Roux-en-Y gastric bypass [15]. Therefore, we have used 25-mm circular-stapled anastomosis in all patients. In our study, anastomotic stricture developed in 5 of 94 patients (5.31%) in a manner consistent with the literature [16, 17], and all were treated conservatively. Some authors have reported an increased frequency of wound infection with CS related to the extraction of the contaminated hand piece through a port site [18, 19]. In our study, 9 patients had wound infection at the port site, and all were treated with drainage and antibiotics.

The insertion of the Orvil™ requires the cooperation of an experienced anesthesiologist who is conversant with esophageal anatomy. The passage of the anvil through the esophagus should be facilitated with the help of the laryngoscope by lifting the back of the neck and deflating the cuff of the endotracheal tube. If the anvil sticks to the esophagus, force should not be used to prevent the damage to the esophageal mucosa. In this cases, esophagoscopy observation may be helpful for the passage of the anvil.

The incidence of GJ leak, hospital stay, and post-operative bleeding did not show any significant difference between the groups. The time taken to prepare Orvil prolonged the operative time. This was the only drawback of CS-HMO technique. However, prolonged opera-

tive time did not cause any additional complications in patients.

### Conclusions

It is known that, the transoral placement of an Orvil™ is technically feasible and safe for passage through the oropharynx and esophagus. We have successfully performed LRYGB using CS-HMO technique with acceptable surgical outcomes. We believe that this method is especially useful to reduce costs when the Orvil™ cannot be provided.

### Disclosure of conflict of interest

None.

**Address correspondence to:** İlhan Ece, Department of Surgery, Faculty of Medicine, Selcuk University, Konya 42075, Turkey. Tel: +903322415000-44713; Fax: +903322412184; E-mail: ilhanece@yahoo.com

### References

- [1] Wittgrove AC, Clark W, Tremblay LJ. Laparoscopic gastric bypass, Roux en Y: preliminary report of five cases. *Obes Surg* 1994; 4: 353-357.
- [2] Nguyen NT, Wolfe BM. Hypopharyngeal perforation during laparoscopic Roux-en-Y gastric bypass. *Obes Surg* 2000; 10: 64-7.
- [3] Teixeira JA, Borao FJ, Thomas TA, Cerabona T, Artuso D. An alternative technique for creating the gastrojejunostomy in laparoscopic Roux-en-Y gastric bypass: experience with 28 consecutive patients. *Obes Surg* 2000; 10: 240-4.
- [4] DeMaria EJ, Sugerman HJ, Kellum JM, Meador JG, Wolfe LG. Results of 281 consecutive total laparoscopic Roux-en-Y gastric bypasses to treat morbid obesity. *Ann Surg* 2002; 235: 640-7.
- [5] Xie JW, Huang CM, Zheng CH, Li P, Wang JB, Lin JX, Jun L. A safe anastomotic technique of using the transorally inserted anvil (Orvil) in Roux-en-Y reconstruction after laparoscopy-assisted total gastrectomy for proximal malignant tumors of the stomach. *World J Surg Oncol* 2013; 11: 256.
- [6] Nguyen NT, Hinojosa MW, Smith BR, Reavis KM, Wilson SE. Advances in circular stapling technique for gastric bypass: transoral placement of the anvil. *Obes Surg* 2008; 18: 611-4.
- [7] LaFemina J, Viñuela EF, Schattner MA, Gerdes H, Strong VE. Esophagojejunal reconstruction after total gastrectomy for gastric cancer using a transorally inserted anvil delivery system. *Ann Surg Oncol* 2013; 20: 2975-83.

## Gastrojejunostomy anastomosis in bariatric Roux-en Y gastric bypass

- [8] Wittgrove AC, Clark GW. Laparoscopic gastric bypass, Roux-en-Y- 500 patients: technique and results, with 3-60 month follow-up. *Obes Surg* 2000; 10: 233-9.
- [9] Wittgrove AC, Clark GW. Laparoscopic gastric bypass: Technique and results in 75 cases with 3-30 months follow-up. *Obes Surg* 1996; 6: 500-4.
- [10] Liu CD, Glantz GJ, Livingston EH. Fibrin glue as a sealant for high-risk anastomosis in surgery for morbid obesity. *Obes Surg* 2003; 13: 45-8.
- [11] Shikora SA, Kim JJ, Tarnoff ME. Reinforcing gastric staple-lines with bovine pericardial strips may decrease the likelihood of gastric leak after laparoscopic Roux-en-Y gastric bypass. *Obes Surg* 2003; 13: 37-44.
- [12] Scott DJ, Provost DA, Jones DB. Laparoscopic Roux-en-Y gastric bypass: transoral or transgastric anvil placement? *Obes Surg* 2000; 10: 361-5.
- [13] Jeong O, Park YK. Intracorporeal circular stapling esophagojejunostomy using the transorally inserted anvil (OrVil) after laparoscopic total gastrectomy. *Surg Endosc* 2009; 23: 2624-30.
- [14] Chong-Wei K, Dan-Lei C, Dan D. A modified technique for esophagojejunostomy or esophagogastrostomy after laparoscopic gastrectomy. *Surg Laparosc Endosc Percutan Tech* 2013; 23: e109-15.
- [15] Takata MC, Ciovica R, Cello JP, Posselt AM, Rogers SJ, Campos GM. Predictors, treatment, and outcomes of gastrojejunostomy stricture after gastric bypass for morbid obesity. *Obes Surg* 2007; 17: 878-84.
- [16] Ibele AR, Bendewald FP, Mattar SG, McKenna DT. Incidence of Gastrojejunostomy Stricture in Laparoscopic Roux-en-Y Gastric Bypass Using an Autologous Fibrin Sealant. *Obes Surg* 2014; 24: 1052-6.
- [17] Giordano S, Salminen P, Biancari F, Victorzon M. Linear stapler technique may be safer than circular in gastrojejunal anastomosis for laparoscopic Roux-en-Y gastric bypass: a meta-analysis of comparative studies. *Obes Surg* 2011; 21: 1958-1964.
- [18] Abdel-Galil E, Sabry AA. Laparoscopic Roux-en-Y gastric bypass evaluation of three different techniques. *Obes Surg* 2002; 12: 639-642.
- [19] Shope TR, Cooney RN, McLeod J, Miller CA, Haluck RS. Early results after laparoscopic gastric bypass: EEA vs GIA stapled gastrojejunal anastomosis. *Obes Surg* 2003; 13: 355-9.