

## Case Report

# Left renal vein transposition is effective for posterior nutcracker syndrome

Yuedong Chen, Jinchun Xing, Fei Liu

Department of Urology and Center of Urology, The First Hospital Affiliated to Xiamen University, Xiamen 361003, P. R. China

Received August 29, 2014; Accepted October 23, 2014; Epub December 15, 2014; Published December 30, 2014

**Abstract:** An 8-year-old girl was enrolled in hospital with intermittent gross hematuria in a period of 3 years. Bloody efflux from the left ureteral orifice was diagnosed in this patient with urethrocytostomy. A retroaortic left renal vein appeared to be compressed by the aorta as detected by computerized tomography. The left renal vein was compressed between the aorta and the spine. A groove in the anterior surface of the left renal vein was detected. A transposition surgery of the left renal vein to a site in front of the aorta was performed for the patient. The patient was discharged after recovery and the hematuria symptom was not found during the 15-month follow-up investigation.

**Keywords:** Posterior nutcracker syndrome, renal vein, hematuria, surgery

### Introduction

The nutcracker syndromes, including the anterior nutcracker syndrome and the posterior nutcracker syndrome, often cause hematuria [1-3]. The nutcracker syndromes result often from compression of the left renal vein (LRV) between the superior mesenteric artery and the abdominal aorta, leading to renal venous hypertension and formation of renal hilar varices [4, 5]. Posterior nutcracker syndrome refers to the left renal venous hypertension due to compression of the retroaortic left renal vein (RLRV) between the aorta and the spine [6, 7]. The posterior nutcracker syndrome is rarely found and the effective treatment is needed to be studied. We have now reported the surgical treatment of a rare case of posterior nutcracker syndrome and the surgical efficacy.

### Case report

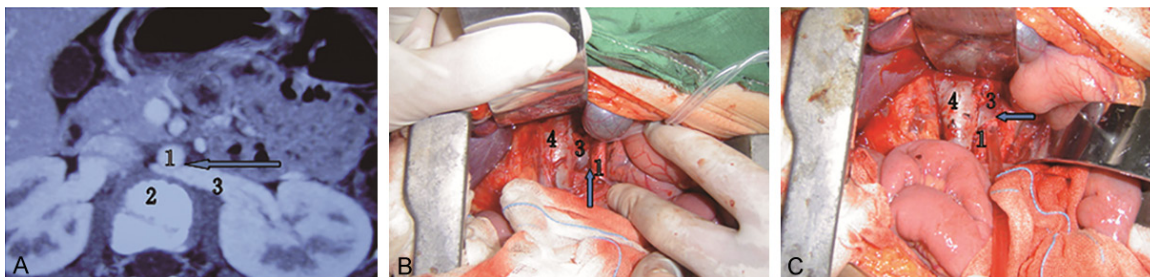
An 8-year-old girl was enrolled in hospital with intermittent gross hematuria in a period of 3 years. The patient did not have the history of renal trauma, urinary tuberculosis, urinary bilharziasis, renal calculi or other diseases. Urinalysis detection of this patient showed 10-15 red blood cells per high power field. With phase-

contrast microscopy, isomorphic red blood cells were revealed in this patient, which excluded a glomerular cause for hematuria. The test results for tuberculosis and bilharziasis were negative. Casts were absent and the urine cytology result was negative for malignancy. Abdominal ultrasonography and excretory did not found causes for her hematuria.

However, the urethrocytostomy examination revealed a bloody efflux from the left ureteral orifice in this patient. Computerized tomography examination revealed a retroaortic left renal vein, which appeared to be compressed by the aorta (**Figure 1A**). No evidence was found for collateral decompression flow such as via the gonadal vein. Phase differences between the right and left kidneys in the corticomedullary, parenchymal and excretory phases were not found. The LRV was compressed between the aorta and the spine. A groove in the anterior surface of the LRV was found, where it passed posterior to the aorta (**Figure 1B**).

To treat this disease, the left renal vein was cut and transposed to a position in front of the aorta to perform side anastomosis with the vena cava (**Figure 1C**). During the surgery, the side anastomosis without clamping the left

## Left renal vein transposition



**Figure 1.** Diagnosis and surgery of the posterior nutcracker syndrome case. A. Computerized tomography showed left renal vein (arrow) compressed between the aorta posteriorly and the vertebral column anteriorly. Distal part of left renal vein was more dilated compare with proximal portion. B. Intraoperative photograph showing a groove at the left renal vein (arrow) at site of compression by the aorta. C. Postoperative detection of the transposition of the left renal vein. The arrow indicates the site of the left renal vein across the aorta. 1, Abdominal aorta; 2, spine; 3, left renal vein; 4, inferior vena cava.

renal artery between the left renal vein and the vena cava took only 12 minute. The whole surgery resulted in a loss of only 120 ml of blood. After the surgery, urine volume and creatinine levels were normal. In 1 week after the surgery, the hematuria disappeared. The 15 month following up investigation found that the liver and kidney functions are normal. The urine routine examination results are normal, with hematuria found.

### Discussion

RLRV is a malformation characterized by the presence of a vessel that drains the left renal blood up to the inferior vena cava crossing behind the aorta. Hoeltl et al [8] classified RLRV into 2 types. Type 1, including this case, is an orthotopic retroaortic renal vein. In type 2, a single LRV descends the renal hilum, joins the testicular (or ovarian) and ascending lumbar veins before joining the inferior vena cava, and passes behind the aorta and in front of the vertebra. The incidence of the type 1 has been report to be 0.3% to 1.9% in the population in the world [8]. The increased venous pressure within the renal circulation promotes the development of collaterals of the renal pelvis, and this plexus of abnormal hypertensive veins causes microhematuria or gross hematuria [9-11]. Other possible symptoms include left flank pains [12], left-sided varicocele [13].

Although diagnostic criteria of posterior nutcracker syndrome have not been established, the venography and venous pressure measurement are two methods often used in diagnosis of nutcracker syndrome [14]. Left renal venog-

raphy is not suitable to be used for children, indicating that a noninvasive method of diagnosis is more desirable [15]. Alternative methods to confirm the diagnosis have also been proposed, including computerized tomography examination and the computerized tomography angiography, simple magnetic resonance imaging and magnetic resonance angiography, Doppler sonography.

Hematuria can be caused by increased pressure in the renal vein. Conservative treatment has been proposed for cases of mild hematuria, while surgery is useful treatment for massive hematuria and pain. In this study, the transposition of the left renal vein is effective for posterior nutcracker syndrome. During the surgery, the side anastomosis without clamping the left renal artery between the left renal vein and the vena cava took only 12 minutes, which is helpful for attenuating the effects on liver and kidney functions. The whole surgery resulted in a loss of only 120 ml of blood. In 1 week after the surgery, the hematuria disappeared. The 15-month following up investigation found that the liver and kidney functions are normal. The urine routine examination results are normal, with no hematuria found.

### Disclosure of conflict of interest

None.

**Address correspondence to:** Dr. Jinchun Xing, Department of Urology, The First Hospital Affiliated to Xiamen University, Zhenhai Road 55, Xiamen 361003, P. R. China. Tel: +86-013606061735; E-mail: xmurology@126.com

## Left renal vein transposition

### References

- [1] Alaygut D, Bayram M, Soylu A, Cakmakci H, Türkmen M and Kavukcu S. Clinical Course of Children With Nutcracker Syndrome. *Urology* 2013; 82: 686-690.
- [2] Qin J, Zheng XY and Jiang H. Posterior nutcracker phenomenon in patient with renal arteriovenous malformation. *Urology* 2012; 80: e73-74.
- [3] Polaina-Rusillo M, Liébana-Carpio L, Borrego-Hinojosa J and Liébana-Cañada A. Gross haematuria in patients with nutcracker syndrome. *Nefrologia* 2012; 32: 537-538.
- [4] El Sadr AR and Mina A. Anatomical and surgical aspects of the operative management of varicoceles. *Urol Cutan Rev* 1950; 54: 257-262.
- [5] Chung BI and Gill IS. Laparoscopic splenorenal venous bypass for nutcracker syndrome. *J Vasc Surg* 2009; 49: 1319-1323.
- [6] Lau JLT, Lo R, Chan FI and Wong KK. The posterior "nutcracker": hematuria secondary to retroaortic left renal vein. *Urology* 1986; 20: 437-439.
- [7] Marone EM, Psacharopulo D, Kahlberg A, Coppi G and Chiesa R. Surgical treatment of posterior nutcracker syndrome. *J Vasc Surg* 2011; 54: 844-847.
- [8] Hoeltl W, Hruby W and Aharinejad S. Renal vein anatomy and its implication for retroperitoneal surgery. *J Urol* 1990; 143: 1108-1114.
- [9] Macmahon HE and Latorraca R. Essential renal hematuria. *J Urol* 1954; 71: 667-676.
- [10] Pytel A. Renal fornical hemorrhages: their pathogenesis and treatment. *J Urol* 1960; 83: 783-789.
- [11] Low AI and Matz LR. Haematuria and renal fornical lesions. *Br J Urol* 1972; 44: 681-689.
- [12] Takemura T, Iwasa H, Yamamoto S, Hino S, Fukushima K, Isokawa S, Okada M and Yoshioka K. Clinical and radiological features in four adolescents with nutcracker syndrome. *Pediatr Nephrol* 2000; 14: 1002-1005.
- [13] Zerhouni EA, Siegelman SS, Walsh PC and White RI. Elevated pressure in left renal vein in patients with varicocele: preliminary observations. *J Urol* 1980; 123: 512-513.
- [14] Stewart BH and Reiman G. Left renal venous hypertension "nutcracker" syndrome. Managed by direct renocaval reimplantation. *Urology* 1982; 20: 365-369.
- [15] Zerlin JM, Hernandez RJ, Sedman AB and Kelsch RC. "Dilatation" of the left renal vein on computer tomography in children: a normal variation. *Pediatr Radiol* 1991; 21: 267-269.