

Original Article

Risk factors of free anterolateral thigh flap failure for reconstruction of lower-limb defects: a 10-year experience

Xiaqing Yang¹, Hede Yan², Yongzhi Fan¹, Junli Dong¹, Yi Cai^{1*}, Zhijie Li^{2*}

¹Department of Pain Treatment, The Central Hospital of Wuhan, Tongji Medical College, Huazhong University of Science and Technology, Wuhan, China; ²Department of Hand and Plastic Surgery, The Second Affiliated Hospital and Yuying Children's Hospital of Wenzhou Medical University, Wenzhou, China. *Equal contributors.

Received July 22, 2017; Accepted June 8, 2018; Epub October 15, 2018; Published October 30, 2018

Abstract: Background: The risk factors of free anterolateral thigh flap in lower extremity reconstruction have not been well defined. We sought to further demonstrate certain risk factors affecting the occurrence of free anterolateral thigh flap failure for lower limb defects. Methods: A retrospective review of patients undergoing free anterolateral thigh flap reconstruction between November 2005 and November 2015 was performed. Chi-squared test, Fisher's exact test and Regression analysis were used to assess risk factors for free anterolateral thigh flap failure. Symptom Distress Check List (SCL-90) was applied for evaluating mental health conditions of patients. Results: A total of 137 free anterolateral thigh flaps were performed for the reconstruction of lower limb defects in 128 patients. The overall proportion of free anterolateral thigh flap failure was 14%. Free anterolateral thigh flap failure was associated with age (odds ratio [OR], 4.569, 95% confidence interval [95% CI], 1.424 to 14.685, $p=0.015$), smoking (OR, 3.408, 95% CI, 1.104 to 10.525, $p=0.038$), diabetes mellitus (OR, 5.197, 95% CI, 1.693 to 15.949, $p=0.006$), osteomyelitis (OR, 3.731, 95% CI, 1.195 to 11.644, $p=0.028$), variation of perforator (OR, 5.547, 95% CI, 1.338 to 22.990, $p=0.027$), operative time (OR, 3.733, 95% CI, 1.366 to 10.201, $p=0.012$), mental health condition (OR, 4.514, 95% CI, 1.624 to 12.551, $p=0.004$), the size of the defect (OR, 4.043, 95% CI, 1.113 to 14.688, $p=0.039$), the generation of fibrous protein (OR, 5.827, 95% CI, 1.745 to 19.459, $p=0.007$). Conclusions: Age, smoking, diabetes mellitus, osteomyelitis, variation of perforator, operative time, mental health condition, the size of the defect, the generation of fibrous protein in anastomotic stoma were independent risk factors of free anterolateral thigh flap failure. Among these risk factors, mental health condition was most closely associated with free anterolateral thigh flap failure.

Keywords: Free anterolateral thigh flap, risk factors, lower limb defects, flap failure.

Introduction

The reconstruction of the lower extremity with soft tissue defects has always been a common but challenging clinical entity, and they generally need flaps coverage. Among numerous protocols described to manage defects of the lower extremity, there were direct suturing, skin grafting, local flaps, and free flaps [1]. Before the concept of microsurgery, surgeons had few reconstructive options other than local flaps, such as the local muscle flaps, advanced flaps, cross-leg flaps and local perforator flaps, which were perfect for time efficient and effortless reconstruction of the lower extremity. However, they do contain certain disadvantages, as an

example, vulnerable venous return, the limbs immobilization for weeks with a large amount of skin transferred, restrictions of flap advancement or coverage, the limited flap size which could result in joint stiffness and poor sensation, large scars on donor and recipient lower extremity [2]. In addition, in certain conditions, the application of a local or distant flap is not an optimal reconstruction [3-5].

With the development of reconstructive microsurgery, a new operation style for limb-saving procedures has become available. The concept of the free anterolateral thigh flap belongs to Song et al, who first demonstrated the utilization of the free anterolateral thigh flap in 1984

Risk factors for free anterolateral thigh flap failure

and achieved a wonderful outcome in dimensions of wound coverage [6]. Soon afterwards, a rapidly growing literature regarding the use of the free anterolateral thigh flap for reconstruction of the lower extremity was reported with a high survival rate [7-9]. Based on a long pedicle from the lateral femoral circumflex artery, the flap is versatile and reliable. Before long the free anterolateral thigh flap has been one of the dominating reconstructive options for the lower extremity, particularly for severe lower extremity injuries [10-12]. In the wake of popularization of the free anterolateral thigh flap in the sphere of reconstruction and plastic, the flap has become a standard technique for lower extremity reconstruction. The free anterolateral thigh flap is generally indispensable for extensive defects as well as territory where there are no regional options [13, 14].

To date, the flap survival rate has ranged 94.0-97.3 % with improvements and growing experience in microsurgical reconstruction [15]. Although the flap survival rate is extremely high, and functional outcomes of lower extremity reconstruction by the use of the free anterolateral thigh flap have been evaluated extensively, flap necrosis does occasionally occur. So the evaluation of risk factors and countermeasures that prevent flap necrosis are indispensable. However, clinical studies regarding risk factors of the free anterolateral thigh flap for the reconstruction of lower extremity are relatively scarce.

Therefore, this retrospective study, derived from our 10-year experience with soft tissue defect located at the lower extremity that were reconstructed with the free anterolateral thigh flap, was conducted. On the one hand, the aim of this study was to assess the risk factors of the free anterolateral thigh flap in lower extremity soft tissue reconstruction, on the other hand, it is an attempt to further offer a series of credible and accurate reference data that could promote the flap survival rate in lower extremity reconstruction.

Patients and methods

Between November 2005 and November 2015, a series of 128 patients with soft tissue defects located at the lower extremity underwent the free anterolateral thigh flap procedures at our institution. After vigorous debridement, a total

of 137 cases of free anterolateral thigh flaps were performed for reconstruction of the lower extremity. Patients associated with ulceration/gangrene/osteomyelitis of the lower extremity were treated by wound debridement and reconstructions in accordance with the limb salvage protocol [16]. Chronic osteomyelitis was diagnosed with patient history, physical examination, clinical and radiographic examinations, and confirmed by intraoperative cultures and histological examinations. In the majority of the patients, Doppler examination was applied approximately one week prior to the operation, especially for patients with diabetes mellitus and the elderly aged 60 years or older.

A meticulous preoperative assessment for all patients and their wounds were made, to decide whether they were suitable for the operation. Blood routine examination, strict blood glucose control, coagulation function, and close clinical monitoring of the patient's general condition were prerequisites for surgery. Each patient was required for lower extremity pulse and plain radiograms, and patient suspected of having osteomyelitis underwent scintigraphy. Necrotic and infected tissues were resected and removed before surgery. A culture-based antibiotic treatment was administered in infected patients and continued postoperatively in accordance with the bacterial culture of wound secretion and drug sensitivity test. Transcutaneous oxygen measurements were greater than 30 mmHg in cases which need reconstruction.

In this retrospective study, demographic characteristics were collected, so as were defect site, complications, containing partial and complete flap loss, causes of the injury, hospital stays, operative time, duration of follow-up and so on. We reviewed those messages and interviewed the patients and/or their families in the office or by telephone in January of 2016.

Mental health condition was assessed by Symptom Distress Check List (SCL-90). SCL-90 is a self-report scale that is extensively used in normal and tormenting population. Validity and reliability of SCL-90 were demonstrated in the Turkish population. The content of SCL-90 contains ninety items which are divided into 10 subscales, including somatization (SOM), obsessive-compulsive (OC), phobic anxiety (PHOB), interpersonal sensitivity (INT),

Risk factors for free anterolateral thigh flap failure

Table 1. Mechanism and Flaps Required for Coverage

Causes	Sex (Male/Female)		No. of Patients (no. of flaps)	Percent of Patients (percent of flaps)
Acute trauma				
Road traffic accident	25	7	32 (36)	25 (26.3)
Industrial accident	10	0	10 (11)	7.8 (8.0)
Burn	2	2	4 (4)	3.1 (2.9)
High falling injuries	5	0	5 (5)	3.9 (3.6)
Gunshot	1	0	1 (2)	0.8 (1.5)
Electric injuries	1	1	2 (3)	1.6 (2.2)
Crush injuries	4	1	5 (5)	3.9 (3.6)
Chronic trauma				
Infection/necrotizing fasciitis wounds	22	8	30 (32)	23.4 (23.4)
Unstable scarring	2	1	3 (3)	2.3 (2.2)
Diabetic foot	12	6	18 (18)	14.1 (13.1)
Osteomyelitis	13	5	18 (18)	14.1 (13.1)
Total	97	31	128 (137)	100 (100)

anger-hostility (HOS), depression (DEP), paranoid thought (PAR), anxiety (ANX), psychotism (PYS), and extra scale (ES). Scores are considered as general symptom index (GSI), with higher scores indicating more problems. In our research, scores from 0 to 0.99 were deemed normal, and those over 1 manifest psychopathology.

After sifting the irrelevant factors, we chose the factors that might influence the survival of the free anterolateral thigh flap, which included age, sex, smoking, diabetes mellitus, osteomyelitis, variation of perforator, recipient vessel, ratio of artery and the vein, the method of vascular anastomosis, operative time, mental health condition, the infection of recipient site, the size of the defect, the generation of fibrous protein in anastomotic stoma. What is more, we evaluated the survival and function of the free anterolateral thigh flap.

Statistical analysis

Statistical analysis was performed using chi-squared test or Fisher's exact test for categorical variables and logistic regression analysis for multivariate analysis. A value of $p < 0.05$ was considered to manifest statistically significant differences. All the statistical analyses were conducted with SPSS version 19. Each patient had to sign written informed consent prior to surgery and preserved in the documentation department.

Results

Baseline and demographic characteristics

Ninety-seven males (75.8%) and 31 females (24.2%) were involved in this series, with an approximately 3:1 male-to-female ratio, and their ages at the time of operation varied from 4 to 71 years, with an average age of 40.8 years. The mean age of male patients during operation was 43.4 years (range, 6 to 71 years) and that of female patients was 32.8 years (range, 4 to 69 years).

Causes of defects

The causes of the wounds included road traffic accident in 32 cases, industrial accident occurred in 10 cases, burn in 4 cases, high falling injuries in 5 cases, gunshot in 1 case, electric injuries in 2 cases, crush injuries in 5 cases, infection/necrotizing fasciitis wounds in 30 cases, unstable scarring in 3 cases, diabetic foot or diabetes mellitus after ORIF for fractures in 18 cases, osteomyelitis in 18 cases (**Table 1**).

Sites and size of defects

All wounds had exposed tendon, bone, and/or joint after debridement. The soft-tissue defects were primarily located on the foot dorsum ($n=38$), followed by the ankle (30), then the pretibial area ($n=24$), the heel (20), the

Risk factors for free anterolateral thigh flap failure

Table 2. Defect site

Location	Sex (Male/Female)		Age (mean years)	No. of Patients (no. of flaps)	Percent of Patients (percent of flaps)
Ankle	19	11	4-62 (36.7)	30 (33)	23.4 (24.1)
Foot dorsum	30	8	7-69 (39.3)	38 (43)	29.7 (31.4)
Heel	15	5	6-71 (41.0)	20 (20)	15.6 (14.6)
Plantar area	9	1	21-61 (38.7)	10 (10)	7.8 (7.3)
Pretibial area	21	3	25-71 (48.8)	24 (25)	18.8 (18.2)
Popliteal area	3	3	21-64 (42.3)	6 (6)	4.7 (4.4)
Total	97	31	4-71 (40.8)	128 (137)	100 (100)

Table 3. Medical Complications

Medical Complications	No. of Patients	Percent of Patients
Complete flap loss	6	18.2
Partial flap loss	13	39.4
Venous thrombosis	10 (3 resulting in complete flap failures)	21.2
Arterial thrombosis	1	3.0
Split-thickness skin graft loss	2	6.1
Dehiscence	2	6.1
Infection	2	6.1
Total	33	100

plantar area (10), and last the popliteal area (6) (**Table 2**). Defect sizes ranged from 3 cm × 2 cm to 25 cm × 15 cm, the mean size of the free flap was 16 cm × 10 cm. The wounds were debrided with an average of 2.6 times (range, 1 to 9 times). The average length of hospital stay was 33.9 days (range, 7 to 111 days). Average follow-up time was 2.5 years.

Vascular anastomosis

Recipient arteries used were the anterior tibial artery (56 cases), the posterior tibial artery (46 cases), the dorsalis pedis artery (17 cases), the peroneal artery (5 cases), the popliteal artery (2 cases), the medial plantar artery (1 case), the lateral plantar artery (1 case). With respect to the ratio of artery and the vein, two venous anastomoses and one venous anastomoses were used in 85 and 43 patients, respectively. The arterial end-to-end anastomoses were performed in 96 patients and that of end-to-side were in 31 patient, and vein grafting was performed in 1 patients. The mean duration of surgery was 5.9 hours (range from 4 to 19 hours).

Complications of the free anterolateral thigh flap

Of the 137 reconstructive operations required, a total of 36 complications occurred in 33 patients, for a 26 percent complication rate, including complete flap failures (n=6), partial flap loss (n=13), venous thrombosis (n=10), arterial thrombosis (n=1), split-thickness skin graft loss (n=2), dehiscence (n=2), infection (n=2) (**Table 3**). In 5 cases of complete flap failures, five types of flaps were used to reconstruct the defect, including the lateral retromalleolar perforator flap, the poste-

rior tibial artery perforators flap, the free anterolateral thigh flap, the thoracic umbilical flap, and the retrograde anterior tibial artery island flap. Below-knee amputation was performed in one case of complete flap failures. Of the 13 partial flap loss, the flaps healed without further intervention in 3 cases, sutured after debridement in 2 cases, local skin flap transposition in 3 cases, and split-thickness skin graft in 5 cases. Blood vessel crisis occurred in 11 cases within 48 hours after surgery and 8 flaps survived finally by means of exploring and anastomoses vessels.

The survival of the free anterolateral thigh flap

The overall flap success rate was 86%, as 118 of 137 flaps were successful, this was considerably lower than other reports (**Figure 1**). However, the cases suffering flap necrosis were associated with at least one of the above risk factors. If patients who combined with the risk factors were excluded from the analysis, the complete flap success rate was high as 99.2 percent. One hundred and twenty-seven of 128 wounds initially covered with free anterolateral thigh flaps healed the wound, for an approximately 100 percent limb salvage rate, with an

Risk factors for free anterolateral thigh flap failure

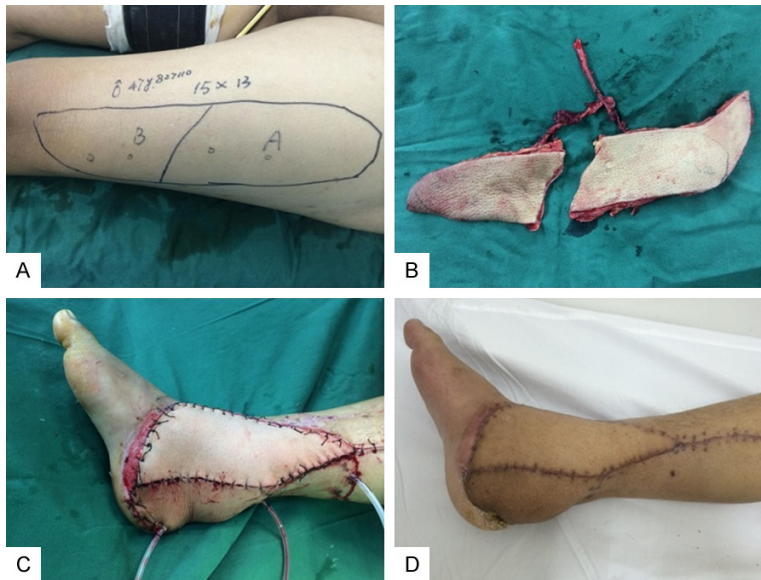


Figure 1. A. An anterolateral thigh flap was designed to cover the defect of the right lower-limb after medial malleolus fracture in a 48-year-old man. B. A bi-lobed island flap was harvested. C. The donor site was closed primarily. D. Follow-up at 3 months.

mean time of 121 days to union. Follow-up visit was conducted in 88 percent of patients, of those patients, 90 percent could walk comfortably, and 82 percent were exceedingly satisfied with the reconstructive outcome.

Results of related data analysis

The analysis of relevance between each risk factor and flap necrosis showed that the *P*-values of sex ($p=1.000$), age ($p=0.015$), diabetes mellitus ($p=0.006$), smoking ($p=0.038$), operative time ($p=0.012$), the size of the defect ($p=0.039$), osteomyelitis ($p=0.028$), variation of perforator ($p=0.027$), the generation of fibrous protein in anastomotic stoma ($p=0.007$), mental health condition ($p=0.004$), the infection of recipient site ($p=0.772$), recipient vessel ($p=0.407$), the method of vascular anastomosis ($p=0.780$), and ratio of artery and the vein ($p=0.069$), therefore, age, smoking, diabetes mellitus, operative time, the size of the defect, osteomyelitis, variation of perforator, mental health condition and the generation of fibrous protein in anastomotic stoma were statistically significant (**Table 4**). Based on analysis data, mental health condition was the most significant risk factor in this study.

Discussion

The paramount objective of lower extremity reconstruction is to acquire function and agree-

able appearance, for which bone reconstruction with steady soft tissue coverage is essential. More tissue and function would be lost if failure occurred in the initial reconstruction. As a consequence, it is crucial to make the advisable treatment plan, and it is suggestive of the free anterolateral thigh flap would be one of the best therapies for patients who suffered from severe injuries of the lower extremities.

The free anterolateral thigh flap has been extensively used for lower extremity reconstruction over the past three decades. However, flap failure prefers to occur in lower extremity rather than other regions of the body [17]. Few

reports analyzed the factors and strategies of the free anterolateral thigh flap for the lower extremity reconstruction [18]. Although flap failures remain unavoidable, discovering risk factors in reducing the flap survival rate is essential. In this section, the question under discussion is the risk factors that influence the flap survival rate in lower extremity reconstruction.

A closer look at the data indicates that age, smoking, diabetes mellitus, osteomyelitis, variation of perforator, operative time, mental health condition, the site of the defect, the generation of fibrous protein in anastomotic stoma are the independent risk factors which could result in the flap necrosis in our study. The results are differ from other reports, Min Jo Kang found no correlation in his study between age, diabetes mellitus, smoking and complications [19].

High quality vascular anastomosis is the basic condition of a successful operation, but with the advance of microsurgical technique, the small blood vessels anastomosis is no longer the main factor affecting flap necrosis. In our study, age is one of the risk factors that can easily lead to flap failure. The incidence rate of skin flap necrosis increased significantly in patients older than 60 years. The reasons could attribute to the greatly reduced skin fibro-

Risk factors for free anterolateral thigh flap failure

Table 4. Influence of patient demographic and *P* Value of flap failure

	No. of Patients or Flaps	No. of Flap Failure	Odds Ratio	95% CI	<i>P</i> Value
Sex			1.235	0.377-4.041	1.000
Male	97	15			
Female	31	4			
Age category			4.569	1.424-14.685	0.015
<60 yr	112	13			
≥60 yr	16	6			
Smoking			3.408	1.104-10.525	0.038
Yes	19	6			
No	119	13			
Diabetes mellitus			5.197	1.693-15.949	0.006
Yes	18	7			
No	110	12			
Operative time			3.733	1.366-10.201	0.012
<10 h	93	9			
≥10 h	35	10			
The size of the defect			4.043	1.113-14.688	0.039
<100 cm ²	50	3			
≥100 cm ²	78	16			
Osteomyelitis			3.731	1.195-11.644	0.028
Yes	18	6			
No	110	13			
Mental health condition			4.514	1.624-12.551	0.004
<1 score	86	7			
≥1 score	42	12			
The infection of recipient site			1.200	0.394-3.658	0.772
Yes	30	5			
No	98	14			
Variation of perforator			6.027	1.456-24.954	0.022
Yes	9	4			
No	128	15			
The generation of fibrous Protein in anastomotic stoma			6.346	1.903-21.165	0.005
Yes	14	6			
No	123	13			
Recipient vessel			0.436	0.147-1.299	0.176
Anterior tibial artery	61	6			
Posterior tibial artery	50	10			
Dorsalis pedis artery	17	2			
Peroneal artery	5	0			
Popliteal artery	2	1			
Medial plantar artery	1	0			
Lateral plantar artery	1	0			
The method of vascular anastomosis			0.977	0.324-2.942	1.000
End-to-end	100	14			
End-to-side	35	5			
Vein graft	2	0			
Ratio of artery and the vein			2.339	0.878-6.232	0.119
1:1	48	10			
1:2	89	9			

Risk factors for free anterolateral thigh flap failure

blasts proliferation ability, capacity reduction in blood supply obstacles, blood vessel elasticity decreased due to the loss of cardiac function, all these contribute to slow wound healing and give rise to wound infection.

Smoking is also the risk factor that influences the survival rate of skin flap. The nicotine in tobacco plays an important role in vascular contraction, it can decrease the blood supply of the recipient area, which could cause a great loss to oxygen and nutrients material in the skin flap area. At the same time, smoking can increase the NO content in the blood, NO is able to combine with oxygen competitively, that reduces the oxygen content in the blood. In particular, smoking can injure flap vessels resulting in intimal fibrosis [20].

The possible role of diabetes mellitus as a risk factor was not considered in a slice of reports [21]. However, in our study, we have found that diabetes mellitus was also a negative predictive risk factor for free anterolateral thigh flap surgery. Patients with diabetes mellitus may suffer a greater flap failure rate on account of atherosclerosis of the vessel intima. Besides, high levels of blood sugar could give rise to impaired healing, vascular occlusion and flap infection.

Our analysis of risk factors also indicates that operative time and the size of the defect had an influence on outcome (the longer the time and the greater the flap area involved, the greater the risk of failure). Three possible explanations for this result are considered: in the first place, the longer surgical time could trigger a longer ischemic period, the critical cold ischemia time of each tissue is different, once the critical time is exceeded, the flap may suffer from reperfusion ischemia, resulting in problematic healing and damage to tissue on account of anoxic injuries [22, 23]. There is one more point, the longer operative time and greater size of the defect are more inclined to associate with surgery performed by multiple surgeons, which could lead to an increase operative complication rates in the free anterolateral thigh flap reconstruction and a greater standard of complexity. The last but not the least, longer operative time invariably means more significant blood loss, resulting in ischemia reperfusion through the reconstruction, which may give rise to partial flap loss, especially for the greater size of flap.

This study manifests that osteomyelitis, as an independent variable, was associated with an apparent increase in the free anterolateral thigh flap failure. A previous study indicated that no significant increase of flap failure was observed in patients suffered from osteomyelitis [24]. However, our study demonstrated that osteomyelitis was a vital risk factor for the use of free anterolateral thigh perforator flap in the lower extremity reconstruction. Despite an adequate and extensive débridement were performed followed by complete obliteration by the use of free anterolateral thigh musculocutaneous or muscle flaps for the coverage of the dead space [25-27], the rate of flap necrosis was comparatively high in this series. Undoubtedly, the consequences of osteomyelitis in lower extremity due to diabetes or trauma has always been disastrous, and usually the prolonged hospitalization caused by multiple and resistant organisms, nonunions or bone defects was inevitable. In addition, multiple operations were performed, and often the limb function is impaired, all these led to a low successful rate in the reconstruction of osteomyelitis located at the lower extremity by the use of free anterolateral thigh flap.

Additionally, our findings indicated that variation of perforator was significant risk factor for free anterolateral thigh flap failure in patients with soft tissue defect of the lower extremity. The complexity and variation of the local vasculature were frequently the most untoward facet of the anterolateral thigh. The overall incidence of cases without suitable perforators was found to be 1.8%, suggesting that the vast majority of free anterolateral thigh flaps likely possessed suitable perforators for harvest, however, vascular flap embarrassment and tissue loss could occur if the surgeons failed to understand its variability [28]. Although knowledge of pertinent normal and variant anatomy for the free anterolateral thigh flap has detailedly described in the literature to date, the potential variation of perforator could bewilder the surgeon in intraoperative decision-making concerning flap design [29, 30]. Furthermore, variation of perforator was usually associated with a prolonged operation time that may increase the probability of flap necrosis. In our study, the average operation time was 12.5 hours in patients with variation of perforator that may contribute to the high incidence of flap failure. And due to

Risk factors for free anterolateral thigh flap failure

anatomical variations (including variation of perforator and absence of dominant perforators), ischaemic complications increased.

The possible role of the generation of fibrous protein in anastomotic stoma as a negative predictive risk factor for free anterolateral thigh flap surgery was considered in our study. So far, correlation research regarding the risk factor of the generation of fibrous protein in anastomotic stoma is few. The role of fibrous protein in anastomotic stoma is indistinct. However, in our report, 6 of 14 patients who associated with the generation of fibrous protein in anastomotic stoma were subjected to flap necrosis with a value of $p=0.007$. Thus, the generation of fibrous protein in anastomotic stoma was bound up with the flap necrosis.

The mechanism may lie as follows: the generation of fibrous protein in anastomotic stoma demonstrated that a large number of blood clotting enzyme had been generated in vascular pedicle of the flap. Meanwhile, vascular pedicle of the flap had been damaged. Both activated the mechanism of endogenous and exogenous coagulation, the thrombin would produce more F X a and F IX a, which could form more endogenous clotting enzyme, known as the waterfall theory, and amplification reaction could produce in the thrombin. If the contaminated still blood clotting occurred within the vascular injury, the thrombogenesis would unavoidably appear within 24 hours after surgery, even if the vascular anastomosis was instant unobstructed. These all led to the high incidence of flap necrosis in patients with the generation of fibrous protein in anastomotic stoma.

In the end, we will focus on the risk factor of mental health condition. The *P*-value of mental health condition was 0.004, on the basis of the data, it is the most statistically significant risk factor in our study. It represents psychopathology when the scores are over 1. Stress responses such as tense and anxious will take on in this condition, which could greatly stimulate the secretion of catecholamine in the body. The superabundant catecholamine is able to facilitate the contraction of blood vessels. If that happens, spasm will occur in the blood vessels of flap area, the artery crisis could come into being, the flap reconstruction will fail if emergency measures are not enough.

As in any retrospective review, this study had some limitations. Some degree of selection bias is inescapable. This research includes only those patients who eventually underwent free anterolateral thigh flap transfers. On initial surgical counseling, only those patients who the surgeon considered could tolerate the surgical procedure were offered free anterolateral thigh flap transfers, those who were felt unable to tolerate surgery or recovery were excluded. Fifteen patients (12%) were lost to followup after 1 year, as a consequence, other complications or functional rehabilitation were unable to evaluate. The number of patients is not extremely large, some analysis of data could have been more accurate if a multitude of patients were participated. Three main surgeons in our institution performed the procedures, that may influence the outcomes in some degree. Given these limits and our relatively small numbers, it is likely that association of risk factors with flap failures might not have been exceedingly precise related to insufficient sample size. In spite of this, our data should be considered useful primary data for farther, larger, multicenter studies on this theme.

Conclusions

Free anterolateral thigh flap transfer can be conducted with a high rate of success in well-selected patients, however, grievous medical complications remain troublesome. In this study, each risk factor is likely to influence the results. Our study indicates that age, smoking, diabetes mellitus, osteomyelitis, variation of perforator, operative time, mental health condition, the site of the defect, the generation of fibrous protein in anastomotic stoma are the pivotal risk factors in this respect. In addition, we have also demonstrated that mental health condition is the most significantly risk factor associated with free anterolateral thigh flap failure.

Acknowledgements

This study was supported by the following grants: the Natural Science Foundation of Zhejiang province (Grant No. Y16H060039), the funding of Health Department of Zhejiang province (201599567) and the funding of Science and Technology Bureau of Wenzhou (Y20150056).

Risk factors for free anterolateral thigh flap failure

Disclosure of conflict of interest

None.

Address correspondence to: Zhijie Li, Department of Hand and Plastic Surgery, The Second Affiliated Hospital and Yuying Children's Hospital of Wenzhou Medical University, Wenzhou, China. Tel: +86 13587969029; Fax: 0577-88816173; E-mail: 15356232976@163.com; Yi Cai, Department of Pain Treatment, The Central Hospital of Wuhan, Tongji Medical College, Huazhong University of Science and Technology, Wuhan, China. Tel: +86 138-71125953; Fax: 027-82811080; E-mail: 332760-093@qq.com

References

- [1] Gottlieb LJ, Krieger LM. From the reconstructive ladder to the reconstructive elevator. *Plast Reconstr Surg* 1994; 93: 1503-1504.
- [2] Jayes PH. Cross-leg flaps: a review of 60 cases. *Br J Plast Surg* 1950; 3: 1-5.
- [3] Godina M. Early microsurgical reconstruction of complex trauma of the extremities. *Plast Reconstr Surg* 1986; 78: 285-292.
- [4] Francel TJ, Vander Kolk CA, Hoopes JE, Manson PN, Yaremchuk MJ. Microvascular soft-tissue transplantation for reconstruction of acute open tibial fractures: timing of coverage and long-term functional results. *Plast Reconstr Surg* 1992; 89: 478-487.
- [5] Hallock GG. Utility of both muscle and fascia flaps in severe lower extremity trauma. *J Trauma* 2000; 48: 913-917.
- [6] Song YG, Chen GZ, Song YL. The free thigh flap: a new free flap concept based on the septocutaneous artery. *Br J Plast Surg* 1984; 11: 149-159.
- [7] Kuo YR, Jeng SF, Kuo MH, Huang MN, Liu YT, Chiang YC, Yeh MC, Wei FC. Free anterolateral thigh flap for extremity reconstruction: clinical experience and functional assessment of donor site. *Plast Reconstr Surg* 2001; 107: 1766-1771.
- [8] Yildirim S, Gideroglu K, Akoz T. Anterolateral thigh flap: ideal free flap choice for lower extremity soft-tissue reconstruction. *J Reconstr Microsurg* 2003; 19: 225-233.
- [9] Ozkan O, Coskunfirat OK, Ozgentas HE. The use of the free anterolateral thigh flap for reconstructing soft tissue defects of the lower extremities. *Ann Plast Surg* 2004; 53: 455-461.
- [10] Saint-Cyr M, Schaverien M, Wong C, Nagarkar P, Arbique G, Brown S, Rohrich RJ. The extended anterolateral thigh flap: anatomical basis and clinical experience. *Plast Reconstr Surg* 2009; 123: 1245-1255.
- [11] Park JE, Rodriguez ED, Bluebond-Langer R, Bochicchio G, Christy MR, Bochicchio K, Scalea TM. The anterolateral thigh flap is highly effective for reconstruction of complex lower extremity trauma. *J Trauma* 2007; 62: 162-165.
- [12] Askouni EP, Topping A, Ball S, Hettiaratchy S, Nanchahal J, Jain A. Outcomes of anterolateral thigh free flap thinning using liposuction following lower limb trauma. *J Plast Reconstr Aesthet Surg* 2012; 65: 474-481.
- [13] Soltanian H, Garcia RM, Hollenbeck ST. Current concepts in lower extremity reconstruction. *Plast Reconstr Surg* 2015; 136: 815-829.
- [14] Cavadas PC, Landín L, Ibáñez J, Nthumba P. Reconstruction of major traumatic segmental bone defects of the tibia with vascularized bone transfers. *Plast Reconstr Surg* 2010; 125: 215-223.
- [15] Xiong L, Gazyakan E, Kremer T, Hernekamp FJ, Harhaus L, Saint-Cyr M, Kneser U, Hirche C. Free flaps for reconstruction of soft tissue defects in lower extremity: a meta-analysis on microsurgical outcome and safety. *Microsurgery* 2016; 36: 511-24.
- [16] Brem H, Sheehan P, Rosenberg HJ, Schneider JS, Boulton AJ. Evidence-based protocol for diabetic foot ulcers. *Plast Reconstr Surg* 2006; 117: 193-209.
- [17] Demirtas Y, Kelahmetoglu O, Cifci M, Tayfur V, Demir A, Guneren E. Comparison of free anterolateral thigh flaps and free muscle-musculocutaneous flaps in soft tissue reconstruction of lower extremity. *Microsurgery* 2010; 30: 24-31.
- [18] Celik N, Wei FC, Lin CH, Cheng MH, Chen HC, Jeng SF, Kuo YR. Technique and strategy in anterolateral thigh perforator flap surgery, based on an analysis of 15 complete and partial failures in 439 cases. *Plast Reconstr Surg* 2002; 109: 2211-2216.
- [19] Kang MJ, Chung CH, Chang YJ, Kim KH. Reconstruction of the lower extremity using free flaps. *Arch Plast Surg* 2013; 40: 575-583.
- [20] Reus WF, Colen LB, Stranker DJ. Tobacco smoking and complications in elective microsurgery. *Plast Reconstr Surg* 1992; 89: 490-494.
- [21] Perrot P, Bouffaut AL, Perret C, Connault J, Duteille F. Risk factors and therapeutic strategy after failure of free flap coverage for lower-limb defects. *J Reconstr Microsurg* 2010; 27: 157-162.
- [22] Pattani KM, Byrne P, Boahene K, Richmon J. What makes a good flap go bad? A critical analysis of the literature of intraoperative factors related to free flap failure. *Laryngoscope* 2010; 120: 717-723.
- [23] Serletti JM, Higgins JP, Moran S, Orlando GS. Factors affecting outcome in free-tissue trans-

Risk factors for free anterolateral thigh flap failure

- fer in the elderly. *Plast Reconstr Surg* 2000; 106: 66-70.
- [24] Hong JP, Shin HW, Kim JJ, Wei FC, Chung YK. The use of anterolateral thigh perforator flaps in chronic osteomyelitis of the lower extremity. *Plast Reconstr Surg* 2005; 115: 142-147.
- [25] Varey AH, Khan U. Soft-tissue reconstruction of open fractures of the lower limb: muscle versus fasciocutaneous flaps. *Plast Reconstr Surg* 2012; 130: 284-295.
- [26] Yazar S, Lin CH, Lin YT, Ulusal AE, Wei FC. Outcome comparison between free muscle and free fasciocutaneous flaps for reconstruction of distal third and ankle traumatic open tibial fractures. *Plast Reconstr Surg* 2006; 117: 2468-2475.
- [27] Arnold PG, Yugueros P, Hanssen AD. Muscle flaps in osteomyelitis of the lower extremity: a 20-year account. *Plast Reconstr Surg* 1999; 104: 107-110.
- [28] Lakhiani C, Lee MR, Saint-Cyr M. Vascular anatomy of the anterolateral thigh flap: a systematic review. *Plast Reconstr Surg* 2012; 130: 1254-1268.
- [29] Seth R, Manz RM, Dahan IJ, Nuara MJ, Meltzer NE, McLennan G, Alam DS. Comprehensive analysis of the anterolateral thigh flap vascular anatomy. *Arch Facial Plast Surg* 2011; 13: 347-354.
- [30] Kuo YR, Jeng SF, Kuo MH, Huang MN, Liu YT, Chiang YC, Yeh MC, Wei FC. Free anterolateral thigh flap for extremity reconstruction: clinical experience and functional assessment of donor site. *Plast Reconstr Surg* 2001; 107: 1766-1771.