

Original Article

Sinus tarsi approach with modified calcaneal plate for intra-articular calcaneus fractures

Guowei Huang*, Shan Wei*, Xuefeng Jiang

Department of Orthopedics, The Affiliated Jiangyin Hospital of Nantong University, Jiangyin City, Jiangsu Province, China. *Equal contributors and co-first authors.

Received September 20, 2017; Accepted October 30, 2017; Epub December 15, 2017; Published December 30, 2017

Abstract: Objective: To investigate the clinical efficacy of sinus tarsi approach with modified calcaneal plate for open reduction and internal fixation of intra-articular calcaneus fractures, in an effort to reduce the risk of wound complications. Methods: A total of 40 patients (48 feet) with closed Sanders type II (30 (62.5%) feet) and III (18 (37.5%) feet) calcaneal fractures, who were admitted to our hospital from June 2012 to December 2013, were enrolled in the study. According to Essex-Lopresti classification, there were 20 (41.7%) feet of tongue-type fracture and 28 (58.3%) feet of joint depression type. All the patients received surgical intervention by combining the sinus tarsi approach with modified calcaneal plate in our hospital. Böhler's angle and Gissane's angle were compared before and after surgery. The clinical results were evaluated according to the American Orthopaedic Foot and Ankle Society ankle-hindfoot scale (AOFAS), and the incidence of wound complications was recorded. The follow-up duration for all patients ranged from 12 to 22 months (mean 16.3 months). Results: Satisfactory restoration of Böhler's angle and Gissane's angle was obtained and no loss of reduction was found during the follow-up period. The final good and excellent rate of AOFAS score from was 87.5%, and no severe wound complications were observed. Conclusion: Sinus tarsi approach combined with a modified calcaneal plate is an effective method for the treatment of Sanders type II and III calcaneus fractures.

Keywords: Calcaneus fracture, internal fixation, plate fixation, sinus tarsi approach

Introduction

Calcaneal fractures, usually called comminuted intra-articular fractures, are the most common type of traumatic tarsal bone injuries occurred predominantly in young and middle-aged patients with severe dysfunction after treatment frequently [1]. Open reduction and internal fixation to restore posterior calcaneal facet and calcaneal geometric shape, in combination with early functional rehabilitation, has become a standard surgical method for the treatment of intra-articular calcaneal fractures. The extensile lateral L-shaped approach is the most widely used; however, high rate of wound complications remains a serious problem. In recent years, in order to obtain satisfactory reduction and fixation, and minimize soft tissue injuries and postoperative wound complications, much attention has been paid to minimally invasive treatment of calcaneal fractures [2-6].

In the present retrospective study, 48 intra-articular calcaneal fractures in 40 patients were operatively treated with modified calcaneal plate via sinus tarsi approach at our hospital from June 2012 to December 2013, and the outcomes of the operation were successful. Here we present the surgical approaches as follows.

Patients and methods

We reviewed 48 feet in 40 patients with closed calcaneus fracture. All were treated with open reduction and internal fixation via sinus tarsi approach with modified calcaneal plate in our hospital by a group of surgeons (G.H. and X.J.) from June 2012 to December 2013. The cohort included 32 (80%) males (38 feet) and 8 (20%) females (10 feet), with an average age of 36.5 (range from 18 to 58) years. Of all the patients in the group, 24 (60%) fell from a height, 12

Sinus tarsi approach with modified calcaneal plate

Table 1. Preoperative, postoperative angles and the angles at the last follow-up visit (n=48 feet, 40 patients)

	Böhler angle (°)	Gissane angle (°)
Preoperatively	6.10±12.9	105.1±8.9
Postoperatively	28.7±9.1	120.0±9.6
Last follow-up visit	29.1±9.0	118.7±8.8
F value	36.315	18.949
P value	0.000	0.000

(30%) were injured in a traffic accident, 4 (10%) had their foot injured by a heavy object falling down. For all cases, plain radiographs and preoperative CT scans were performed. According to the Essex-Lopresti classification, there were 20 (41.7%) feet with a tongue type fracture, and 28 (58.3%) feet with joint depression fractures. According to the Sanders classification, there were 30 (62.5%) feet with type II fracture and 18 (37.5%) feet with type III fracture. The mean duration of time from injury to surgery was 6.5 days (range from 4 to 12 days).

Preparation of internal fixation

Lateral calcaneal plates (TREU®, Tuttlingen, Germany) with the horizontal branch cut out were prepared as modified calcaneal plates, and used in this study. The implantation of modified calcaneal plate was performed via sinus tarsi approach. Double-headed cannulated screws (Newdeal®, Saint-Priest, France) were also used for fixation.

Surgical technique

As for surgery, each patient was placed in a lateral position on a radiolucent operating table. The procedures were performed by two surgeons (G.H. and X.J.), with the patient under spinal or general anesthesia. A straight incision toward the base of the fourth metatarsal was made 1 cm below the lateral malleolus. The sural nerve and peroneal tendon sheath were exposed and protected, and the dissection area was divided into anterior and posterior windows. The belly of extensor digitorum brevis was dissected sharply in the anterior window, revealing the calcaneocuboid joint, sinus tarsi and subtalar joint. The posterior window was mainly for plate implantation and screw fixation.

For the tongue-type fracture, the fragment was pried and elevated using Kirschner wires (K-wires) directly through the calcaneal tubercle, with the aid of a wire spreader. The K-wires were positioned percutaneously for temporary fixation after reduction. Bone graft substitute (β -tricalcium phosphate) was used in all cases to fill the void in the body after joint realignment. After reposition of the posterior fragment, the lateral wall fragment was manipulated and soft tissues were stripped in preparation for plate placement. Plate screws were inserted directly and percutaneously.

For the joint depression fractures, the collapsed facet fragments were elevated, after which screws were used to fix the plate.

In each case, the reduction was verified by means of intra-operative C-arm fluoroscopy, with direct inspection and manipulation on the joints. A drainage tube was used routinely, along with anatomic layer closure and bandaging with an ankle-foot positioning splint. After the operation, the drainage tube was removed in 24 to 48 hours, and a plaster cast was used for 2 weeks. Partial weight bearing activity was started 10 weeks after surgery, and this was followed by full weight bearing activity as tolerated, usually for 12 weeks after surgery.

Outcomes of interest

Wound complications were recorded. For postoperative evaluation of the reduction, Böhler's and Gissane's angles of the calcaneus were recorded by measuring radiographs of the patients before and after surgery. Since measurement error may be caused by different projection angles of the X-ray beam, loss of reduction was considered to present when a change $>5^\circ$ was observed [7]. Two of the treating surgeons (G.H. and X.J.) followed up all of the patients, measured and recorded the outcomes. The patients were radiologically evaluated at 12, 26, and 52 weeks postoperatively, with a clinical examination for signs of wound complications conducted at each follow-up visit. At the last follow-up visit, the American Orthopaedic Foot and Ankle Society (AOFAS) ankle-hind foot scale were used to quantify the subjective outcomes [8, 9].

Statistical analyses

The data was statistically analyzed using SPSS 11.0, and group comparison was conducted by

Sinus tarsi approach with modified calcaneal plate

Table 2. Comparison of excellent and good rate of foot function after calcaneal fracture operation

Type	Number of Cases	Excellent (%)	Good (%)	Excellent rate (%)	Poor (%)
Sanders type II	30	20 (66.67)	8 (26.67)	93.33	2 (6.67)
Sanders type III	18	8 (44.44)	6 (33.3)	77.78	4 (22.22)
Tongue fracture	20	14 (70)	6 (30)	100	0 (0)
Joint depression type fractures	28	14 (50)	8 (28.57)	78.57	6 (21.43)

repeated measures analysis of variance. The Student-Newman-Keuls test was used to compare the preoperative and postoperative Böhler's angle, Gissane's angle, and AOFAS scores before and after the operation. $P < 0.05$ was considered statistically significant.

Results

All patients were followed from 12 to 22 months (mean average 16.3 months). Disturbance of wound healing because of skin and soft tissue necrosis requiring operative intervention did not develop in any patient. One wound (2.1% of fractures, 2.5% of patients) displayed superficial skin dry necrosis after the operation, and it healed successfully with local wound care.

From surgery to fracture healing, all patients progressed to radiographic evidence of solid bony union in a mean period of 10.1 weeks (range from 8 to 16 weeks), and no loss of Böhler's or Gissane's angles of the calcaneus was found in any patients. Conversely, Böhler's and Gissane's angles of the calcaneus were significantly improved as a result of the operation ($P < 0.05$); while no significant differences were found during the follow-up period compared with the immediate postoperative measurements (Table 1).

The median AOFAS score was 84 (range from 68 to 99) at the last follow-up evaluation, corresponding to a good to excellent result in 42 (87.5%) of the fractures. Among the 30 Sanders II fractures, excellent scores were achieved in 20 (66.7%) fractures, good in 8 (26.7%), and fair in 2 (6.7%). Among the 18 Sanders type III fractures, excellent scores were achieved in 8 (44.4%) fractures, good in 6 (33.3%), and fair in 4 (22.2%). Among the 20 feet with tongue-type fractures, excellent scores were achieved in 14 (70.0%) fractures and good scores were achieved in 6 (30.0%). Among the 28 joint depression type fractures, excellent scores

were achieved in 14 (50.0%), good in 8 (28.6%), and fair in 6 (21.4%), as shown in Table 2. Typical cases are shown in Figures 1 and 2.

Discussion

Anatomical reduction, rigid fixation, and early exercise are the main methods in the treatment of intra-articular fractures. The conventional "L" shaped incision, which is still widely used, allows wide exposure to the calcaneal tuberosity, the lateral wall, subtalar joint and calcaneocuboid joints, and thus obtains satisfactory reduction and fixation using a large plate with no apparent loss of reduction and excellent outcomes in 60-85% of cases [10, 11]. It has been reported that 45% of the calcaneal blood supply is from the lateral wall [12, 13]. L-shaped approach needs more extensive dissection of lateral soft tissues, which may cause further damage to the blood supply of articular fragments; this could potentially lead to delayed fracture union or bone necrosis and early occurrence of osteoarthritis of the subtalar joint. Postoperatively, the incidence of wound complication has been reported from 0 to 33% [10, 14, 15]; large area of necrosis, calcaneal osteomyelitis and other catastrophic complications, have urged the physicians to look for safer and more effective surgical methods for the treatment of displaced calcaneal fractures.

The sinus tarsi approach is a minimally invasive approach for the treatment of calcaneal fractures, which can reduce the incidence of wound complications [16, 17]. Via this approach, the subtalar joint can be directly exposed and satisfactory reduction can be achieved [17, 18]. Numerous materials for fixation were used, including K-wires, screws, and dysmorphic small plates; hence, there is a lack of repetition or a definitive standard surgical technique [2, 16, 17, 19, 20]. K-wires and screws can only provide point-to-point fixation without rigidity and potential loss of reduction, while shaped small plates are not specifically designed for calcaneus fractures and defects still remain. Reliability of fixation and loss of reduction are main concerns regarding minimally invasive surgery. Some studies have also been per-

Sinus tarsi approach with modified calcaneal plate

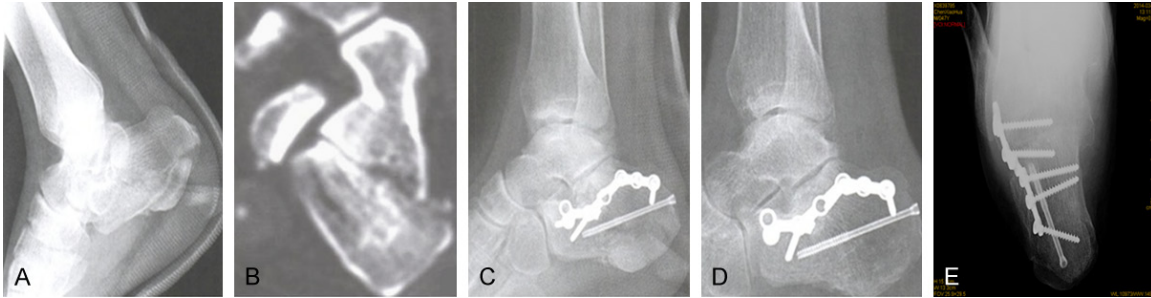


Figure 1. One case of intra-articular *tongue-type* calcaneus fractures treated via sinus tarsi approach with modified calcaneal plate (n=48 feet, 40 patients). A. Preoperative X-ray image of calcaneus. B. Preoperative CT image of Sanders III fracture. C. Postoperative X-ray image of calcaneus (satisfied fixation). D. X-ray image after fracture healing (no significant loss of reduction). E. Postoperative X-ray image of axial calcaneus with internal fixation.

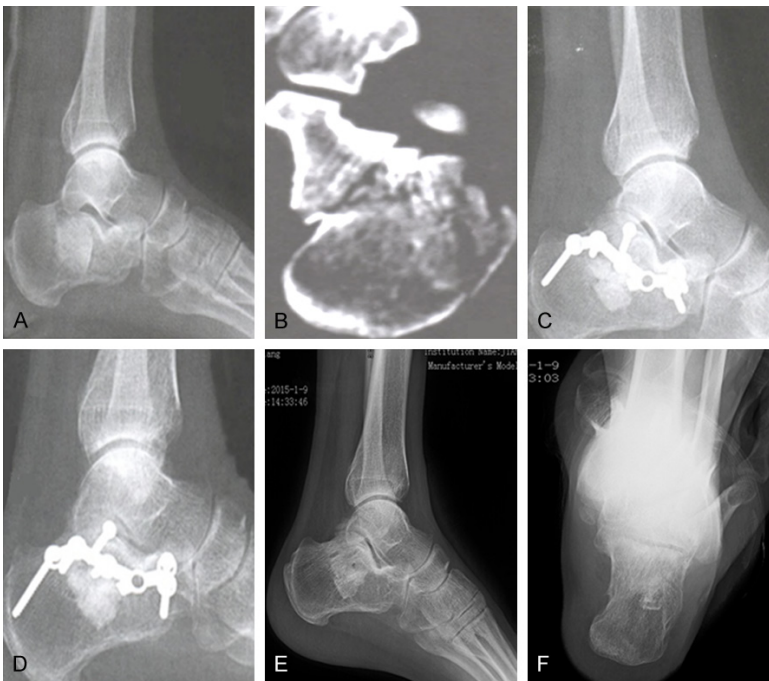

Figure 2. One case of intra-articular joint depression type calcaneus fractures treated via sinus tarsi approach with modified calcaneal plate (n=48 feet, 40 patients). A. Preoperative X-ray image of calcaneus. B. Preoperative CT film image of Sanders III fracture. C. Postoperative X-ray image of calcaneus (showed satisfied fixation). D. X-ray image after fracture healing (no significant loss of reduction). E, F. X-ray images after removal of internal fixation.



Figure 3. Modified calcaneal plate.

formed using regular calcaneal anatomic plate fixation via sinus tarsi approach or other minimally invasive approaches, but it also require extensive dissection of the lateral calcaneal soft tissues, and is difficult to position a plate properly [21, 22]. The modified plate used in our group of patients derives from a regular calcaneus plate. The narrow shape makes it easy to insert into the incision, and only a small area of soft tissue dissection is needed at the superior border of the lateral wall, to achieve a minimally invasive operation. The modified plate doesn't cover and depress the lateral wall directly, but can reduce and maintain the geometry of the calcaneus by ligamentotaxis, and promotes restoration of the width of the body and integrity of the lateral wall [23].

During the follow-up visit, we found no impingement of the lateral wall in any cases. As shown in **Figure 3**, the No. 1 and No. 2 holes in the plate are used for fixation of the anterior process and calcaneocuboid joint, and the No. 3 and No. 4 holes are positioned inferior to the articular surface with screws directly inserted into the sustentaculum tali in order to fix and support the posterior facet, and the No. 5, 6 and 7 holes are used for fixation of large tongue-type or tubercle fragments. By using the

Sinus tarsi approach with modified calcaneal plate

modified plate, the anterior process, calcaneal sustentaculum tali, posterior facet, and calcaneal tubercle are integrated and Böhler's and Gissane's angles are restored directly. But if the medial bone cortex is comminuted, the plate could not offer enough support medially and screws outside the plate are needed for augmentation. A locking plate may be the solution in such fractures, which is our direction for further study.

The 40 patients with 48 feet fractures that we observed in this report obtained satisfactory reduction during surgery and no apparent loss of reduction during the follow-up visit, and they did not experience wound healing complications, which suggested that the sinus tarsi incision and modified plate fixation method that we used can be effective. The surgical technique warranting mentioned five key points as follows. (1) Indications: Displaced intra-articular calcaneal fractures, including Sanders type II and III injuries, were successfully treated in our series of patients. For Sanders type IV fractures, we are not familiar with any reported surgical techniques that yield good clinical outcomes [8, 24, 25]. There were no patients with Sanders type IV fractures enrolled in this study. However, we think that the sinus tarsi approach can be used for the first stage of such injuries, because subtalar joint fusion is often needed for the second stage, and the use of a sinus tarsi incision may prevent excessive scarring of the lateral soft tissues. (2) Incision placement: The sinus tarsi incision was located 1 cm inferior to the lateral tip of the fibular malleolus and extended toward the base of the fourth metatarsal, and the incision needed to be appropriately extended when performing calcaneocuboid joint fixation. Care must be taken to identify the sural nerve or peroneal tendons that may get displaced superiorly due to the widening of the calcaneus after the fracture occurs. Do not open the peroneal tendon sheath, as bare tendon may increase the risk of wound complications. Careful subperiosteal dissection should be used along the edge of the lateral wall, and extensive stripping of the periosteum should be avoided. (3) Fracture reduction: In some case of Sanders type III injury, it was necessary to temporarily remove the lateral joint fragment to visualize the medial subtalar joint fragment. In such cases, retrograde K-wires could be used for temporary fixation of the facet fragments. After the reduction of posterior articular facet, fixation could be obtained using a 3.0 mm cannulated screw

inserted to the articular surface. However, overpressurizing should be avoided to prevent overlap. For patients with calcaneal varus, K-wires were drilled through the calcaneal tubercle and talus, and a K-wire spreader was used to correct varus. Screws were used percutaneously *along* the medial wall of the calcaneal tubercle or the long axis of calcaneus. (4) Bone graft: Artificial bone was used in all cases to support the posterior articular facet. (5) Postoperative treatment: Closed suction vacuum drainage was used with the tube through the muscle belly of extensor digitorum brevis, which could reduce the infection risk of the drainage tube. Conventional plaster was used postoperatively until the skin sutures were removed, and the plaster was applied to the foot dorsiflexed in a valgus position in order to reduce incision tension.

In this study, the small sample size is a limitation in terms of explaining the outcomes, although it was sufficient enough to enable us to observe significant differences in the radiographic angle measurements and the AOFAS scores. Though we found no severe soft tissue complications or loss of reduction; however, larger samples are needed to thoroughly explore the outcomes of the technique that we described, and the findings of this report could be useful in the development of such future investigations.

In conclusion, based on our observations of the patients described in this report, the sinus tarsi approach with modified calcaneal plate yields satisfactory exposure without lateral soft tissue complications, and provides fracture reduction and fixation that holds up over the healing phase.

Disclosure of conflict of interest

None.

Address correspondence to: Xuefeng Jiang, Department of Orthopedics, The Affiliated Jiangyin Hospital of Nantong University, No. 163 Shoushan Road, Jiangyin 214400, Jiangsu Province, China. Tel: +86-15961656699; Fax: +86-0510-86879000; E-mail: jiangxuefeng009@163.com

References

- [1] Rammelt S and Zwipp H. Calcaneus fractures: facts, controversies and recent developments. *Injury* 2004; 35: 443-461.

Sinus tarsi approach with modified calcaneal plate

- [2] Hospodar P, Guzman C, Johnson P and Uhl R. Treatment of displaced calcaneus fractures using a minimally invasive sinus tarsi approach. *Orthopedics* 2008; 31: 1112.
- [3] Kurozumi T, Jinno Y, Sato T, Inoue H, Aitani T and Okuda K. Open reduction for intra-articular calcaneal fractures: evaluation using computed tomography. *Foot Ankle Int* 2003; 24: 942-948.
- [4] Spagnolo R, Bonalumi M, Pace F and Capitani D. Calcaneus fractures, results of the sinus tarsi approach: 4 years of experience. *European Journal of Orthopaedic Surgery & Traumatology* 2010; 20: 37.
- [5] Sivakumar BS, Wong P, Dick CG, Steer RA, Tetsworth K. Arthroscopic reduction and percutaneous fixation of selected calcaneus fractures: surgical technique and early results. *J Orthop Trauma* 2014; 28: 569-76.
- [6] Wallin KJ, Cozzetto D, Russell L, Hallare DA and Lee DK. Evidence-based rationale for percutaneous fixation technique of displaced intra-articular calcaneal fractures: a systematic review of clinical outcomes. *J Foot Ankle Surg* 2014; 53: 740-743.
- [7] Weber M, Lehmann O, Sagesser D and Krause F. Limited open reduction and internal fixation of displaced intra-articular fractures of the calcaneum. *J Bone Joint Surg Br* 2008; 90: 1608-1616.
- [8] Kitaoka HB, Alexander IJ, Adelaar RS, Nunley JA, Myerson MS, Sanders M. Clinical rating systems for the ankle-hindfoot, midfoot, hallux, and lesser toes. *Foot Ankle Int* 1994; 15: 349-53.
- [9] Ibrahim T, Beiri A, Azzabi M, Best AJ, Taylor GJ, Menon DK. Reliability and validity of the subjective component of the American orthopaedic foot and ankle society clinical rating scales. *Journal of Foot & Ankle Surgery* 2007; 46: 65-74.
- [10] Benirschke SK and Sangeorzan BJ. Extensive intraarticular fractures of the foot. Surgical management of calcaneal fractures. *Clin Orthop Relat Res* 1993; 128-134.
- [11] Sanders R, Vaupel ZM, Erdogan M and Downes K. Operative treatment of displaced intra-articular calcaneal fractures: long-term (10-20 Years) results in 108 fractures using a prognostic CT classification. *J Orthop Trauma* 2014; 28: 551-563.
- [12] Andermahr J, Helling HJ, Rehm KE and Koebke Z. The vascularization of the os calcaneum and the clinical consequences. *Clin Orthop Relat Res* 1999; 212-218.
- [13] Borrelli J Jr, Lashgari C. Vascularity of the lateral calcaneal flap: a cadaveric injection study. *J Orthop Trauma* 1999; 13: 73-77.
- [14] Eastwood DM, Langkamer VG and Atkins RM. Intra-articular fractures of the calcaneum. Part II: open reduction and internal fixation by the extended lateral transcaneal approach. *J Bone Joint Surg Br* 1993; 75: 189-195.
- [15] Freeman BJ, Duff S, Allen PE, Nicholson HD and Atkins RM. The extended lateral approach to the hindfoot. Anatomical basis and surgical implications. *J Bone Joint Surg Br* 1998; 80: 139-142.
- [16] Kline AJ, Anderson RB, Davis WH, Jones CP and Cohen BE. Minimally invasive technique versus an extensile lateral approach for intra-articular calcaneal fractures. *Foot Ankle Int* 2013; 34: 773-780.
- [17] Schepers T and Patka P. Treatment of displaced intra-articular calcaneal fractures by ligamentotaxis: current concepts' review. *Arch Orthop Trauma Surg* 2009; 129: 1677-1683.
- [18] Nosewicz T, Knupp M, Barg A, Maas M, Bolliger L, Goslings JC and Hintermann B. Mini-open sinus tarsi approach with percutaneous screw fixation of displaced calcaneal fractures: a prospective computed tomography-based study. *Foot Ankle Int* 2012; 33: 925-933.
- [19] Gupta A, Ghalambor N, Nihal A and Trepman E. The modified Palmer lateral approach for calcaneal fractures: wound healing and postoperative computed tomographic evaluation of fracture reduction. *Foot Ankle Int* 2003; 24: 744-753.
- [20] Abdelazeem A, Khedr A, Abousayed M, Seifeldin A and Khaled S. Management of displaced intra-articular calcaneal fractures using the limited open sinus tarsi approach and fixation by screws only technique. *Int Orthop* 2014; 38: 601-606.
- [21] Zhang T, Su Y, Chen W, Zhang Q, Wu Z, Zhang Y. Displaced intra-articular calcaneal fractures treated in a minimally invasive fashion: longitudinal approach versus sinus tarsi approach. *J Bone Joint Surg Am* 2014; 96: 302-9.
- [22] Cao L, Weng W, Song S, Mao N, Li H, Cai Y, Zhou Q Jr, Su J. Surgical treatment of calcaneal fractures of Sanders type II and III by a minimally invasive technique using a locking plate. *J Foot Ankle Surg* 2015; 54: 76-81.
- [23] Schepers T and Patka P. Treatment of displaced intra-articular calcaneal fractures by ligamentotaxis: current concepts' review. *Arch Orthop Trauma Surg* 2009; 129: 1677-1683.
- [24] Berry GK, Stevens DG, Kreder HJ, McKee M, Schemitsch E and Stephen DJ. Open fractures of the calcaneus: a review of treatment and outcome. *J Orthop Trauma* 2004; 18: 202-206.
- [25] Huang PJ, Huang HT, Chen TB, Chen JC, Lin YK, Cheng YM and Lin SY. Open reduction and internal fixation of displaced intra-articular fractures of the calcaneus. *J Trauma* 2002; 52: 946-950.