

## Case Report

# An extremely rare case report: small intestine diffuse lymphangiomas with jejunum focal cavernous hemangioma in a 51-year-old female suffering from melena

Liwei Pang, Jing Kong

Department of Biliary and Minimally Invasive Surgery, China Medical University Shengjing Hospital Shenyang, Liaoning, China

Received May 14, 2017; Accepted October 12, 2017; Epub November 15, 2017; Published November 30, 2017

**Abstract:** Lymphangiomas, one kind of benign tumor, usually arise during infancy, and is uncommon for adults and even more uncommon in small intestine. Diffuse lymphangiomas of small intestine, also called small intestine lymphangiomas, are even rarer and it is so rare that it has seldom been reported in the world. Thus we report a case of diffuse lymphangiomas of small intestine in a middle-aged female who presented with fatigue, anemia and melena, and underwent partial small intestine resection so that exploratory laparotomy was performed. Histological examination revealed diffuse lymphangiomas of small intestine with jejunum focal cavernous hemangioma and there was the appearance of multiple abdominal lymphangioma with calcification.

**Keywords:** Lymphangiomas, hemangioma, small intestine

### Introduction

Lymphangiomas, as a rare benign tumor, usually arise during infancy and can occur anywhere in the skin. Small intestine diffuse lymphangiomas is extremely rare among adults so that there hardly is no relevant article about it in recent 10 years. Also, cavernous hemangiomas of the small intestine are rare and it accounts for 5% to 10% of all benign diseases. As a matter of fact, cavernous hemangiomas of the small intestine are simply a kind of vascular proliferative disease rather than a real tumor. Both of those are rare but they did occur in a Chinese woman. Therefore we report a case of diffuse lymphangiomas of small intestine with jejunum focal cavernous hemangioma as has never been reported before.

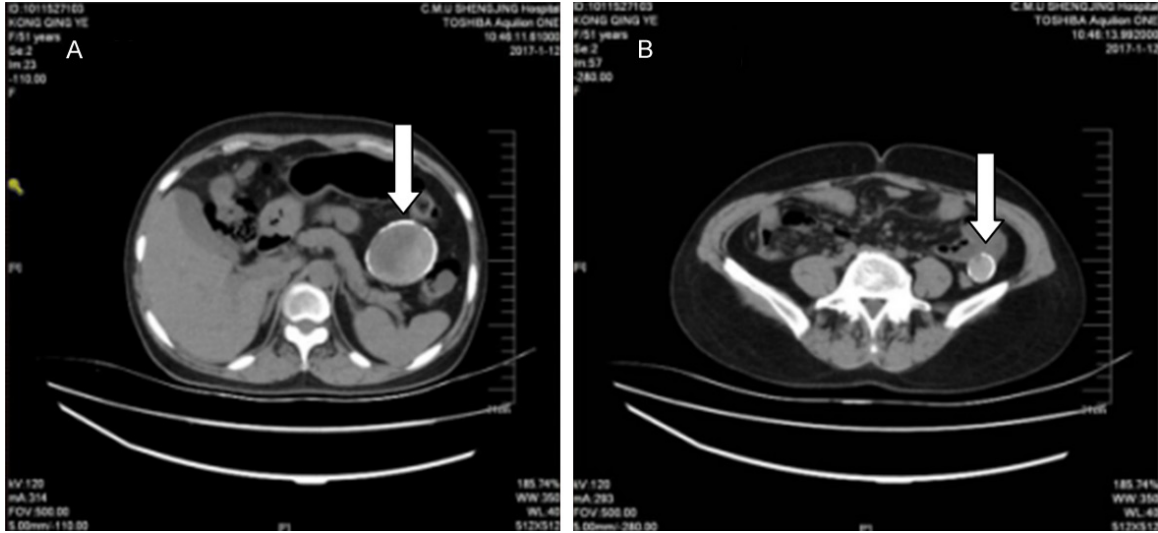
### Case report

The patient, a 51-year-old female with fatigue and ½-year history of anemia, went to a local hospital. CT scan reported multiple abdominal cysts with calcification and gastroscopy indi-

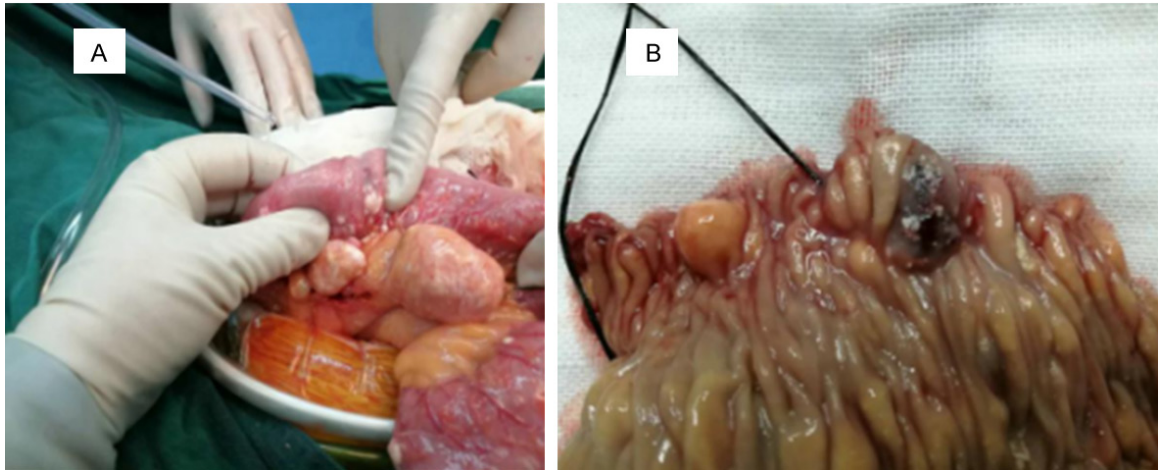
cated chronic superficial gastritis and gastric polyps. She didn't care about it at that time. But the above symptoms increased in recent ten days and severe melena appeared. Thus she went to the local hospital again and the hemoglobin level was 96 g/L after the transfusion of red blood cells at 1200 ml, diagnosed as anemia. As a result, she came to our hospital and her positive signs were as below: melena, left upper quadrant pain and anemia. The following levels were found in the blood via blood test: leukocyte  $3.26 \times 10^9/L$ , erythrocyte  $3.5 \times 10^9/L$ , hemoglobin 99 g/L. The levels of tumor markers (CEA, AFP, CA199), routine urinalysis as well as other blood tests were within normal limits.

The enhanced computed tomography scan (2017-01-12) scan of our hospital reported multiple abdominal cysts with calcification, remaining to be determined (See **Figure 1**). We considered it to be gastrointestinal stroma tumors (GIST) before operation. It was a pity that we didn't carry out enteroscopy, gastroscopy and stool occult blood test on the patient

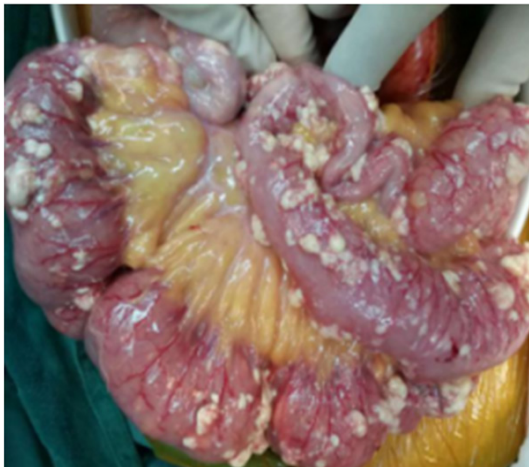## A case of small intestine diffuse lymphangiomatosis



**Figure 1.** Enhanced computed tomography. A. The biggest cyst with calcification; B. The other hard lesion.



**Figure 2.** A. The finger position suspecting hemangioma; B. Partial small intestine is cut off, the suture suspects hemangioma.

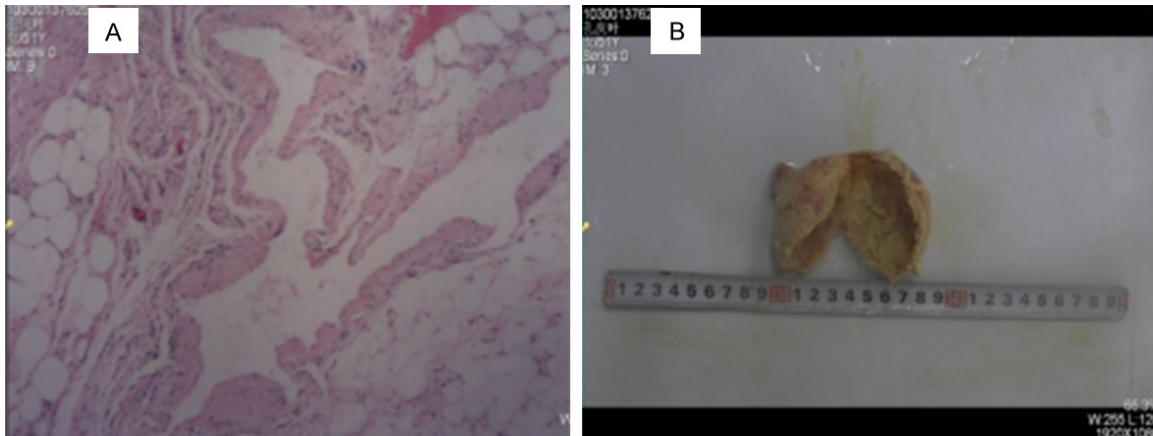


**Figure 3.** A lot of white cysts pervading the whole small intestine especially jejunum.

out of her being too eager to have an operation. She had a previous history of pulmonary tuberculosis.

On January 16, 2017, exploratory laparotomy was performed and a lot of white cysts were found pervading the whole small intestine, especially the jejunum. Moreover, exploratory laparotomy showed that chyliform ascites was about 100 ml. We had explored the whole small intestine and detected an appropriate 1.5 cm dark red occupying hemangioma 140 cm

## A case of small intestine diffuse lymphangiomatosis



**Figure 4.** A. Histological section revealed the proliferation and expansion of lymph-vessel through whole intestinal wall, especially submucosal and serosa, with calcification; B. The biggest cyst, hard, contains white chyliform fluid.

away from the ligament of Treitz, which was considered as the site of bleeding (See **Figure 2**). Apart from that, we also found multiple cysts in small intestine, two of which were big and hard while the rest ones were soft. All of those multiple cysts in small intestine contained chyliform ascites (See **Figure 3**). We cut off the intestinal segment about 15 cm and found cysts of varying sizes distributed both inside and outside the small intestine. Histological examination revealed diffuse lymphangiomas of small intestine with jejunum focal cavernous hemangioma and there was the appearance of multiple abdominal lymphangioma with calcification (See **Figure 4**). The hemoglobin level of the patient was 92 g/L after operation and we then conducted anti-inflammatory (using Sulperazone for 4 days) and rehydration therapy (using Compound Amino Acid Injection (I5AA), Fat Emulsion Injection and appropriate glucose for 5 days) toward her. On the fourth day after operation, she reported an uncomfortable state of exhaustion. One day later, we provided her a liquid diet. She recovered and discharged from hospital on the eighth day after operation and no intestinal leakage, obstruction and bleeding occurred. By far (2017-07-13), melena or obstruction had not reappeared yet so that she could deal with normal work on her own. However, small cysts still remained in her abdomen.

### Discussion

The pathogenesis of lymphangiomatosis is not yet known. And there is no relevant article about small intestine diffuse lymphangioma-

sis in recent 10 years. Only a few scattered, solitary lymphangiomas was reported. Some authors hold that it may originate from the lymphoid tissues during the embryonic period because the hyperplasia of residual lymphoid tissues caused lymphatic expansion so as to further result in lymphangiomatosis [1]. Other authors deem that it may be a result of the connectivity of immature interstitial portion of lymphatic vessels with the venous system [2]. Both of these two theories can explain why lymphangiomatosis usually arises during infancy. Lymphangiomatosis can be classified four main types: (1) capillary lymphangioma, (2) cavernous lymphangioma, (3) cystic lymphangioma, (4) hemo-lymphangiomatosis [3]. This kind of classification is based on different phases of the same disease. Lymphangiomatosis and hemangioma are both benign tumors and they can occur at the same time. This case is right a good example. The common symptoms of small intestine lymphangiomatosis mainly include the below ones: bleeding (especially with hemangioma), intestinal obstruction (the most common), abdominal pain (depending on the size and location of the tumor) [4].

As lymphangiomatosis is the benign hyperplasia of lymphoid tissues, some authors suggest that asymptomatic lymphangiomatosis call for regular observation [5]. However, once symptoms like bleeding, obstruction, etc. occur, an operation is quite necessary to cut off limited number of cysts. Moreover, the prognosis is good as well. But the tricky problem is that small intestinal lymphangiomatosis has a very high recurrence rate that can even

## A case of small intestine diffuse lymphangiomas

approach 100% [6], which needs to be dealt with urgently.

Abdominal CT scan and MRI, though lack of specificity, are still necessary. Lymphangiomas may present with cysts of varying sizes which contain intracystic debris or hemorrhage [7]. MRI is advantageous for detecting fluid-filled cystic lesions as it may reveal the cystic nature of cavernous lymphangiomas that appear as solid masses on CT [8]. With the development of capsule endoscopy and small intestinal endoscope, it has tremendous value in the small intestinal lymphangiomas diagnosis.

Lymphangiomas is a rare disease that usually has no specific clinical performance, so the doctor can easily succumb to misdiagnosis and missed diagnosis. A complete medical history, careful physical examination and assistant examination are necessary [9]. Complete surgical resection should be performed when necessary. We report this rare case with the aim to improve your understanding of this disease.

### Disclosure of conflict of interest

None.

**Address correspondence to:** Jing Kong, Department of Biliary and Minimally Invasive Surgery, China Medical University Shengjing Hospital Shenyang, No. 36, San Hao Street, Shenyang 110004, Liaoning, China. Tel: 18940258158; E-mail: kongjing-1998@163.com

### References

- [1] Paal E, Thompson LD and Heffess CS. A clinicopathologic and immunohistochemical study of ten pancreatic lymphangiomas and a review of the literature. *Cancer* 1998; 82: 2150-2158.
- [2] Huang Q, Wang XM, Liu YL, Wang ZF, Peng T. Clinical analysis of lymphangioma in small intestine. *Chin J Gastroenterol Hepatol* 2015; 24: 83-87.
- [3] Kosmidis I, Vlachou M, Koutroufinis A and Filiopoulos K. Hemolymphangioma of the lower extremities in children: two case reports. *J Orthop Surg Res* 2010; 5: 56.
- [4] de Vries JJ, Vogten JM, de Bruin PC, Boerma D, van de Pavoordt HD and Hagendoorn J. Mesenteric lymphangiomas causing volvulus and intestinal obstruction. *Lymphat Res Biol* 2007; 5: 269-273.
- [5] Kochman ML, Wiersema MJ, Hawes RH, Canal D and Wiersema L. Preoperative diagnosis of cystic lymphangioma of the colon by endoscopic ultrasound. *Gastrointest Endosc* 1997; 45: 204-206.
- [6] Goh BK, Tan YM, Ong HS, Chui CH, Ooi LL, Chow PK, Tan CE and Wong WK. Intra-abdominal and retroperitoneal lymphangiomas in pediatric and adult patients. *World J Surg* 2005; 29: 837-840.
- [7] Hwang SS, Choi HJ and Park SY. Cavernous mesenteric lymphangiomas mimicking metastasis in a patient with rectal cancer: a case report. *World J Gastroenterol* 2009; 15: 3947-3949.
- [8] Gabata T, Terayama N, Yamashiro M, Takamatsu S, Yoshida K, Matsui O, Usukura M, Takeshita M and Minato H. Solid serous cystadenoma of the pancreas: MR imaging with pathologic correlation. *Abdom Imaging* 2005; 30: 605-609.
- [9] Lin RY, Zou H, Chen TZ, Wu W, Wang JH, Chen XL, Han QX. Abdominal lymphangiomas in a 38-year-old female: case report and literature review. *World J Gastroenterol* 2014; 20: 8320-8324.