

## Original Article

# The effects of platelet-rich plasma on wound healing in rats

Cihad Tatar<sup>1</sup>, Husnu Aydin<sup>2</sup>, Tamer Karsidag<sup>3</sup>, Soykan Arikan<sup>1</sup>, Fevziye Kabukcuoglu<sup>4</sup>, Ozan Dogan<sup>5</sup>, Aylin Bekem<sup>6</sup>, Ahmet Unal<sup>6</sup>, Ishak Sefa Tuzun<sup>7</sup>

<sup>1</sup>Department of General Surgery, Istanbul Training and Research Hospital, Istanbul, Turkey; <sup>2</sup>Department of General Surgery, School of Medicine, Erciyes University, Kayseri, Turkey; <sup>3</sup>Department of General Surgery, School of Medicine, Acibadem University, Istanbul, Turkey; <sup>4</sup>Department of Patology, Sisli Etfal Training and Research Hospital, Istanbul, Turkey; <sup>5</sup>Department of Obstetrics and Gynecology, Düzce Ataturk State Hospital, Duzce, Turkey; <sup>6</sup>Department of Metallurgical and Materials Engineering, Yildiz Technical University, Istanbul, Turkey; <sup>7</sup>Department of General Surgery, School of Medicine, Kemerburgaz University, Istanbul, Turkey

Received September 5, 2016; Accepted March 12, 2017; Epub May 15, 2017; Published May 30, 2017

**Abstract:** Background: Wound healing follows a predictable course of overlapping phases, which involve cellular and biochemical events: (a) hemostasis and inflammation, (b) proliferation and (c) maturation and remodeling. Platelet Rich Plasma (PRP) is obtained by the blood from the patient being concentrated using different techniques. In the light of this basic information, platelet rich plasma (PRP) is used in many areas, especially orthopedic, oral and maxillofacial, dental, ophthalmic, plastic and reconstructive surgeries. In this experimental study performed on rats, the effects of PRP in wound healing were investigated. Methods: The study included 24 male Wistar Albino rats. The animals were divided into three groups, each consisting of 8 animals. Any treatment was not given for defects created in Group 1 and it formed the control group. PRP was applied topically on lesion in Group 2. PRP was injected on the lesion in Group 3. Results: Angiogenesis increased with the topical application, and the tissue durability increased with the intralesional injection. Conclusion: We can state that PRP had positive effects on the wound healing, the angiogenesis increased with the topical application, and the tissue durability increased with the intralesional injection. We believe that there is a need for new publications on this subject.

**Keywords:** Platelet-rich plasma, rats, wound healing

## Introduction

Wound healing follows a predictable course of overlapping phases, which involve cellular and biochemical events: (a) hemostasis and inflammation, (b) proliferation and (c) maturation and remodeling. Hemostasis occurs before the inflammatory phase and initiates inflammation by chemotactic factors released from the wound site. As a result of the contact of platelets with the subendothelial collagen together with the disruption of tissue integrity, platelets aggregate, degranulate and eventually the coagulation cascade starts. Multiple wounds healing agents such as platelet-derived growth factor (PDGF), transforming growth factor- $\beta$  (TGF $\beta$ ), platelet activating factor (PAF) are secreted from platelet  $\alpha$  granules, platelet activating factor (PAF), fibronectin and serotonin. A fibrin clot plays a role as a scaffold for the migration of inflammatory cells such as polymorphonuclear leukocytes (PMNL, neutrophils)

and monocytes to the wound in addition to providing hemostasis. The growth factors which are activated by platelets have an impact on the whole process of wound healing [1]. Platelet Rich Plasma (PRP) is obtained by the blood from the patient being concentrated using different techniques.

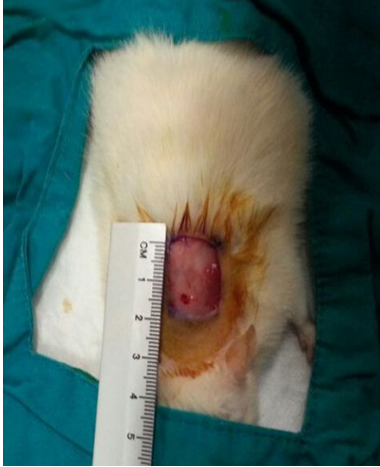In the light of this basic information, platelet rich plasma (PRP) is used in many areas, especially orthopedic, oral and maxillofacial, dental, ophthalmic, plastic and reconstructive surgeries [2-8]. In this experimental study performed on rats, the effects of PRP in wound healing were investigated.

## Material and methods

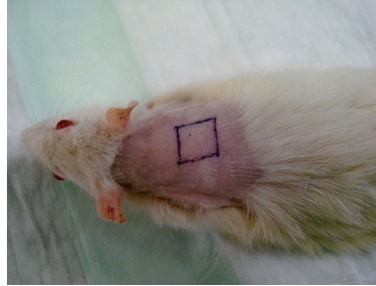
### Animals

The study included 24 male Wistar Albino rats. All animals were monitored in standard labora-

## The effects of PRP on wound healing



**Figure 1.** Creating full-thickness skin defects on the backs of the animals.



and also sufficient food and water were given. The backs of the rats were used as a wound surface in order for the animals not to damage the wound. All rats were kept in separate cages to prevent any harm to each other.

### *Creation of the wound*

The animals were placed under anesthesia by intramuscular ketamine hydrochloride injection (50 mg/kg) and their backs were also shaved with an electric razor tool. All surgical procedures were performed under sterile conditions.

After antiseptics were provided with povidone iodine, 1.5 × 1.5 cm full-thickness skin defects were created on the backs of the animals by sterile holes covers and hemostasis was achieved by making pressure with sterile gauze bandages (**Figure 1**). Then the wounds were allowed to heal secondarily which may last for 30 days.

### *Preparation of PRP*

Platelet-rich plasma was obtained during sacrificing same-sex rats used as a control group of another study. Total approximately 50 cc of blood was taken from 8 rats in sterile conditions. 2 cc of blood was taken into an EDTA tube for the WBC and PLT counts. The remaining blood was made platelet rich plasma with the method described by Okuda et al. [9]. After PRP was obtained, 2 cc of blood was taken again into an EDTA tube for the WBC and PLT counts.

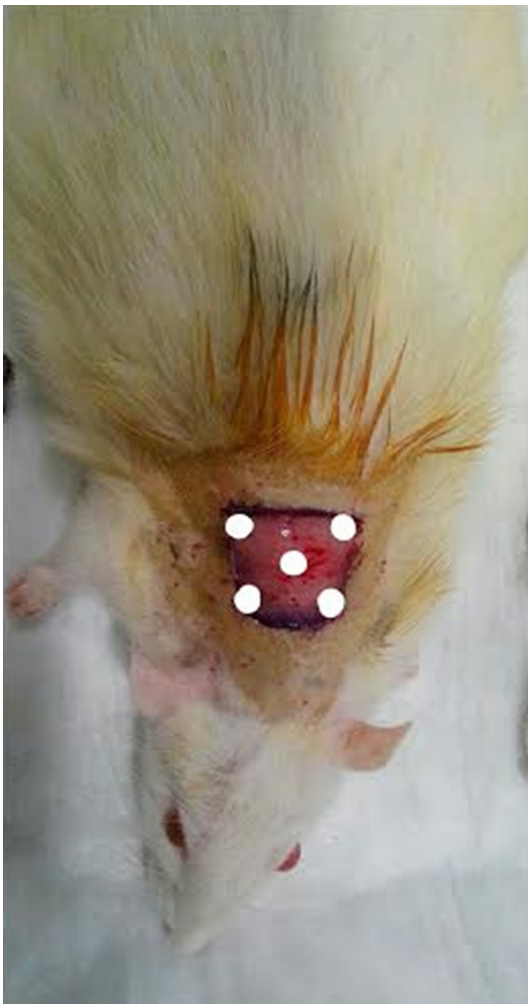### *Treatment*

The animals were divided into three groups, each consisting of 8 animals.

Any treatment was not given for defects created in Group 1 and it formed the control group. PRP was applied as a single topical 250 µl on lesion areas in Group 2. PRP was injected with 31 gauge needle as a single intradermal 250 µl (50 µl for each) on 5 zones (4 corners and 1 center) on the square-shaped lesions in Group 3 (**Figure 2**).

### *Histopathological examination*

Full-thickness cylindrical biopsies with a 2 mm diameter were taken with disposable punch




**Figure 2.** PRP was injected on 5 zones (4 corners and 1 center) on the square-shaped lesions.

tory conditions. They were maintained on 12-hour light: 12-hour dark cycles. 17-25°C temperature and 30% humidity were provided

# The effects of PRP on wound healing

**Table 1.** Histopathological parameters

Score	Re-epithelialization	Granulation tissue deposition	Collagen deposition	Inflammatory cell	Angiogenesis
0	No	No or immature	No	No	No
1	Partial	Small amount	Small amount	Small amount	Less than 5 vessels
2	Completed immature	Moderately mature	Moderate	Moderate	6-10 vessels
3	Completed mature	Mature	Abundant	Abundant	More than 10 vessels



**Figure 3.** Mechanical tensile test.

biopsy tool for microscopic examination on the 7th, 14th and 21st postoperative days. All surgical specimens were examined under a light microscope and stained with hematoxylin-eosin (HE) by the same pathologist. The analysis included re-epithelialization, granulation tissue deposition, collagen deposition, an inflammatory cell and angiogenesis parameters (**Table 1**). All surgical specimens were examined by the same pathologist without knowledge of the groups' features.

### *Mechanical tensile test*

In order to measure tensile strength, 30 × 5 mm strip-shaped skin was excised from the incision scars as the scar tissue remaining in the center on the 30th postoperative day after sacrificing subjects. The tissue samples were kept in physiological saline. Tensile strength measurements were made within 6 hours following sample receipt.

Tensile strength tests were made in the Composite Materials Laboratory of Metallurgy & Materials Engineering Department of Yildiz Technical University. It was performed using a 500 N (~50 kg) load cell by Mares brand universal tensile machine with a capacity of 20 kN.

The tissue strips were placed on tensile machine. The load was applied to the sample by fixing lower jaw and moving upper jaw up. Newtons per square millimeter was calculated at the time of rupture of the strips and was expressed in the form of megapascal ( $\text{N}/\text{mm}^2 = \text{MPa}$ ) (**Figure 3**). Stress-strain graphics were drawn with the help of software. Moreover, values that are known as modulus of elasticity (E-mode) were obtained by taking the slope of the stress-strain curve (**Figure 4**). E-mode value was used to measure the tissue durability.

Protocol was approved by the committee for animal research and the study strictly conformed to the animal experiment guidelines of the Committee for Human Care.

### *Statistical analysis*

SPSS 15.0 for Windows was used for statistical analysis. Percentage was used for categorical variables; and mean ± standard deviation and median were used for numerical variables. The One-Way ANOVA test or the Kruskal-Wallis test was performed according to whether the comparisons of multiple independent groups on quantitative variables were normally distributed or not. The Tukey HSD test for parametric test and the Mann-Whitney U test for the non-parametric test were performed in subgroup analyzes and then they were interpreted with the Bonferroni correction. The comparisons of multiple dependent groups were made with the Friedman test for ordinal variables. Subgroup analyzes were made by the Wilcoxon test and then they were interpreted with the Bonferroni correction. The alpha level (the threshold level of statistical significance) was considered as  $P < 0.05$ .

### **Results**

The number of PLT was determined as  $42 \times 10^3/\text{mm}^3$  in complete blood count made with

## The effects of PRP on wound healing

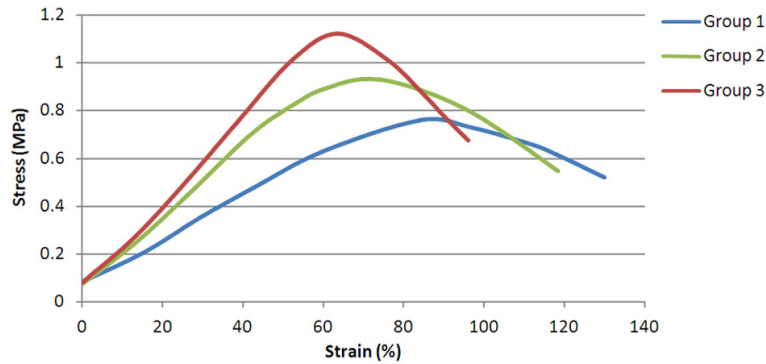


Figure 4. Stress-strain curve.

blood samples taken from rats. The number of PLT was determined as  $1127 \times 10^3/\text{mm}^3$  in the sample obtained after the preparation of PRP. It was found that the platelet count in the obtaining plasma was increased approximately 8-fold. None of the rats developed wound infection during the healing period.

In the groups, biopsy scores on the 7th, 14th and 21st days were shown in **Tables 2, 3** and also, tensile test results which were made by totally excising the scar area on the 30th day were summarized on **Figure 4**.

### Re-epithelialization

While re-epithelialization was observed in none of the animals on the 7th day, partial re-epithelialization was found to be respectively 4 (50%) animals in the Group 1, 3 (37.5%) animals in the Group 2 and 5 (62.5%) animals in the Group 3 on the 14th day. Re-epithelialization completed respectively in 3 (37.5%) animals the Group 1, 3 (37.5%) animals in the Group 2 and 5 (62.5%) animals on the 21st day but was observed to be immature. Statistically, a significant increase in re-epithelialization was observed in all groups ( $P < 0.001$ ). However, there was no a statistically significant difference between the groups in terms of re-epithelialization ( $P > 0.05$ ).

### Granulation tissue

It was observed that a small amount of granulation tissue formed respectively in 8 (100%) animals in the Group 1, 7 (87.5%) animals in the Group 2 and 7 (87.5%) animals in the Group 3 on the 7th day, moderately mature granulation

tissue formed respectively in 8 (100%) animals in the Group 1, 7 (87.5%) animals in the Group 2 and 7 (87.5%) animals in the Group 3 on the 14th day and mature granulation tissue formed in all the animals on the 21st day. The increase in the granulation tissue was statistically significant for all groups ( $P < 0.001$ ). However, there was no a statistically significant difference between the groups ( $P > 0.05$ ).

### Collagen accumulation

While collagen accumulation was observed in none of the animals on the 7th day, a small amount of collagen deposition occurred respectively in 6 (75%) animals in the Group 1, 8 (100%) animals in the Group 2 and 8 (87.5%) animals in the Group 3 on the 14th day. Moderate collagen deposition occurred respectively in 3 (37.5%) animals the Group 1, 2 (25%) animals in the Group 2 and 4 (50%) animals on the 21st day. The increase in the collagen deposition was statistically significant for all groups ( $P < 0.001$ ). However, there was no a statistically significant difference between the groups ( $P > 0.05$ ).

### Inflammatory cell

It was observed that there were a moderate amount of inflammatory cells, respectively in 5 (62.5%) animals in the Group 1, 6 (75%) animals in the Group 2 and 5 (62.5%) animals in the Group 3 on the 7th day, there were a few of inflammatory cells respectively in 5 (62.5%) animals in the Group 1, 5 (62.5%) animals in the Group 2 and 5 (62.5%) animals in the Group 3 on the 14th day but there were no inflammatory cells, respectively in 5 (62.5%) animals in the Group 1, 5 (62.5%) animals in the Group 2 and 5 (62.5%) animals in the Group 3 on the 21st day. The reduction in the inflammatory cells was statistically significant for all groups ( $P < 0.001$ ). However, there was no a statistically significant difference between the groups ( $P > 0.05$ ).

### Angiogenesis

On the 7th day, it was observed that the number of vessels was less than 5 in 6 (75%) ani-

## The effects of PRP on wound healing

**Table 2.** Histopathological examination scores

	Day		Group 1		Group 2		Group 3	
			n	%	n	%	n	%
Reepithelialization	7	No	8	100	8	100	8	100
	14	No	4	50.0	4	50.0	2	25.0
		Partial	4	50.0	3	37.5	5	62.5
		Completed immature	0	0.0	1	12.5	1	12.5
	21	Partial	5	62.5	4	50.0	2	25.0
		Completed immature	3	37.5	3	37.5	5	62.5
Completed mature		0	0.0	1	12.5	1	12.5	
Granulation tissue deposition	7	No or immature	0	0.0	1	12.5	1	12.5
		Small amount	8	100	7	87.5	7	87.5
	14	Small amount	0	0.0	1	12.5	1	12.5
		Moderately mature	8	100	7	87.5	7	87.5
	21	Mature	8	100	8	100	8	100
	Collagen deposition	7	No	8	100	8	100	8
14		No	1	12.5	0	0.0	0	0.0
		Small amount	6	75.0	8	100	8	100
		Moderate	1	12.5	0	0.0	0	0.0
21		Small amount	5	62.5	6	75.0	4	50.0
		Moderate	3	37.5	2	25.0	4	50.0
Inflammatory cell	7	Moderate	5	62.5	6	75.0	5	62.5
		Abundant	3	37.5	2	25.0	3	37.5
	14	Small amount	5	62.5	5	62.5	5	62.5
		Moderate	2	25.0	3	37.5	3	37.5
		Abundant	1	12.5	0	0.0	0	0.0
	21	No	5	62.5	5	62.5	5	62.5
Small amount		2	25.0	3	37.5	3	37.5	
Moderate		1	12.5	0	0.0	0	0.0	
Angiogenesis	7	Less than 5 vessels	6	75.0	0	0.0	6	75.0
		6-10 vessels	2	25.0	5	62.5	2	25.0
		More than 10 vessels	0	0.0	3	37.5	0	0.0
	14	Less than 5 vessels	0	0.0	0	0.0	1	12.5
		6-10 vessels	5	62.5	3	37.5	7	87.5
		More than 10 vessels	3	37.5	5	62.5	0	0.0
	21	Less than 5 vessels	0	0.0	0	0.0	0	0.0
		6-10 vessels	2	25.0	2	25.0	2	25.0
		More than 10 vessels	6	75.0	6	75.0	6	75.0

mals but ranged from 6 to 10 in 2 animals in both Group 1 and 3. It was observed that the number of vessels ranged from 6 to 10 in 5 (62.5%) animals but was more than 10 in 3 (37.5%) animals in the Group 2. On the 14th day, it was observed that the number of vessels ranged from 6 to 10 respectively in 5 (62.5%) animals in the Group 1, 3 (37.5%) animals in the Group 2 and 7 (87.5%) animals in the Group 3. However, on the 21st day, it was

observed that the number of vessels was more than 10 in 6 (75%) animals in the Group 1, 5 (62.5%) animals in the Group 2 and 6 (75%) animals in the Group 3. The increase in the angiogenesis was statistically significant for all groups ( $P < 0.001$ ). Moreover, the angiogenesis on the 7th and 14th day in the Group 2 was statistically significantly higher than that in the other groups (respectively,  $P < 0.001$ ,  $P = 0.022$ ) (**Table 4; Figure 5**).

## The effects of PRP on wound healing

**Table 3.** Histopathological examinations and mechanical tensile test results

	Day	Group 1			Group 2			Group 3			P <sub>∞</sub>
		Ort.	SD	Med	Ort.	SD	Med	Ort.	SD	Med	
Reepithelialization	7	0.00	0.00	0	0.00	0.00	0	0.00	0.00	0	1.000
	14	0.50	0.53	0.5	0.63	0.74	0.5	0.88	0.64	1	0.490
	21	1.38	0.52	1	1.63	0.74	1.5	1.88	0.64	2	0.298
	P~	0.001			0.001			0.001			
Granulation tissue Deposition	7	1.00	0.00	1	0.88	0.35	1	0.88	0.35	1	0.563
	14	2.00	0.00	2	1.88	0.35	2	1.88	0.35	2	0.593
	21	3.00	0.00	3	3.00	0.00	3	3.00	0.00	3	1.000
	P~	<0.001			<0.001			<0.001			
Collagen Deposition	7	0.00	0.00	0	0.00	0.00	0	0.00	0.00	0	1.000
	14	1.00	0.53	1	1.00	0.00	1	1.00	0.00	1	1.000
	21	1.38	0.52	1	1.25	0.46	1	1.50	0.53	1.5	0.600
	P~	0.001			0.001			0.001			
Inflammatory cell	7	2.38	0.52	2	2.25	0.46	2	2.38	0.52	2	0.836
	14	1.50	0.76	1	1.38	0.52	1	1.38	0.52	1	0.977
	21	0.50	0.76	0	0.38	0.52	0	0.38	0.52	0	0.977
	P~	<0.001			<0.001			<0.001			
Angiogenesis	7	1.25	0.46	1	2.38	0.52	2	1.25	0.46	1	0.001
	14	2.38	0.52	2	2.63	0.52	3	1.88	0.35	2	0.022
	21	2.75	0.46	3	2.75	0.46	3	2.75	0.46	3	0.134
	P~	0.001			0.001			0.001			
Mechanical Tensile Test	E-mod	0.79	0.23	0.8	1.02	0.24	0.9	1.38	0.30	1.3	0.001

∞Independent group analysis; ~Dependent group analysis. One-Way ANOVA or Kruskal-Wallis test.

**Table 4.** Subgroup analysis

	Angiogenesis* Day 7	Angiogenesis* Day 14	Tensile Test** E-mod
Group 1 vs. Group 2	0.002	0.333	0.213
Group 1 vs. Group 3	1.000	0.044	<0.001
Group 2 vs. Group 3	0.002	0.008	0.024

Post Hoc Test \*Mann Whitney U Bonferroni Correction P<0.017 \*\*Tukey HSD Test.

### Mechanical tensile test

The mean of E-mode had a statistically significant difference in between the groups in mechanical tensile test (P<0.001). In the independent sub-group analysis, the mean of E-mode was statistically significantly higher in the Group 3 than that in both Group 1 and 2 (respectively, P<0.001 and P=0.024).

### Discussion

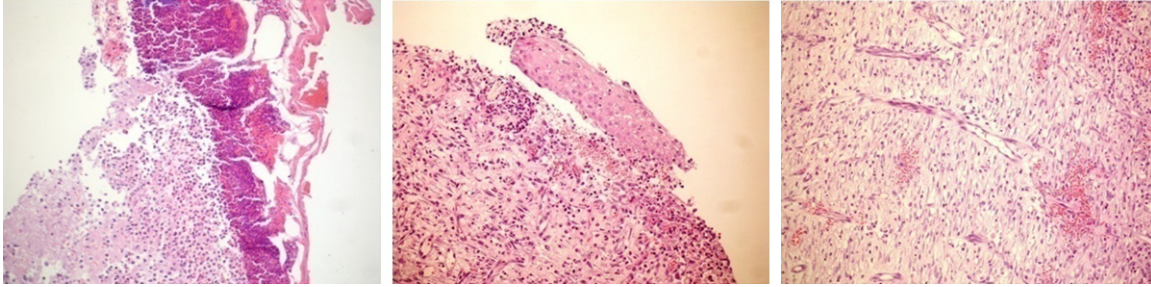
The wound healing is a process which consists of hemostasis, inflammation, proliferation, maturation and remodeling. The effect of

growth factors which are activated by platelets is greater to continue this process more quickly and smoothly. When these factors are at the wound site, recruitment and differentiation of cells in tissue repair increase and so tissue repair occurs more quickly and well [10]. In the light of this information, PRP was used in many

clinical trials and has been reported to have positive effects on tissue repair [2-8]. It is known to use different methods during obtaining PRP [9]. There is no standardization yet about which method is better to achieve the best results and what the ratio of platelet count in PRP is the most appropriate. While Marx et al. [11] argued that an increase of 338% would be ideal, Quarteiro et al. [12] reported that a 4-5 fold increase would be sufficient. In our study, it was found that there was an approximately 8-fold increase in the number of PLT.

Although there are publications [13, 14] suggest that platelets need to be activated by

## The effects of PRP on wound healing



**Figure 5.** Histopathological findings (A) Group 1 Day 7 HE  $\times$  20 (B) Group 2 Day 7 HE  $\times$  20 (C) Group 3 Day 7HE.

thrombin or calcium in order to increase the release of growth factors in the obtaining PRP, Fufa et al. [15] reported that thrombin and type I collagen is a potent stimulator for platelet and granulocyte activation. In this study, we did not use any agent for platelet activation during obtaining PRP.

It was emphasized that the presence of different concentrations of growth hormone in different types such as rat, rabbit, sheep and human might cause significant variations and also this situation would be important for clinical and experimental researches [16].

It has been reported in different studies that PRP accelerated the inflammatory process [12], increased epithelialization and neovascularization [17], raised collagen synthesis and hemostatic responses to injury and so eliminated the inhibitory effects of glucocorticoids on wound healing [18, 19]. In the literature, there was not a study comparing topical administration with an injection into the lesion area, but the positive results related to both applications have been reported in different studies [20-22]. In a study on dogs performed by Jee et al. [22], the effect of PRP which was injected into the wound site was investigated on wound healing and then it was reported to have positive effects on angiogenesis, granulation formation, collagen deposition, and re-epithelialization.

In an experimental study on rabbits conducted by Ostvar et al. [23], PRP was topically applied to the lesions created on the backs of animals and then it was reported that re-epithelialization, angiogenesis, and collagen deposition were statistically significantly increased compared to the control group. In this study, the

topical activity of PRP was also emphasized with the obtained results.

In a study by Abegao et al. [24], heterologous PRP obtained from dogs was topically applied on the wound sites created on rabbits, but there was no a significant difference between the study group and control group in terms of histopathology.

In our study, there was no significant difference between the groups for re-epithelialization, granulation tissue formation, collagen deposition, and inflammatory cell count. The increase in angiogenesis by the topical application of PRP on lesion area was found to be statistically significant compared to the control group and the injected group. The significant was only observed at 7th and 14th day, and the number of vessels appeared to be without statistical significance at the end of 21th day.

According to the results of the tensile test, the injection of PRP increased statistically significantly the tissue durability compared to the other groups. The mechanical integrity and wound strength in the wound are determined by the quantity and quality of collagen. The accumulation of collagen in wound healing reaches a maximum value 2-3 weeks after the injury. Tensile strength gradually increases with the organized fibrils with more intermolecular bands replacing the collagen fibers. There is a direct correlation between tensile strength and thickness of collagen fibrils. An increase in the number of intramolecular and intermolecular covalent bonds increases the tissue durability [1]. In our study, there was no statistical difference between the groups in terms of collagen deposition. However, the results of the mechanical tensile tests were found to be better in the injected group. Although the amount of colla-

## The effects of PRP on wound healing

gen is same, we consider that the collagen in the injected group may have higher quality and more intramolecular and intermolecular covalent bonds. We think that the detection of the quality of collagen and hydroxyl-proline levels in new studies will reveal more meaningful results.

In our study, short-term results of wound healing were evaluated and it must be emphasized that wound healing continued for 6-12 months. New studies should be made for long-term results.

Consequently, we can state that PRP had positive effects on the wound healing, the angiogenesis increased with the topical application, and the tissue durability increased with the intralesional injection. We believe that there is a need for new publications on this subject.

### Disclosure of conflict of interest

None.

**Address correspondence to:** Cihad Tatar, Department of General Surgery, Istanbul Training and Research Hospital, Istanbul 34098, Turkey. Tel: +90 533 659 98 89; Fax: +90 212 459 62 30; E-mail: tatarcihad@gmail.com

### References

- [1] Barbul A, Efron DT, Kavalukas SL. Schwartz principles of surgery. In: Brunicaardi FC, editor. Wound healing. New York: McGraw-Hill; 2016. pp. 241-273.
- [2] Rughetti A, Flamini S, Colafarina O, Dell'Orso L, Filoni A, Gallo R. Closed surgery: autologous platelet gel for the treatment of pseudoarthrosis. *J Blood Transfus* 2004; 1: 37-43.
- [3] Mazzucco L, Medici D, Serra M, Panizza R, Rivara G, Orecchia S. The use of autologous platelet gel to treat difficult-to-heal wounds: a pilot study. *Transfusion* 2004; 44: 1013-1018.
- [4] Forni F, Marzagalli M, Tesei P, Grassi A. Platelet gel: applications in dental regenerative surgery. *J Blood Transfus* 2013; 11: 102-107.
- [5] Gehring S, Hoerauf H, Laqua H, Kirchner H, Klüter H. Preparation of autologous platelets for the ophthalmologic treatment of macular holes. *Transfusion* 1999; 39: 144-148.
- [6] Thorn JJ, Sørensen H, Weis-Fogh U, Andersen M. Autologous fibrin glue with growth factors in reconstructive maxillofacial surgery. *Int J Oral Maxillofac Surg* 2004; 33: 95-100.
- [7] Bhanot S, Alex JC. Current applications of platelet gels in facial plastic surgery. *Facial Plast Surg* 2002; 18: 27-33.
- [8] Anitua E, Muruzabal F, Alcalde I, Merayo-Lloves J, Orive G. Plasma rich in growth factors (PRGF-Endoret) stimulates corneal wound healing and reduces haze formation after PRK surgery. *Exp Eye Res* 2013; 115: 153-161.
- [9] Okuda K, Kawase T, Momose M, Murata M, Saito Y, Suzuki H. Platelet-rich plasma contains high levels of platelet-derived growth factor and transforming growth factor-beta and modulates the proliferation of periodontally related cells in vitro. *J Periodontol* 2003; 74: 849-857.
- [10] Foster TE, Puskas BL, Mandelbaum BR, Gerhardt MB, Rodeo SA. Platelet-rich plasma from basic science to clinical applications. *Am J Sports Med* 2009; 37: 2259-2271.
- [11] Marx RE, Carlson ER, Eichstaedt RM, Schimmele SR, Strauss JE, Georgeff KR. Platelet-rich plasma: growth factor enhancement for bone grafts. *Oral Surg Oral Med Oral Pathol Oral Radiol Endod* 1998; 85: 638-646.
- [12] Quarteiro ML, Tognini JR, de Oliveira EL, Silveira I. The effects of platelet-rich plasma on the repair of muscle injuries in rats. *Rev Bras Ortop* 2015; 50: 586-595.
- [13] Kang J, Hur J, Kang JA, Yun JY, Choi JI, Ko SB. Activated platelet supernatant can augment the angiogenic potential of human peripheral blood stem cells mobilized from bone marrow by G-CSF. *J Mol Cell Cardiol* 2014; 75: 64-75.
- [14] Dionyssiou D, Demiri E, Foroglou P, Cheva A, Saratzis N, Aivazidis C, Karkavelas G. The effectiveness of intralesional injection of platelet-rich plasma in accelerating the healing of chronic ulcers: an experimental and clinical study. *Int Wound J* 2013; 10: 397-406.
- [15] Fufa D, Shealy B, Jacobson M, Kevy S, Murray MM. Activation of platelet-rich plasma using soluble type I collagen. *J Oral Maxillofac Surg* 2008; 66: 684-690.
- [16] Van den Dolder J, Mooren R, Vloon AP, Stoeltinga PJ, Jansen JA. Platelet-rich plasma: quantification of growth factor levels and the effect of growth and differentiation of rat bone marrow cells. *Tissue Eng* 2006; 12: 3067-3073.
- [17] Kakudo N, Kushida S, Minakata T, Suzuki K, Kusumoto K. Platelet-rich plasma promotes epithelialization and angiogenesis in a split-thickness skin graft donor site. *Med Mol Morphol* 2011; 44: 233-236.
- [18] Heldin CH, Westermark B. Platelet-derived growth factor: mechanism of action and possible *in vivo* function. *Cell Regul* 1990; 1: 555-566.
- [19] Ross R, Raines EW, Bowen-Pope DF. The biology of platelet-derived growth factor. *Cell* 1986; 46: 155-169.
- [20] Esat DM, Temel S, Ozer H, Kemal UM, Kaya F, Aslan F. Comparison of the effects of platelet rich plasma prepared in various forms on the



## The effects of PRP on wound healing

- healing of dermal Wounds in rats. *Wounds* 2016; 28: 99-108.
- [21] Carter MJ, Fylling CP, Li WW, de Leon J, Driver VR, Serena TE, Wilson J. Analysis of run-in and treatment data in a wound outcomes registry: clinical impact of topical platelet-rich plasma gel on healing trajectory. *Int Wound J* 2011; 8: 638-650.
- [22] Jee CH, Eom NY, Jang HM, Jung HW, Choi ES, Won JH, Hong IH, Kang BT, Jeong DW, Jung DI. Effect of autologous platelet-rich plasma application on cutaneous wound healing in dogs. *J Vet Sci* 2016; 17: 79-87.
- [23] Ostvar O, Shadvar S, Yahaghi E, Azma K, Fayyaz AF, Ahmadi K, Nowrouzian I. Effect of platelet-rich plasma on the healing of cutaneous defects exposed to acute to chronic wounds: a clinico-histopathologic study in rabbits. *Diagn Pathol* 2015; 10: 85-90.
- [24] Abegão KG, Bracale BN, Delfim IG, Santos ES, Laposy CB, Nai GA, Giuffrida R, Nogueira RM. Effects of heterologous platelet-rich plasma gel on standardized dermal wound healing in rabbits. *Acta Cir Bras* 2015; 30: 209-215.