

Case Report

Pemetrexed and cisplatin followed sequentially by gefitinib as neo-adjuvant therapy for stage IIB EGFR-mutation-positive lung adenocarcinoma patient: a case report and literature review

Hongyan Wang¹, Hong Tang¹, Lifeng Wang², Yufeng Wu¹, Zhe Zhang¹, Zhen He¹, Lili Wang¹, Qiming Wang¹

Departments of ¹Internal Medicine, ²Radiology, Affiliated Cancer Hospital of Zhengzhou University, Henan Cancer Hospital, Zhengzhou, China

Received August 23, 2016; Accepted October 14, 2016; Epub January 15, 2017; Published January 30, 2017

Abstract: Early-stage non-small-cell lung cancer (NSCLC) patients with EGFR mutation positive have a poor prognosis even after complete resection, which raised growing demands for multimodal therapies. Sequential therapy with chemotherapy and EGFR-TKI for advanced EGFR mutation-positive NSCLC patients significantly prolonged PFS, but there has been no report of the efficacy and complications of it in neo-adjuvant therapy for early stage NSCLC patients with EGFR mutation positive. In this paper, the case of a 64-year-old Chinese female patient diagnosed with stage IIB lung cancer harboring EGFR mutation-positive was presented. After two cycles of neo-adjuvant therapy with pemetrexed and cisplatin followed sequentially by gefitinib, the primary lesion was remarkably shrunk. The patient underwent tumor resection and systematic mediastinal lymph node dissection followed by two cycles of adjuvant chemotherapy. The patient had been followed up for 37 months after adjuvant chemotherapy without recurrence or any other complication. And during this period, she didn't receive any anti-cancer therapy. In conclusion, pemetrexed plus cisplatin followed sequentially by gefitinib as neo-adjuvant therapy is effective and safe for early stage NSCLC patients with EGFR mutation.

Keywords: Gefitinib, neo-adjuvant therapy, NSCLC, EGFR mutation

Introduction

Lung cancer remains the leading cause of cancer mortality worldwide, in which non-small cell lung cancer (NSCLC) accounts for approximately 85% of all lung cancer cases [1]. The survival rate of lung cancer varies considerably with the stage of cancer [2, 3]. To date, surgery has remained the treatment of choice for early-stage NSCLC, especially in patients with T3N0 NSCLC [4, 5], before the tumor cells develop distant metastasis [3]. Despite aggressive surgical management, stage IIB to IIIA NSCLC patients with a high recurrence rate display an adverse prognosis [6].

Theoretically, neo-adjuvant therapy potentially shrinks tumor, improves the chances of the complete resection, eradicates occult micro metastasis [7, 8], and significantly improves recurrence-free survival, time to distant recur-

rence and overall survival in resectable NSCLC [9]. After neo-adjuvant therapy, patients with potentially radical lobectomy are more likely to benefit from operation procedures [10]. Disease-free survival (DFS) is increasingly used as the primary end point in early-stage NSCLC randomized trials [6]. A large randomized Southwest Oncology Group Trial S9900 (354 patients) showed that when compared with surgery alone, neo-adjuvant chemotherapy may improve DFS and overall survival (OS) in the clinical stage of IB-IIIa NSCLC, excluding N2 disease and superior sulcus tumors [11]. In addition, aggregate data from randomized controlled trials also indicate neo-adjuvant chemotherapy could improve the overall survival in resectable NSCLC patients [12, 13].

Recently, EGFR mutations have been reported as a predictor of benefit to EGFR TKIs [14-19]. It has been suggested by several reports with

Sequential therapy for EGFR-Mutation lung adenocarcinoma

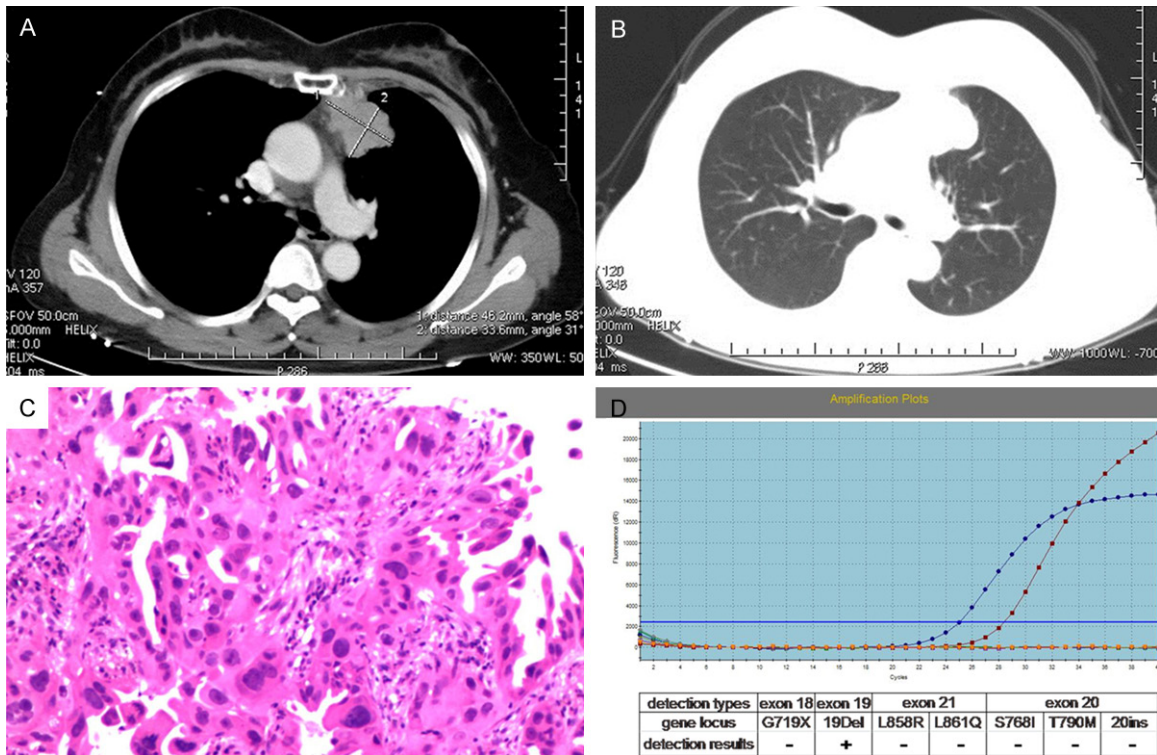


Figure 1. Imaging of patients before treatment. A. (mediastinal window) and B. (pulmonary window), chest computed tomography (CT) scan demonstrated an abnormal mass in the upper lobe of the left lung without lymph node enlargement. C. Immunohistochemical staining of biopsy tissue in the upper lobe of the left lung is histologically consistent with papillary adenocarcinoma, (magnification, 400 ×). D. EGFR molecular analyses of biopsy sample using Real-time fluorescent PCR showed the patient harbored deletion mutation in exon 19.

smaller sample sizes that preoperative EGFR-TKIs is safe and feasible to improve response rate of early-stage NSCLC [20, 21] and even results in N2 down-staging prior to attempted resection with locally advanced NSCLC harboring EGFR mutation [22, 23].

This report describes the clinicopathological features of a patient with stage IIB EGFR mutation-positive lung adenocarcinoma that exhibited remarkable therapeutic efficacy using pemetrexed plus cisplatin followed sequentially by gefitinib as neo-adjuvant therapy. Written informed consent was obtained from the patient for publication of this case report and any accompanying images.

Case report

A 64-year-old Chinese female was admitted to the Affiliated Cancer Hospital of Zhengzhou University (Zhengzhou, China) in November, 2012 due to a suspected mass in the left lung found by health examination. She was a retired

white-collar worker, non-smoker or without the influence of secondhand smoke, without cough or fever. With an Eastern Cooperative Oncology Group (ECOG) performance status of 0, she had no family history of any hereditary illnesses. In addition, she did not have any other accompanying diseases and had not taken any medications. The physical examination did not reveal any significant abnormalities. Chest computed tomography (CT) scan revealed a mass in the upper lobe of the left lung with the size of 48 mm×31 mm in the largest dimension with no clear boundary with mediastinal pleura (**Figure 1A** and **1B**). Serum tumor markers included carcinoembryonic antigen (CEA): 10.47 ng/ml, cytokeratin 19 fragment antigen 21-1: 5.14 ng/ml and neuron-specific enolase (NSE): 16.89 ng/ml. The results of laboratory tests, isotope bone scan, the head MRI, and abdominal ultrasound didn't reveal any significant abnormalities. A computed tomography-guided percutaneous lung biopsy was performed on November 21, 2012, in which the histopathological diag-

Sequential therapy for EGFR-Mutation lung adenocarcinoma

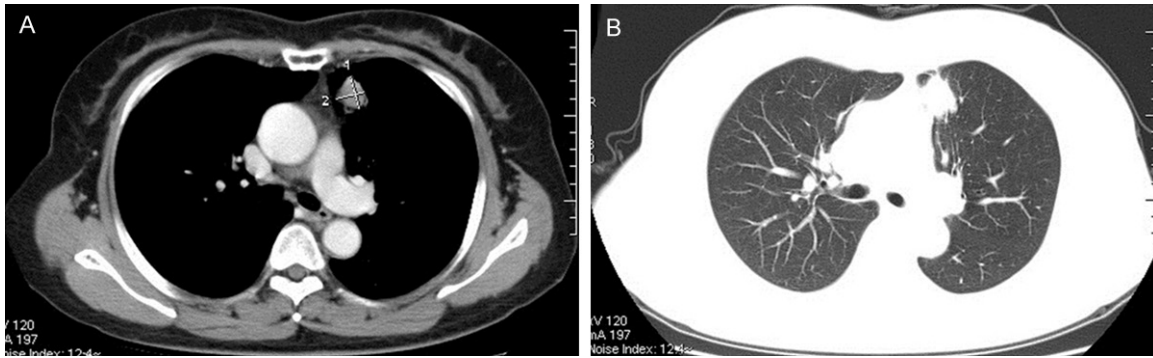


Figure 2. Chest computed tomography (CT) after neoadjuvant therapy. A. (mediastinal window) and B. (pulmonary window), CT scan showed that after 2 cycles of neo-adjuvant therapy, the mass was remarkably reduced.

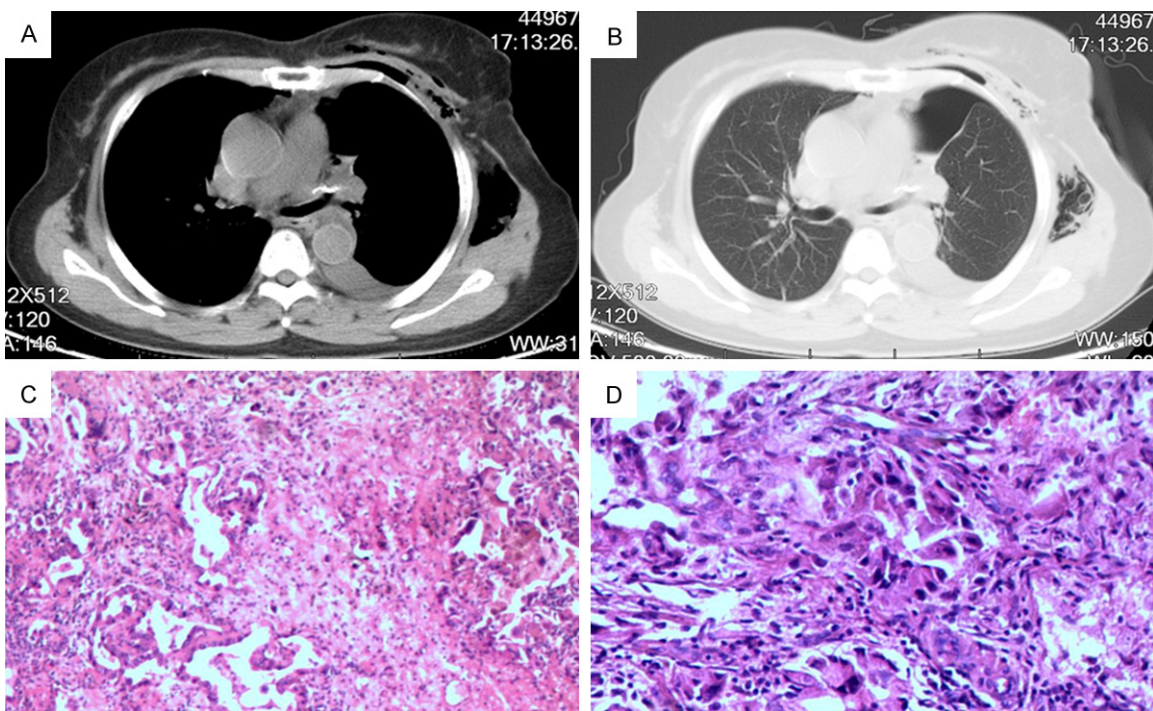


Figure 3. Postoperative CT and postoperative pathology. A. (mediastinal window) and B. (pulmonary window), post-operative CT scan showed that the patient underwent left upper lobe resection. C and D. Postoperative pathology confirmed that the lesion was adenocarcinoma (acinar and adherent growth pattern) (magnification, 400 ×).

nosis of the specimen prompted papillary adenocarcinoma (**Figure 1C**). EGFR molecular analyses of this obtained biopsy sample in exons 18 to 21 by virtue of Real-time fluorescent PCR revealed that the patient harbored deletion mutation in exon 19 (**Figure 1D**). Moreover, anaplastic lymphoma kinase (ALK) fusion protein was negative revealed by VENTANA ALK (D5F3) immunohistochemical staining. The patient with clinical stage IIB (cT3N0M0) [24] could consider surgical resection. Since the

tumor indicated no clear boundary with mediastinal pleura, it was not easy to be resected completely. After consultation with the multidisciplinary team (MDT) which includes the cardiothoracic surgeon, medical oncologist and radiation oncologist, the patient underwent neoadjuvant therapy on November 29, 2012. Pemetrexed (500 mg/m²) and cisplatin (75 mg/m²) was intravenously administered and the intravenous hydration was infused at around 2000 mL and the patient received intravenous

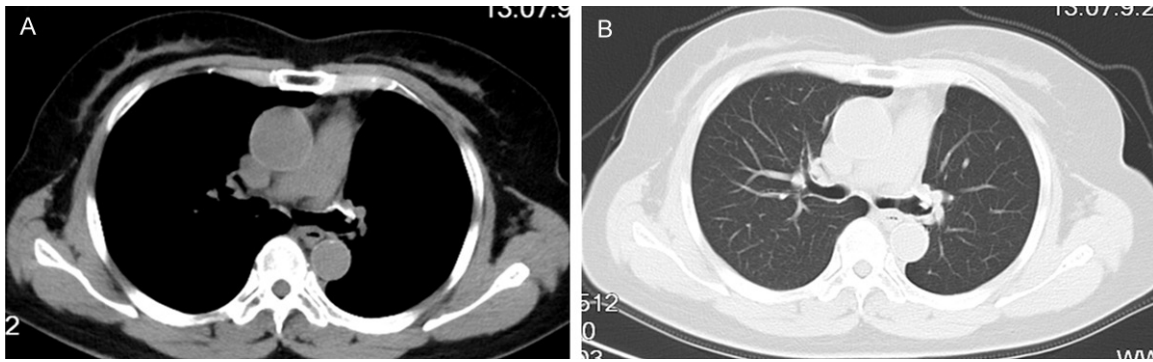


Figure 4. Chest computed tomography (CT) of the patient after she had been followed of 37 months. A. (mediastinal window) and B. (pulmonary window), without recurrence.

injection with diuresis on Day 1; gefitinib (250 mg/d) was taken orally on days 8-17, during which this treatment regimen was repeated every 3 weeks for 2 cycles. After neo-adjuvant therapy, chest CT showed that the primary tumor was significantly shrunk with the size of 17 mm×16 mm (**Figure 2A** and **2B**), which was evaluated as a partial response (PR) according to the Response Evaluation Criteria in Solid Tumors (RECIST) guidelines (version 1.1) [25]. But the biochemical examination results indicated that there was slight renal dysfunction—as serum creatine was 117 $\mu\text{mol/L}$. In response, Shenkang injection had been employed until renal dysfunction got complete recovery.

As there were no surgical contraindications, the patient underwent left upper lobe resection combined with systematic mediastinal lymph node dissection and intercostal nerve cryotherapy on January 17, 2013 (**Figure 3A** and **3B**). Postoperative pathology was adenocarcinoma (acinar and adherent growth pattern) with the visceral pleura and the fine bronchus invasion. Also, the bronchial stump was tumor-free and there was no cancer invasion into the lymph nodes (0/15) (pT3N0M0) (**Figure 3C** and **3D**). Subsequently, the patient received two cycles of postoperative chemotherapy with lesser nephrotoxicity paclitaxel liposome (150 mg/m^2) every 3 weeks after complete recovery of the renal function. Serum creatinine was found to be stable around the normal values during the subsequent treatment. The patient had been followed for a duration of 37 months after adjuvant chemotherapy without recurrence or any other complication, during which she hadn't receive any anti-cancer therapy (**Figure 4A** and **4B**).

Discussion

The mechanisms underlying local recurrence and metastasis of early-stage NSCLC remain unclear, and driver gene mutations have been found to be associated with the response to targeted therapies and prognosis of NSCLC [26]. As a driver gene, EGFR is a transmembrane glycoprotein, ligands bound to its receptor triggers both activation of the TK domain, which includes an extracellular ligand-binding domain and an intracellular kinase domain, by initiating signaling pathways and attenuating some receptor signaling achieving equilibrium to drive normal cell growth or apoptosis and differentiation or dedifferentiation [27-30]. EGFR gene is located on the short arm of chromosome 7 (7p21), which is commonly amplified or overexpressed in NSCLC patients [31]. However, the overexpression of EGFR and its ligands in several carcinomas and their association with accelerated tumor progression provide a rationale for targeting this network employing tumor-selective strategies [30]. EGFR TKIs are small molecules that take effect by inhibiting EGFR autophosphorylation, receptor activation and signal transduction [32]. EGFR mutation was the robust predictive factor behind response to EGFR-TKI [33, 34]. A recent study partially demonstrates how they confer susceptibility on TKIs, and that the relative intensities of tyrosine-phosphorylated proteins induced in cells after transfection by EGFR mutant compared to wild-type EGFR were quantitatively and qualitatively different [18].

Currently, the combination treatment of TKIs and chemotherapy has gained growing popularity, which has two modes: the synchronous

Sequential therapy for EGFR-Mutation lung adenocarcinoma

mode in which TKI and chemotherapy are administered at the same time; and the sequential mode, in which they are given in an interleaved order [35]. However, concurrent combination does not improve treatment outcome in mutation-positive patients [36]. There may be two reasons behind this: firstly, chemotherapy has been found to activate the EGFR pathway and enhance phosphorylation and subsequent ubiquitination and degradation [37, 38]. Moreover, improper activation of EGFR TK results in increased tumor cell survival, proliferation and metastasis [39, 40]. Secondly, chemotherapy and EGFR-TKI have different mechanisms. Chemotherapy drugs acts by cytotoxicity, whereas gefitinib is cytostatic. The anti-tumor effect of TKIs, by arresting the cell cycle, may lower the sensitivity of cytotoxic agents [41-43]. Nonetheless, it is commonly known that sequential use of EGFR-TKI following chemotherapy is used as the first-line treatment for advanced NSCLC patients with an activating EGFR mutation-positive, which produced improved tumor response compared to EGFR TKI treatment alone [44] and significantly prolonged PFS compared to chemotherapy alone [44, 45].

EGFR-TKIs confer an excellent PFS benefit on patients as the first-line treatment for the advanced NSCLC patients with EGFR activating mutation, especially the high abundance of EGFR mutation [46-48]. The identification of patients with an EGFR activating mutation is crucial to the use of sequential neo-adjuvant treatment. Nevertheless, it still remains uncertain whether or not EGFR-TKI can be applied to neo-adjuvant therapy to improve DFS and OS for early stage NSCLC patients. Therefore, assessment of new therapy is of considerable interest for early NSCLC patients. Several reports showed that neo-adjuvant TKI therapy boasts low toxicity and sufficient activity [20, 21] and would not affect operational difficulty and healing of wounds [49]. Neo-adjuvant EGFR-TKI in operable patients offers a unique opportunity to evaluate pathological changes induced by targeted therapy. Subsequently, pathological features of specimens from patients undergoing surgeries after neo-adjuvant therapy demonstrated that typical structural changes varied accordingly, such as deceleration in tumor cell proliferation, reduction of tumor cellularity, and a noticeable replacement

of tumors by fibrotic scar tissues [21, 50]. As we all know the sequential combination of cytotoxic chemotherapy and cytostatic EGFR-TKI delivers a high disease control rate and favorable PFS for advanced NSCLC patients harboring activating EGFR mutation [44, 51]. The pre-clinical study indicated that the G1 phase arrest induced by EGFR-TKI might have interfered with the cell cycle-dependent cytotoxic chemotherapy resulting in significantly enhanced apoptosis, when the sequential combination of chemotherapy and EGFR-TKI was used [52]. However, the efficacy of sequential combination regimen in neo-adjuvant therapy for early stage NSCLC patients with EGFR mutation remains unknown.

In the present case, a 64-year-old Chinese female patient with EGFR mutation positive who was divided into clinical stage of T3N0M0 and stage IIB in the UICC TNM staging system [7, 53, 54], which exhibits a poor prognosis after conventional management strategies. We administered two cycles of neo-adjuvant therapy with pemetrexed and cisplatin followed sequentially by gefitinib. After two cycles of this therapy, the patient was evaluated as partial response (PR) according to the RECIST 1.1 [25]. It is commonly known that adjuvant chemotherapy has become standard regimen in early stage NSCLC, at least for stage II and resected IIIA NSCLC [55]. Also, DFS rate was significantly improved in early-stage NSCLC patients who received adjuvant chemotherapy after complete surgical resection [56-58]. Since the patient exhibited chemotherapy contraindications-renal dysfunction after neo-adjuvant therapy, which was an acceptable level of toxicity, we had to delay the time of adjuvant chemotherapy until the patient's renal dysfunction was completely recovered. She received two cycles of adjuvant paclitaxel liposome chemotherapy with lesser nephrotoxicity. The data suggest that pemetrexed and cisplatin followed sequentially by gefitinib as neo-adjuvant therapy could remarkably reduce the size of the tumor so that resection is completely more easily. This case report may provide further information benefiting multi-angle disease treatment and research.

Cisplatin-based chemotherapy is the standard first-line regimen for advanced NSCLC patients [59]. Unfortunately, nephrotoxicity is the main

dose-limiting side effect of cisplatin [60-62]. It is well known that renal dysfunction, including slight impairments, which is caused by ≥ 50 mg/m² of administration, could occur in approximately one-third of patients who have undergone therapy [60, 63], even when hydration and diuresis were used adequately [64, 65]. One of the clinical signs of kidney damage is an increase of serum creatinine [66]. Furthermore, a recent research was directed towards the understanding of the molecular and cellular mechanism. According to the research, Cisplatin nephrotoxicity was the composite result of the transport of Cisplatin into renal epithelial cells to activate complex signaling pathways that lead to tubular cell injury and activation of a multiple cell death [67].

To the best of our knowledge, this is the first report on the efficacy and complication of pemetrexed and cisplatin followed sequentially by gefitinib as neo-adjuvant therapy for early stage NSCLC patient with EGFR mutation.

Neo-adjuvant sequential administration of pemetrexed and cisplatin followed by gefitinib in this EGFR mutation positive patient in early stage resectable NSCLC could remarkably reduce the size of tumor so that resection can be completed more easily. Pemetrexed and Cisplatin followed sequentially by gefitinib may potentially become a standard treatment for the early stage NSCLC in the future and some patients may benefit moderately, but whether this treatment could prolong DFS and overall survival or not needs long term follow-up in the future.

Acknowledgements

This study was supported by fund of the National Natural Science Foundation of China (No. 81272600).

Disclosure of conflict of interest

None.

Address correspondence to: Dr. Qiming Wang, Department of Internal Medicine, Affiliated Cancer Hospital of Zhengzhou University, Henan Cancer Hospital, 127 Dongming Road, Zhengzhou 450008, China. Tel: +86-137 8359 0691; Fax: +86-371-65588134; E-mail: mysubmission@126.com

References

- [1] Zhang JW, Zhao YY, Guo Y, Xue C, Hu ZH, Huang Y, Zhao HY, Zhang J, Wu X, Fang WF, Ma YX and Zhang L. The impact of both platinum-based chemotherapy and EGFR-TKIs on overall survival of patients with advanced non-small cell lung cancer. *Chin J Cancer* 2014; 33: 105-114.
- [2] Ulivi P, Foschi G, Mengozzi M, Scarpi E, Silvestrini R, Amadori D and Zoli W. Peripheral blood miR-328 expression as a potential biomarker for the early diagnosis of NSCLC. *Int J Mol Sci* 2013; 14: 10332-10342.
- [3] Zhang LQ, Wang J, Jiang F, Xu L, Liu FY and Yin R. Prognostic value of survivin in patients with non-small cell lung carcinoma: a systematic review with meta-analysis. *PLoS One* 2012; 7: e34100.
- [4] Scagliotti GV, Pastorino U, Vansteenkiste JF, Spaggiari L, Facciolo F, Orlovski TM, Maiorino L, Hetzel M, Leschinger M, Visseren-Grul C and Torri V. Randomized phase III study of surgery alone or surgery plus preoperative cisplatin and gemcitabine in stages IB to IIIA non-small-cell lung cancer. *J Clin Oncol* 2012; 30: 172-178.
- [5] Choi Y, Lee IJ, Lee CY, Cho JH, Choi WH, Yoon HI, Lee YH, Lee CG, Keum KC, Chung KY, Haam SJ, Paik HC, Lee KK, Moon SR, Lee JY, Park KR and Kim YS. Multi-institutional analysis of T3 subtypes and adjuvant radiotherapy effects in resected T3N0 non-small cell lung cancer patients. *Radiat Oncol J* 2015; 33: 75-82.
- [6] Lv C, Ma Y, Feng Q, Fang F, Bai H, Zhao B, Yan S, Wu N, Zheng Q, Li S, Chen J, Wang J, Feng Y, Wang Y, Pei Y, Fang J and Yang Y. A pilot study: sequential gemcitabine/cisplatin and icotinib as induction therapy for stage IIB to IIIA non-small-cell lung adenocarcinoma. *World J Surg Oncol* 2013; 11: 96.
- [7] Detterbeck FC, Socinski MA, Gralla RJ, Edelman MJ, Jahan TM, Loesch DM, Limentani SA, Govindan R, Zaman MB, Ye Z, Monberg MJ and Obasaju CK. Neoadjuvant chemotherapy with gemcitabine-containing regimens in patients with early-stage non-small cell lung cancer. *J Thorac Oncol* 2008; 3: 37-45.
- [8] Zhai H, Zhong W, Yang X and Wu YL. Neoadjuvant and adjuvant epidermal growth factor receptor tyrosine kinase inhibitor (EGFR-TKI) therapy for lung cancer. *Transl Lung Cancer Res* 2015; 4: 82-93.
- [9] NSCLC Meta-analysis Collaborative Group. Preoperative chemotherapy for non-small-cell lung cancer: a systematic review and meta-analysis of individual participant data. *Lancet* 2014; 383: 1561-1571.
- [10] Yang H, Yao F, Zhao Y and Zhao H. Clinical outcomes of surgery after induction treatment in

Sequential therapy for EGFR-Mutation lung adenocarcinoma

- patients with pathologically proven N2-positive stage III non-small cell lung cancer. *J Thorac Dis* 2015; 7: 1616-1623.
- [11] Pisters KM, Vallieres E, Crowley JJ, Franklin WA, Bunn PA Jr, Ginsberg RJ, Putnam JB Jr, Chansky K and Gandara D. Surgery with or without preoperative paclitaxel and carboplatin in early-stage non-small-cell lung cancer: Southwest Oncology Group Trial S9900, an intergroup, randomized, phase III trial. *J Clin Oncol* 2010; 28: 1843-1849.
- [12] Burdett S, Stewart LA and Rydzewska L. A systematic review and meta-analysis of the literature: chemotherapy and surgery versus surgery alone in non-small cell lung cancer. *J Thorac Oncol* 2006; 1: 611-621.
- [13] Song WA, Zhou NK, Wang W, Chu XY, Liang CY, Tian XD, Guo JT, Liu X, Liu Y and Dai WM. Survival benefit of neoadjuvant chemotherapy in non-small cell lung cancer: an updated meta-analysis of 13 randomized control trials. *J Thorac Oncol* 2010; 5: 510-516.
- [14] Lynch TJ, Bell DW, Sordella R, Gurubhagavathula S, Okimoto RA, Brannigan BW, Harris PL, Haslerlat SM, Supko JG, Haluska FG, Louis DN, Christiani DC, Settleman J and Haber DA. Activating mutations in the epidermal growth factor receptor underlying responsiveness of non-small-cell lung cancer to gefitinib. *N Engl J Med* 2004; 350: 2129-2139.
- [15] Ellis PM, Morzycki W, Melosky B, Butts C, Hirsh V, Krasnoshtein F, Murray N, Shepherd FA, Soulieres D, Tsao MS and Goss G. The role of the epidermal growth factor receptor tyrosine kinase inhibitors as therapy for advanced, metastatic, and recurrent non-small-cell lung cancer: a Canadian national consensus statement. *Curr Oncol* 2009; 16: 27-48.
- [16] Paez JG, Janne PA, Lee JC, Tracy S, Greulich H, Gabriel S, Herman P, Kaye FJ, Lindeman N, Boggon TJ, Naoki K, Sasaki H, Fujii Y, Eck MJ, Sellers WR, Johnson BE and Meyerson M. EGFR mutations in lung cancer: correlation with clinical response to gefitinib therapy. *Science* 2004; 304: 1497-1500.
- [17] Cappuzzo F, Hirsch FR, Rossi E, Bartolini S, Ceresoli GL, Bemis L, Haney J, Witta S, Danenberg K, Domenichini I, Ludovini V, Magrini E, Gregorc V, Doglioni C, Sidoni A, Tonato M, Franklin WA, Crino L, Bunn PA Jr and Varella-Garcia M. Epidermal growth factor receptor gene and protein and gefitinib sensitivity in non-small-cell lung cancer. *J Natl Cancer Inst* 2005; 97: 643-655.
- [18] Pao W, Miller V, Zakowski M, Doherty J, Politi K, Sarkaria I, Singh B, Heelan R, Rusch V, Fulton L, Mardis E, Kupfer D, Wilson R, Kris M and Varmus H. EGF receptor gene mutations are common in lung cancers from "never smokers" and are associated with sensitivity of tumors to gefitinib and erlotinib. *Proc Natl Acad Sci U S A* 2004; 101: 13306-13311.
- [19] Hirsch FR, Varella-Garcia M, McCoy J, West H, Xavier AC, Gumerlock P, Bunn PA Jr, Franklin WA, Crowley J and Gandara DR. Increased epidermal growth factor receptor gene copy number detected by fluorescence in situ hybridization associates with increased sensitivity to gefitinib in patients with bronchioloalveolar carcinoma subtypes: a Southwest Oncology Group Study. *J Clin Oncol* 2005; 23: 6838-6845.
- [20] Schaake EE, Kappers I, Codrington HE, Valdes Olmos RA, Teertstra HJ, van Pel R, Burgers JA, van Tinteren H and Klomp HM. Tumor response and toxicity of neoadjuvant erlotinib in patients with early-stage non-small-cell lung cancer. *J Clin Oncol* 2012; 30: 2731-2738.
- [21] Lara-Guerra H, Waddell TK, Salvarrey MA, Joshua AM, Chung CT, Paul N, Boerner S, Sakurada A, Ludkovski O, Ma C, Squire J, Liu G, Shepherd FA, Tsao MS and Leighl NB. Phase II study of preoperative gefitinib in clinical stage I non-small-cell lung cancer. *J Clin Oncol* 2009; 27: 6229-6236.
- [22] Takamochi K, Suzuki K, Sugimura H, Funai K, Mori H, Bashar AH and Kazui T. Surgical resection after gefitinib treatment in patients with lung adenocarcinoma harboring epidermal growth factor receptor gene mutation. *Lung Cancer* 2007; 58: 149-155.
- [23] Hishida T, Nagai K, Mitsudomi T, Yokoi K, Kondo H, Horinouchi H, Akiyama H, Nagayasu T and Tsuboi M. Salvage surgery for advanced non-small cell lung cancer after response to gefitinib. *J Thorac Cardiovasc Surg* 2010; 140: e69-71.
- [24] Asamura H, Chansky K, Crowley J, Goldstraw P, Rusch VW, Vansteenkiste JF, Watanabe H, Wu YL, Zielinski M, Ball D and Rami-Porta R. The International Association for the Study of Lung Cancer Lung Cancer Staging Project: Proposals for the Revision of the N Descriptors in the Forthcoming 8th Edition of the TNM Classification for Lung Cancer. *J Thorac Oncol* 2015; 10: 1675-1684.
- [25] Eisenhauer EA, Therasse P, Bogaerts J, Schwartz LH, Sargent D, Ford R, Dancey J, Arbuck S, Gwyther S, Mooney M, Rubinstein L, Shankar L, Dodd L, Kaplan R, Lacombe D and Verweij J. New response evaluation criteria in solid tumours: revised RECIST guideline (version 1.1). *Eur J Cancer* 2009; 45: 228-247.
- [26] Zhu JF, Feng XY, Zhang XW, Wen YS, Lin P, Rong TH, Cai L and Zhang LJ. Time-varying pattern of postoperative recurrence risk of early-stage (T1a-T2bN0M0) non-small cell lung cancer (NSCLC): results of a single-center study of

Sequential therapy for EGFR-Mutation lung adenocarcinoma

- 994 Chinese patients. *PLoS One* 2014; 9: e106668.
- [27] Wells A. EGF receptor. *Int J Biochem Cell Biol* 1999; 31: 637-643.
- [28] Cohen S. Purification of the receptor for epidermal growth factor from A-431 cells: its function as a tyrosyl kinase. *Methods Enzymol* 1983; 99: 379-387.
- [29] Jorissen RN, Walker F, Pouliot N, Garrett TP, Ward CW and Burgess AW. Epidermal growth factor receptor: mechanisms of activation and signalling. *Exp Cell Res* 2003; 284: 31-53.
- [30] Arteaga CL. The epidermal growth factor receptor: from mutant oncogene in nonhuman cancers to therapeutic target in human neoplasia. *J Clin Oncol* 2001; 19: 32s-40s.
- [31] John T, Liu G and Tsao MS. Overview of molecular testing in non-small-cell lung cancer: mutational analysis, gene copy number, protein expression and other biomarkers of EGFR for the prediction of response to tyrosine kinase inhibitors. *Oncogene* 2009; 28 Suppl 1: S14-23.
- [32] Roengvoraphoj M, Tsongalis GJ, Dragnev KH and Rigas JR. Epidermal growth factor receptor tyrosine kinase inhibitors as initial therapy for non-small cell lung cancer: focus on epidermal growth factor receptor mutation testing and mutation-positive patients. *Cancer Treat Rev* 2013; 39: 839-850.
- [33] Mok TS, Wu YL, Thongprasert S, Yang CH, Chu DT, Saijo N, Sunpaweravong P, Han B, Margono B, Ichinose Y, Nishiwaki Y, Ohe Y, Yang JJ, Chewaskulyong B, Jiang H, Duffield EL, Watkins CL, Armour AA and Fukuoka M. Gefitinib or carboplatin-paclitaxel in pulmonary adenocarcinoma. *N Engl J Med* 2009; 361: 947-957.
- [34] Fukuoka M, Wu YL, Thongprasert S, Sunpaweravong P, Leong SS, Sriuranpong V, Chao TY, Nakagawa K, Chu DT, Saijo N, Duffield EL, Rukazenzov Y, Speake G, Jiang H, Armour AA, To KF, Yang JC and Mok TS. Biomarker analyses and final overall survival results from a phase III, randomized, open-label, first-line study of gefitinib versus carboplatin/paclitaxel in clinically selected patients with advanced non-small-cell lung cancer in Asia (IPASS). *J Clin Oncol* 2011; 29: 2866-2874.
- [35] Yan H, Li H, Li Q, Zhao P, Wang W and Cao B. The Efficacy of Synchronous Combination of Chemotherapy and EGFR TKIs for the First-Line Treatment of NSCLC: A Systematic Analysis. *PLoS One* 2015; 10: e0135829.
- [36] Leung L, Mok TS and Loong H. Combining chemotherapy with epidermal growth factor receptor inhibition in advanced non-small cell lung cancer. *Ther Adv Med Oncol* 2012; 4: 173-181.
- [37] Ahsan A, Hiniker SM, Ramanand SG, Nyati S, Hegde A, Helman A, Menawat R, Bhojani MS, Lawrence TS and Nyati MK. Role of epidermal growth factor receptor degradation in cisplatin-induced cytotoxicity in head and neck cancer. *Cancer Res* 2010; 70: 2862-2869.
- [38] Chun PY, Feng FY, Scheurer AM, Davis MA, Lawrence TS and Nyati MK. Synergistic effects of gemcitabine and gefitinib in the treatment of head and neck carcinoma. *Cancer Res* 2006; 66: 981-988.
- [39] Citri A and Yarden Y. EGF-ERBB signalling: towards the systems level. *Nat Rev Mol Cell Biol* 2006; 7: 505-516.
- [40] Ciardiello F and Tortora G. EGFR antagonists in cancer treatment. *N Engl J Med* 2008; 358: 1160-1174.
- [41] Moyer JD, Barbacci EG, Iwata KK, Arnold L, Boman B, Cunningham A, DiOrto C, Doty J, Morin MJ, Moyer MP, Neveu M, Pollack VA, Pustilnik LR, Reynolds MM, Sloan D, Theleman A and Miller P. Induction of apoptosis and cell cycle arrest by CP-358,774, an inhibitor of epidermal growth factor receptor tyrosine kinase. *Cancer Res* 1997; 57: 4838-4848.
- [42] Davies AM, Ho C, Lara PN Jr, Mack P, Gumerlock PH and Gandara DR. Pharmacodynamic separation of epidermal growth factor receptor tyrosine kinase inhibitors and chemotherapy in non-small-cell lung cancer. *Clin Lung Cancer* 2006; 7: 385-388.
- [43] Solit DB, She Y, Lobo J, Kris MG, Scher HI, Rosen N and Sirotnak FM. Pulsatile administration of the epidermal growth factor receptor inhibitor gefitinib is significantly more effective than continuous dosing for sensitizing tumors to paclitaxel. *Clin Cancer Res* 2005; 11: 1983-1989.
- [44] Yan H, Li Q, Wang W, Zhen H and Cao B. Systems assessment of intercalated combination of chemotherapy and EGFR TKIs versus chemotherapy or EGFR TKIs alone in advanced NSCLC patients. *Sci Rep* 2015; 5: 15355.
- [45] Wu YL, Lee JS, Thongprasert S, Yu CJ, Zhang L, Ladrera G, Srimuninnimit V, Sriuranpong V, Sandoval-Tan J, Zhu Y, Liao M, Zhou C, Pan H, Lee V, Chen YM, Sun Y, Margono B, Fuerte F, Chang GC, Seetalarom K, Wang J, Cheng A, Syahrudin E, Qian X, Ho J, Kurnianda J, Liu HE, Jin K, Truman M, Bara I and Mok T. Intercalated combination of chemotherapy and erlotinib for patients with advanced stage non-small-cell lung cancer (FASTACT-2): a randomised, double-blind trial. *Lancet Oncol* 2013; 14: 777-786.
- [46] Zhang WQ, Li T and Li H. Efficacy of EGFR tyrosine kinase inhibitors in non-small-cell lung cancer patients with/without EGFR-mutation: evidence based on recent phase III randomized trials. *Med Sci Monit* 2014; 20: 2666-2676.

Sequential therapy for EGFR-Mutation lung adenocarcinoma

- [47] Zhou C, Wu YL, Chen G, Feng J, Liu XQ, Wang C, Zhang S, Wang J, Zhou S, Ren S, Lu S, Zhang L, Hu C, Hu C, Luo Y, Chen L, Ye M, Huang J, Zhi X, Zhang Y, Xiu Q, Ma J, Zhang L and You C. Erlotinib versus chemotherapy as first-line treatment for patients with advanced EGFR mutation-positive non-small-cell lung cancer (OPTIMAL, CTONG-0802): a multicentre, open-label, randomised, phase 3 study. *Lancet Oncol* 2011; 12: 735-742.
- [48] Zhou Q, Zhang XC, Chen ZH, Yin XL, Yang JJ, Xu CR, Yan HH, Chen HJ, Su J, Zhong WZ, Yang XN, An SJ, Wang BC, Huang YS, Wang Z and Wu YL. Relative abundance of EGFR mutations predicts benefit from gefitinib treatment for advanced non-small-cell lung cancer. *J Clin Oncol* 2011; 29: 3316-3321.
- [49] Wang T, Liu Y, Zhou B, Wang Z, Liang N, Zhang Y, Dong Z and Li J. Effects of icotinib on early-stage non-small-cell lung cancer as neoadjuvant treatment with different epidermal growth factor receptor phenotypes. *Onco Targets Ther* 2016; 9: 1735-1741.
- [50] Lara-Guerra H, Chung CT, Schwock J, Pintilie M, Hwang DM, Leighl NB, Waddell TK and Tsao MS. Histopathological and immunohistochemical features associated with clinical response to neoadjuvant gefitinib therapy in early stage non-small cell lung cancer. *Lung Cancer* 2012; 76: 235-241.
- [51] Takahashi K and Saito H. Is epidermal growth factor receptor tyrosine kinase inhibitor in combination with cytotoxic chemotherapy a better treatment option for patients with EGFR-mutated non-small-cell lung cancer? *Transl Lung Cancer Res* 2016; 5: 98-101.
- [52] Mahaffey CM, Davies AM, Lara PN Jr, Pryde B, Holland W, Mack PC, Gumerlock PH and Gandara DR. Schedule-dependent apoptosis in K-ras mutant non-small-cell lung cancer cell lines treated with docetaxel and erlotinib: rationale for pharmacodynamic separation. *Clin Lung Cancer* 2007; 8: 548-553.
- [53] Mountain CF. Revisions in the International System for Staging Lung Cancer. *Chest* 1997; 111: 1710-1717.
- [54] Goldstraw P, Crowley J, Chansky K, Giroux DJ, Groome PA, Rami-Porta R, Postmus PE, Rusch V and Sobin L. The IASLC Lung Cancer Staging Project: proposals for the revision of the TNM stage groupings in the forthcoming (seventh) edition of the TNM Classification of malignant tumours. *J Thorac Oncol* 2007; 2: 706-714.
- [55] Liang Y and Wakelee HA. Adjuvant chemotherapy of completely resected early stage non-small cell lung cancer (NSCLC). *Transl Lung Cancer Res* 2013; 2: 403-410.
- [56] Arriagada R, Bergman B, Dunant A, Le Chevalier T, Pignon JP and Vansteenkiste J. Cisplatin-based adjuvant chemotherapy in patients with completely resected non-small-cell lung cancer. *N Engl J Med* 2004; 350: 351-360.
- [57] Winton T, Livingston R, Johnson D, Rigas J, Johnston M, Butts C, Cormier Y, Goss G, Inculet R, Vallieres E, Fry W, Bethune D, Ayoub J, Ding K, Seymour L, Graham B, Tsao MS, Gandara D, Kesler K, Demmy T and Shepherd F. Vinorelbine plus cisplatin vs. observation in resected non-small-cell lung cancer. *N Engl J Med* 2005; 352: 2589-2597.
- [58] Chen YY, Wang LW, Wang SY, Wu BB, Wang ZM, Chen FF and Xiong B. Meta-analysis of postoperative adjuvant chemotherapy without radiotherapy in early stage non-small cell lung cancer. *Onco Targets Ther* 2015; 8: 2033-2043.
- [59] Ozkaya S, Findik S, Atici AG and Dirica A. Cisplatin-based chemotherapy in elderly patients with advanced stage (IIIB and IV) non-small cell lung cancer patients. *Neoplasma* 2011; 58: 348-351.
- [60] Arany I and Safirstein RL. Cisplatin nephrotoxicity. *Semin Nephrol* 2003; 23: 460-464.
- [61] Sastry J and Kellie SJ. Severe neurotoxicity, ototoxicity and nephrotoxicity following high-dose cisplatin and amifostine. *Pediatr Hematol Oncol* 2005; 22: 441-445.
- [62] Boulikas T. Poly(ADP-ribose) synthesis in blocked and damaged cells and its relation to carcinogenesis. *Anticancer Res* 1992; 12: 885-898.
- [63] Beyer J, Rick O, Weinknecht S, Kingreen D, Lenz K and Siegert W. Nephrotoxicity after high-dose carboplatin, etoposide and ifosfamide in germ-cell tumors: incidence and implications for hematologic recovery and clinical outcome. *Bone Marrow Transplant* 1997; 20: 813-819.
- [64] Yao X, Panichpisal K, Kurtzman N and Nugent K. Cisplatin nephrotoxicity: a review. *Am J Med Sci* 2007; 334: 115-124.
- [65] Schilsky RL. Renal and metabolic toxicities of cancer chemotherapy. *Semin Oncol* 1982; 9: 75-83.
- [66] Miller RP, Tadagavadi RK, Ramesh G and Reeves WB. Mechanisms of Cisplatin nephrotoxicity. *Toxins (Basel)* 2010; 2: 2490-2518.
- [67] Pabla N and Dong Z. Cisplatin nephrotoxicity: mechanisms and renoprotective strategies. *Kidney Int* 2008; 73: 994-1007.