

Original Article

Two reports of juvenile myelomonocytic leukemia and its literature review

Le Chen, Wen-Li Lu, Li Jiang, Wei Li, Meng-Ting Xie, Xin-Qiong Wang, Xiao-Yu Ma, Chun-Di Xu

Department of Pediatrics, Ruijin Hospital Affiliated to Shanghai Jiao Tong University School of Medicine, Shanghai 200025, China

Received March 9, 2016; Accepted June 3, 2016; Epub February 15, 2017; Published February 28, 2017

Abstract: Objective: To explore the clinical characteristics and gene mutation of children with JMML, so as to improve the diagnostic level for this disease. Methods: Clinical characteristics, diagnosis and treatment, and gene mutation, were observed and explored with the combination of literature review. Results: The clinical manifestations included infection, rash, and hematological abnormality. By means of gene analysis, the mutation of NF1 gene was found in patient 1: nonsense mutation in its Exon10a, c.1318C > T; P.Arg440x and insertion mutation in Exon13, c.2033_2034insC; p.Pro678ProfsX2. In patient 2, two gene mutations of N-RAS were observed, Exon2 missense mutation c.35G > T (p.G21V) and Exon3 intron mutation c.112-70C > T. No relationship was noted between the effect and prognosis of the children after transplantation and nonchemotherapy, low dose of chemotherapy, and strong chemotherapy before transplantation. Conclusion: Clinical and laboratory tests of children with JMML lack specificity, and currently, molecular genetic testing is an important diagnostic basis for the disease.

Keywords: Juvenile Myelomonocytic leukemia, genetic diagnosis, gene mutation

Introduction

Juvenile myelomonocytic leukemia (JMML) is a rare malignant blood system disease among children. In the past, due to the lack of knowledge about this disease and the poor effect of conventional chemotherapy, the clinical diagnosis and treatment of this disease was very difficult. In 2008, the World Health Organization classified this disease into myelodysplastic syndrome (MDS) or myeloproliferative neoplasms (MPN). [1] Clinical manifestations of patients with JMML include infection, anemia, thrombocytopenia, infiltrated skin and mucosa, lymphadenovary in spleen and lymph, immature cells in the peripheral blood, obviously active hyperplasia of marrow cells in the bone marrow cytological examination, and primitive cells < 20%. [2] In recent years, with the development of studies on the pathogenesis of JMML at home and abroad, especially for detecting the disease-related genes, a majority of children are able to be diagnosed, but the only relatively available way to cure this disease is the allogeneic hematopoietic stem cell

transplantation [2]. The gene tests of two children with JMML admitted to the Ruijin Hospital Affiliated to Shanghai Jiao Tong University School of Medicine from 2014 to 2015 were reported in this study, and were reviewed with the combination of latest relevant literature, to improve pediatricians' diagnosis level and treatment level towards this disease.

Materials and methods

Clinical data

Two children were admitted to the Ruijin Hospital Affiliated to Shanghai Jiao Tong University School of Medicine from January 2014 to January 2015, and both were male.

Methods

Through retrospective analysis, relevant analysis was conducted on general clinical data and laboratory examination of the two children with JMML, such as routine blood test, fetal hemoglobin (HbF) and bone marrow examination, and molecular gene detection. The diag-

NF1: Located in the chromosome 17

Exon4c+5: c. 702G>A; p. Leu234Leu

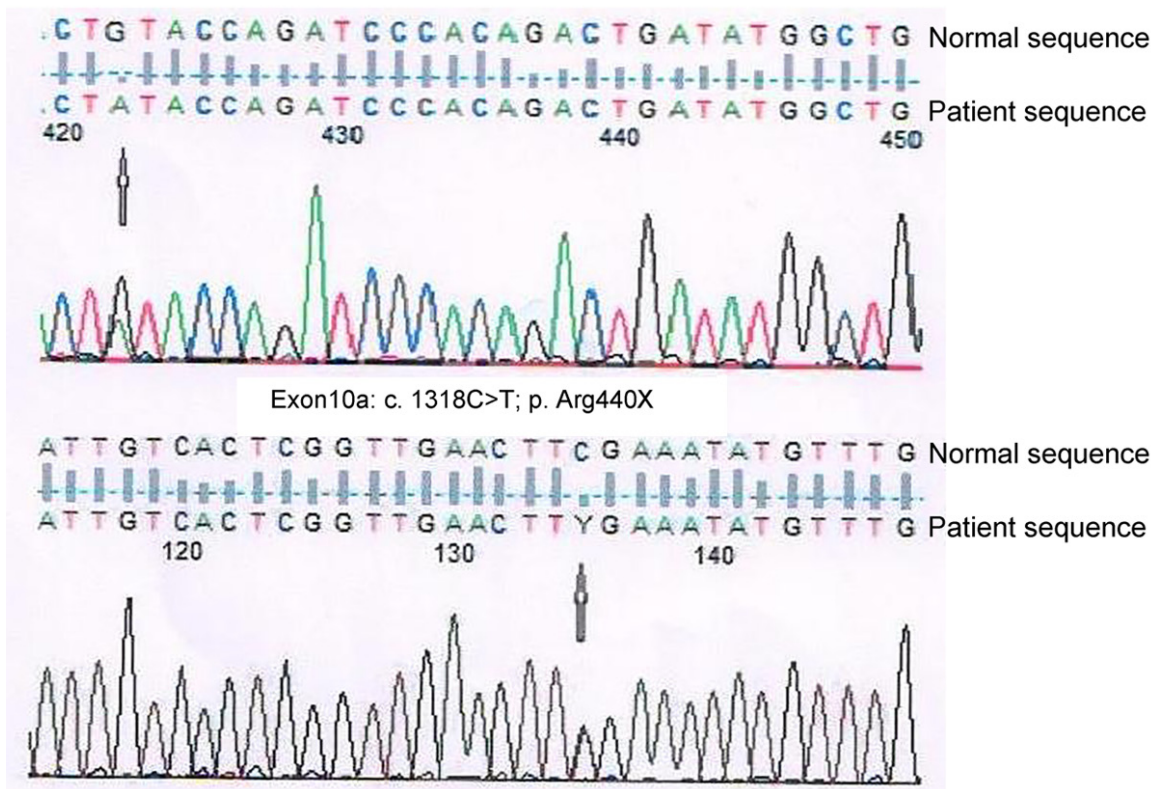


Figure 1. Gene sequence diagram of patient 1.

nostic criteria of JMML were conducted in accordance with the new diagnostic criteria [1].

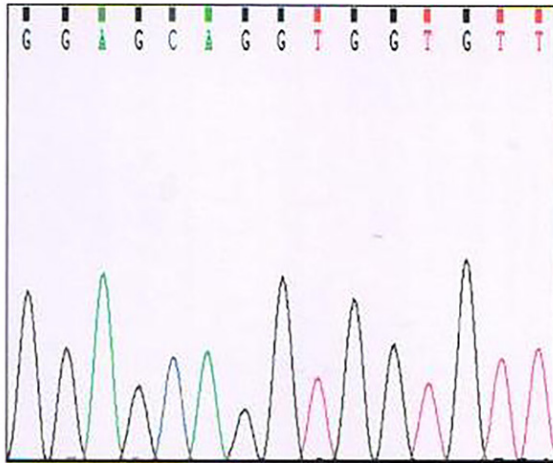
Results

Patient 1, male, at the age of 3 years 9 months, was admitted to a hospital because of “recurrent mass in lower extremities for 4 months”. The routine blood test showed white blood cells (WBCs) of $17.67 \times 10^9/L$, neutrophils of $8.04 \times 10^9/L$, lymphocytes of $3.22 \times 10^9/L$, monocytes of $5.64 \times 10^9/L$, red blood cells (RBC) of $2.55 \times 10^{12}/L$, hemoglobin content of 86 g/L, and blood platelets of $126 \times 10^9/L$. B-ultrasound showed mild swollen spleen. Bone marrow smears showed hyperactive hyperplasia of nucleated cells, primitive cells accounting for 4.5%, primitive immature monocytes accounting for 11.5%, and mature monocytes accounting for 12%. Thus, the patient was diagnosed with MDS/myeloproliferative tumor-JMML. Then, he came to the Ruijin

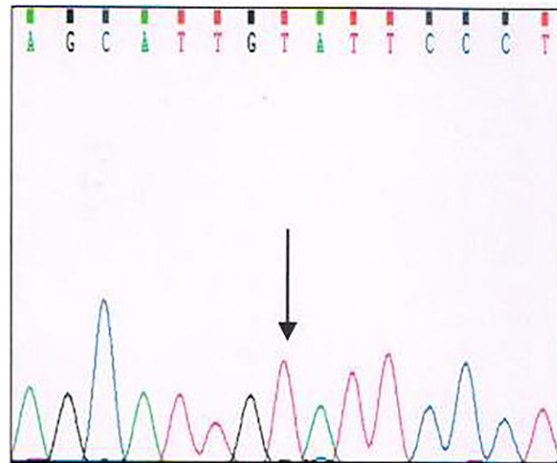
Hospital for specific diagnosis. Physical examination showed mild anemia, systematic café au lait macules, many enlarged lymph nodes of 3~4 cm on the neck and under maxillary, swelling of degree III in bilateral tonsils, at 5 cm above the left midclavicular line of the liver and under ribs, 5 cm above the right midclavicular line of the spleen and under ribs, a 0.5-cm red swelling ecchymosis was palpated with the right foot thumb. B-ultrasound of abdominal and superficial lymph nodes showed lymphadenovari in retroperitoneum and bilateral neck, clavicle, axillary fossa, groin, and other sites. Computed tomography (CT) showed invaded tumors in the posterior wall of the nasopharynx top and tonsil, and systemic multiple lymphadenovari. Routine blood test checked in the Ruijin Hospital showed WBCs of $13.22 \times 10^9/L$, neutrophils of $4.57 \times 10^9/L$, lymphocytes of $5.22 \times 10^9/L$, monocytes of $2.34 \times 10^9/L$, RBCs of $2.92 \times 10^{12}/L$, hemoglobin content of 90 g/L, blood platelets of $126 \times 10^9/L$, and

NRAS:

EXON2 Normal

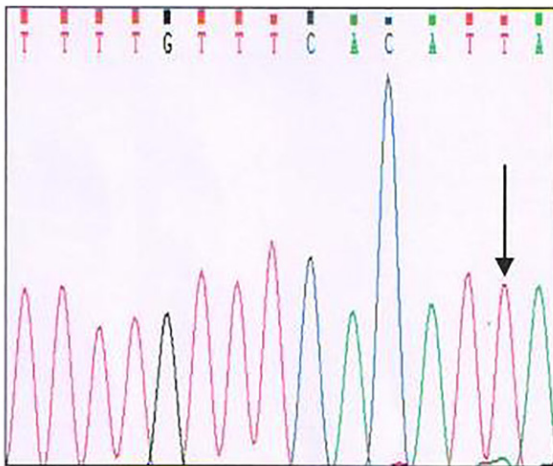


EXON3 intron c. 112-70C>T



CBL:

EXON7 intron c. 1095+19G>T



EXON8 Normal

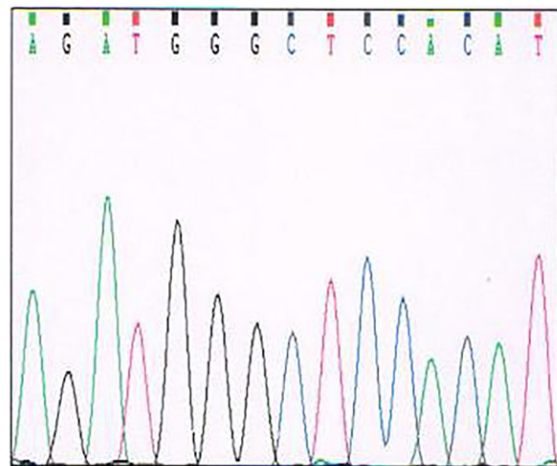


Figure 2. Gene sequence diagram of patient 2.

HbF of 10.0%. The examination of bone marrow smears showed obviously active hyperplasia of the bone marrow, primitive cells accounting for 4.5%, and increased mature monocytes. Primitive cells accounting for 3% was found in the attached peripheral blood smears during the bone marrow examination. The patient was diagnosed with probable JMML. Philadelphia (Ph) chromosome in bone marrow cells was negative; fluorescence *in situ* hybridization (FISH) detection of bone marrow cells showed no chromosome 7 or deletion of the long arm of chromosome 7, and no abnormality in the count of chromosome 8; and the BCR-ABL (p210) fusion gene in the bone marrow was negative.

The analysis of JMML-related genes in the peripheral blood revealed the mutation of type I neurofibromatosis (NF1) gene. The manifestations included nonsense mutation in the NF1 gene Exon10a c.1318C > T; P.Arg440x (heterozygous) causing an early termination of the encoding protein, and insertion mutation in the NF1 gene Exon13 c.2033-2024insC; p.Pro678ProfsX2 (heterozygous) causing an early termination of the encoded protein (see **Figures 1, 4A and 4B**).

Patient 2 was a male, who got fever and cough at the age of 2 years 5 months. Routine blood test in the local hospital showed WBCs of 45.29

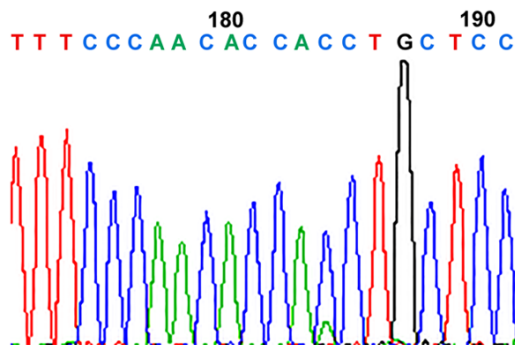


Figure 3. Reverse gene sequence diagram of patient 2.

$\times 10^9/L$, neutrophils of $20.67 \times 10^9/L$, lymphocytes of $5.39 \times 10^9/L$, monocytes of $5.64 \times 10^9/L$, RBCs of $2.55 \times 10^{12}/L$, hemoglobin content of 86 g/L, and blood platelets of $126 \times 10^9/L$. The examination of bone marrow cells suggested the presence of acute myelomonocytic leukemia (AML-M4) myelogram. Then the patient came to the Ruijin Hospital for further treatment. Physical examination showed bilateral cervical lymphadenovary (1~2 cm) and an HbF of 4.7%. Bone marrow smears showed active hyperplasia; the smears showed 15% primitive cells and juvenile single cells; primitive cells of the peripheral blood on peripheral blood smears accounted for 1%. The patient was diagnosed with probable myelogram of JMML and AML tendency; Ph chromosome in bone marrow cells was negative; the FISH detection of bone marrow cells showed no chromosome 7 or the deletion of the long arm of chromosome 7, and no abnormality in the number of chromosome 8; and the BCR-ABL (p210) fusion gene in the peripheral blood showed negative. The analysis of JMML-related genes in the peripheral blood revealed two mutations in N-RAS and one mutation in CBL, in which N-RAS (Exon2) showed missense mutation with low content c.35G > T (p.G21V), and by literature research, it was considered that it might be pathologically significant for JMML; [3] N-RAS (Exon3) showed an intron mutation c.112-70C > T. CBL was an intron mutation around Exon7 c.1095+19G > T mutation. By literature research, the two mutations were considered as sites of a single-nucleotide polymorphism of JMML-related genes [4] (Figure 2). N-RAS (Exon2) was further confirmed with a low content of missense mutations by reverse sequencing (Figures 3, 4C and 4D).

Discussion

JMML is a chronic myeloid leukemia, which rarely occurs in early childhood, and accounts for 1% to 2% of childhood leukemia. It often occurs in children, and the onset ratio of males to females is about 1.4~2.5:1 [5]. The onset age of the two children with JMML in this study was, respectively, 3 years 9 months and 2 years 5 months, and both were male, which is substantially the same as the onset rules of this disease. The commonest clinical manifestations of patients with JMML include rash, anemia, hemorrhagia, infection, etc. Lymphadenovary in liver and spleen can be found in physical examination, and cafe au lait macule can be seen in a small number of patients [5]. The clinical significance of the bone marrow test in the laboratory might not be as great as that of the peripheral blood. Peripheral hemogram of patients with JMML often shows increased WBCs, mainly granulocytes and monocytes, especially for monocyte count generally about $> 1 \times 10^9/L$; anemia; thrombocytopenia, and immature cells might be associated with; and HbF often rises. The examination of bone marrow cells reveals primitive cells of the bone marrow $< 20\%$, Ph chromosome negative, and BCR-ABL fusion gene negative. Due to the lack of specific manifestations in the bone marrow examination of this disease, diagnosis for JMML was more difficult than that for other leukemia in the past and it often required the patient's clinical manifestations, examination of bone marrow cells, peripheral hemogram examination, HbF determination, Ph chromosome (-), BCR-ABL fusion gene (-), and other results for reference to make a comprehensive judgment.

The diagnostic criteria suggested by the 2008 International JMML Working Group are as follows: (1) Clinical manifestations shall include hepatosplenomegaly, lymphadenovary, pallor, fever, and rash. (2) Laboratory tests shall meet all of the following three: namely, Ph chromosome negative, BCR-ABL gene negative, peripheral blood monocytes $> 1.0 \times 10^9/L$, and bone marrow immature cells $< 20\%$. (3) The diagnostic criteria shall meet at least two of the following: namely, (a) increased HbF; (b) myeloid immature cells in peripheral blood smears; (c) WBC $> 10.0 \times 10^9/L$; (d) abnormal clone (including chromosome monomer 7); and (e) hyper-

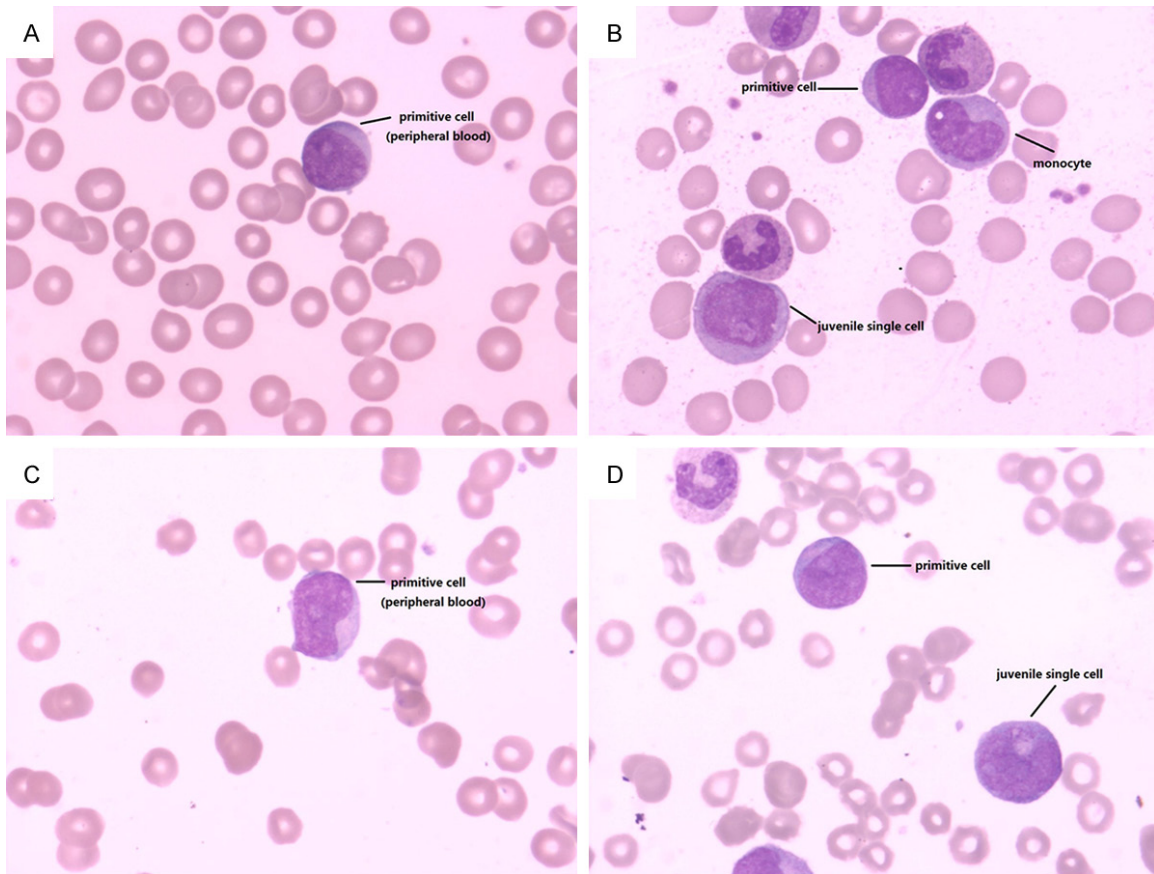


Figure 4. A. Primitive cells were found in peripheral blood of patient 1; B. Primitive cells, juvenile single cells and monocytes were found in bone marrow smears; C. Primitive cells were found in peripheral blood of patient 2; D. Primitive cells and juvenile single cells were found in bone marrow smears.

sensitivity of myeloid progenitors cultured *in vitro* toward granulocyte-macrophage colony-stimulating factor [1].

In recent years, studies on the molecular pathogenesis of JMML have made great progress at home and abroad, and gene mutations of K-RAS, N-RAS, CBL, PTPN11, NF1, and SETBP1 have been found in about 80% of children with JMML. [6] These gene mutations play an important role in the pathogenesis of JMML. In the same way, these abnormal genes are present in children with JMML, and they play an important role in the diagnosis of the disease. The molecular pathogenesis of JMML is common in the following situations: (1) Self-mutation of RAS gene: The point mutations of RAS gene occurs in about 30% of human tumors, and the commonest one is point mutation of K-RAS (about 85%). RAS proteins of these point mutations lose guanosine triphosphate (GTP) enzyme activity and prevent the

active form of RAS protein from being hydrolyzed by a GTPase-activating protein (GAP); therefore, it can exist in the form of active combination. Another finding is that mutations of N-RAS gene and K-RAS gene (ratio between 15% and 30%) lead to an abnormal activation of the RAS pathway, which results in myeloid cells' hypersensitivity toward granulocyte colony-stimulating factor, thus causing tumors. [7] In patient 2, two gene mutations of N-RAS were observed, namely, Exon2 missense mutation c.35G > T (p.G21V) and Exon3 intron mutation c.112-70C > T. (2) The deletion of GAP: The most typical one is the deletion of neurofibromin encoded by the NF1 gene. The encoding product of the NF1 gene, neurofibromin, has GAP activity. But the NF1 gene is a tumor suppressor, and its encoding product can inactivate the RAS protein. The mutation of NF1 gene occurs in 11% of patients, resulting in the deletion of its function. This leads to the abnormal sustained activation of RAS protein,

which releases the inhibitory function of the RAS pathway, leading to the its sustained activation; thus malignant tumors appear [8]. The mutation of NF1 gene was found in patient 1: Nonsense mutation in its Exon10a c.1318C > T; P.Arg440x and insertion mutation in Exon13 c.2033_2034insC; p.Pro678ProfsX2. (3) Mutations of other RAS downstream effectors: The phosphoinositide 3-kinase (PI3K) pathway in the downstream of the RAS pathway is activated for the amplification of the PI3K's downstream target Akt2, which mainly results from the deletion of the tumor suppressor gene PTEN. PTEN (phosphatase and tensin homolog deleted on chromosome 10) is a kind of tumor suppressor gene. It resists the function of PI3K by the dephosphorylation of phosphatidylinositol 3,4,5 trisphosphate to inhibit the function of Akt. The latter plays a positive role on the proliferation, differentiation, and apoptosis of cells. Its inhibition function is released in the case of gene mutation, which leads to the continued activation of the RAS pathway; therefore, malignant tumors appear [6].

In addition to the above changes of the RAS pathway, CBL, SETBP1, and other genes may also be associated with the onset of JMML. The two children in the Ruijin Hospital also showed CBL mutation.

The clinical changes of JMML are diverse. Some children with acute progressive changes progress to leukemia or tumor cell invasion in extramedullary vital organs. For example, the invasion in lung causes respiratory failure. Therefore, death resulting from tumor cell invasion in extramedullary vital organs is usually seen in JMML patients. The progress of illness in some children is pretty slow, even in a stable status at a certain stage, and a small part of them can ease naturally [6].

Currently, due to the lack of standardized treatment for JMML and the poor efficacy of chemotherapy on this disease, a big difficulty is faced in the treatment, and the only effective treatment method is the allogeneic hematopoietic stem cell transplantation. Therefore, children with no clinical symptoms cannot be treated before finding a suitable donor. The study also showed that no obvious relationship was noted between the effect and prognosis of children after transplantation and nonchemotherapy, low dose of chemotherapy,

and strong chemotherapy before transplantation [9]. At present, it is recommended that once JMML is diagnosed, the allogeneic hematopoietic stem cell transplantation should be performed timely when the suitable donor is found. The transplantation lets more than 50% of children have over 3 years of disease-free survival, [10] but if not transplanted, more than 80% of the children will die within 3 years. Related factors suggesting poor prognosis include age at diagnosis over 2 years old, blood platelet count less than $40 \times 10^9/L$, higher HbF, etc. In recent years, with the development of gene-targeted therapy, the treatment of JMML has made a new progress. The new targeted therapy for the RAS signal path is expected to improve the prognosis of some children with JMML.

Disclosure of conflict of interest

None.

Address correspondence to: Wen-Li Lu, Department of Pediatrics, Ruijin Hospital Affiliated to Shanghai Jiao Tong University School of Medicine, No. 197, Ruijin 2 Road, Shanghai 200025, China. Tel: +86-13501624118; Fax: +86-64085-875; E-mail: lwl204059@126.com

References

- [1] Tefferi A and Vardiman JW. Classification and diagnosis of myeloproliferative neoplasms: the 2008 World Health Organization criteria and point-of-care diagnostic algorithms. *Leukemia* 2008; 22: 14-22.
- [2] Loh ML. Recent advances in the pathogenesis and treatment of juvenile myelomonocytic leukaemia. *Br J Haematol* 2011; 152: 677-687.
- [3] Loh ML. Childhood myelodysplastic syndrome: focus on the approach to diagnosis and treatment of juvenile myelomonocytic leukemia. *Hematology Am Soc Hematol Educ Program* 2010; 2010: 357-362.
- [4] de Vries AC, Zwaan CM and van den Heuvel-Eibrink MM. Molecular basis of juvenile myelomonocytic leukemia. *Haematologica* 2010; 95: 179-182.
- [5] Hao CL. Study progress of juvenile myelomonocytic leukemia. *Foreign Medical Sciences (Blood Transfusion and Hematology)* 2000; 23: 178-181.
- [6] Dvorak CC and Loh ML. Juvenile myelomonocytic leukemia: molecular pathogenesis informs current approaches to therapy and hematopoietic cell transplantation. *Front Pediatr* 2014; 2: 25.

Two reports of JMML and its literature review

- [7] Missero C, Pirro MT and Di Lauro R. Multiple ras downstream pathways mediate functional repression of the homeobox gene product TTF-1. *Mol Cell Biol* 2000; 20: 2783-2793.
- [8] Bollag G, Clapp DW, Shih S, Adler F, Zhang YY, Thompson P, Lange BJ, Freedman MH, McCormick F, Jacks T and Shannon K. Loss of NF1 results in activation of the Ras signaling pathway and leads to aberrant growth in haematopoietic cells. *Nat Genet* 1996; 12: 144-148.
- [9] Locatelli F, Nollke P, Zecca M, Korthof E, Lanino E, Peters C, Pession A, Kabisch H, Uderzo C, Bonfim CS, Bader P, Dilloo D, Stary J, Fischer A, Revesz T, Fuhrer M, Hasle H, Trebo M, van den Heuvel-Eibrink MM, Fenu S, Strahm B, Giorgiani G, Bonora MR, Duffner U and Niemeyer CM. Hematopoietic stem cell transplantation (HSCT) in children with juvenile myelomonocytic leukemia (JMML): results of the EWOG-MDS/EBMT trial. *Blood* 2005; 105: 410-419.
- [10] Steelman LS, Franklin RA, Abrams SL, Chappell W, Kempf CR, Basecke J, Stivala F, Donia M, Fagone P, Nicoletti F, Libra M, Ruvolo P, Ruvolo V, Evangelisti C, Martelli AM and McCubrey JA. Roles of the Ras/Raf/MEK/ERK pathway in leukemia therapy. *Leukemia* 2011; 25: 1080-1094.