

Original Article

Application of delta-shaped anastomosis in totally laparoscopic D2 radical distal gastrectomy

Ketao Jin¹, Jieqing Lv¹, Huanrong Lan², Feng Tao¹

¹Department of Gastrointestinal Surgery, ²Department of Breast and Thyroid Surgery, Shaoxing People's Hospital, Shaoxing Hospital of Zhejiang University, Shaoxing, P. R. China

Received February 23, 2016; Accepted June 4, 2016; Epub February 15, 2017; Published February 28, 2017

Abstract: We presented our preliminary clinical data for totally laparoscopic D2 radical distal gastrectomy using delta-shaped anastomosis (TLG-DSA) to evaluate its effectiveness in terms of minimal invasiveness, technical feasibility, and safety for resection of early gastric cancer. Five consecutive patients who underwent TLG-DSA in our institution from October 22th 2013 to November 29th 2013 were enrolled in this study. In all five cases, only laparoscopic linear staplers were used for intracorporeal anastomosis. There were 3 men and 2 women, with a mean age of 67.6 years and a mean body mass index (BMI) of 21.4. All the patients with early gastric cancer were received TLG-DSA. The mean operation time was 140 minutes, the mean anastomotic time was 19.0 minutes, the mean number of staples used was six, and the mean estimated blood loss was 56 mL. There was no case of conversion to an open procedure. The first flatus was observed at 4.4 days, and liquid diet was started at 5.2 days. The mean postoperative hospital stay was 9.8 days. No postoperative complications were found in all five patients, and no postoperative mortality occurred. TLG-DSA using laparoscopic linear staplers for early gastric cancer was safe and feasible. Delta-shaped anastomosis is a simple, easy and safe method of intracorporeal gastroduodenostomy.

Keywords: Gastrectomy, laparoscopic gastrectomy, totally laparoscopic gastrectomy, gastric cancer, anastomosis

Introduction

As a minimally invasive surgical technique, laparoscopic radical gastrectomy is associated with such advantages as less injury, reduced postoperative pain, lower impact on immune function, milder morbidity, and rapid recovery of gastrointestinal function with a short hospital stay [1-3]. Laparoscopic gastrectomy was commonly performed in our institution for the treatment of early and advanced gastric cancer. With the advances in technology and surgical techniques, totally laparoscopic distal gastrectomy is now can be performed intraabdominally using only endoscopic linear staplers. Totally laparoscopic distal gastrectomy is defined as a method to intracorporeally perform both the resection and anastomosis using the laparoscopic technique [4-7]. Totally laparoscopic distal gastrectomy has several advantages over laparoscopy-assisted distal gastrectomy such as smaller wounds and a lower degree of invasiveness [4].

The delta-shaped anastomosis method was first reported by Kanaya *et al.* [8] in 2002 and then used at some institutions in China [9, 10]. The basic procedure of delta-shaped anastomosis is a Billroth I gastroduodenostomy using only endoscopic linear staplers [8, 9]. Here we presented our initial experience with first five consecutive patients who underwent totally laparoscopic D2 radical distal gastrectomy using delta-shaped anastomosis (TLG-DSA) in our institution from October 22th 2013 to November 29th 2013. We evaluated the effectiveness of TLG-DSA in terms of minimal invasiveness, technical feasibility, and safety for resection of early gastric cancer.

Patients and methods

Patients

Five consecutive patients with early gastric cancer who underwent TLG-DSA in our institution from October 22th 2013 to November 29th 2013 were prospectively enrolled in this study. The

Totally laparoscopic distal gastrectomy

Table 1. Clinical characteristics of 5 patients underwent TLG-DSA

	Case 1	Case 2	Case 3	Case 4	Case 5	Mean \pm SE
Age (years)	73	69	74	59	63	67.6 \pm 2.89
Gender (male/female)	Female	Male	Male	Female	Male	
BMI (kg/m ²)	25.0	20.1	17.0	23.2	21.9	21.4 \pm 1.37

TLG-DSA, totally laparoscopic D2 radical distal gastrectomy using delta-shaped anastomosis. SE, Standard Error of Mean. BMI, body mass index.

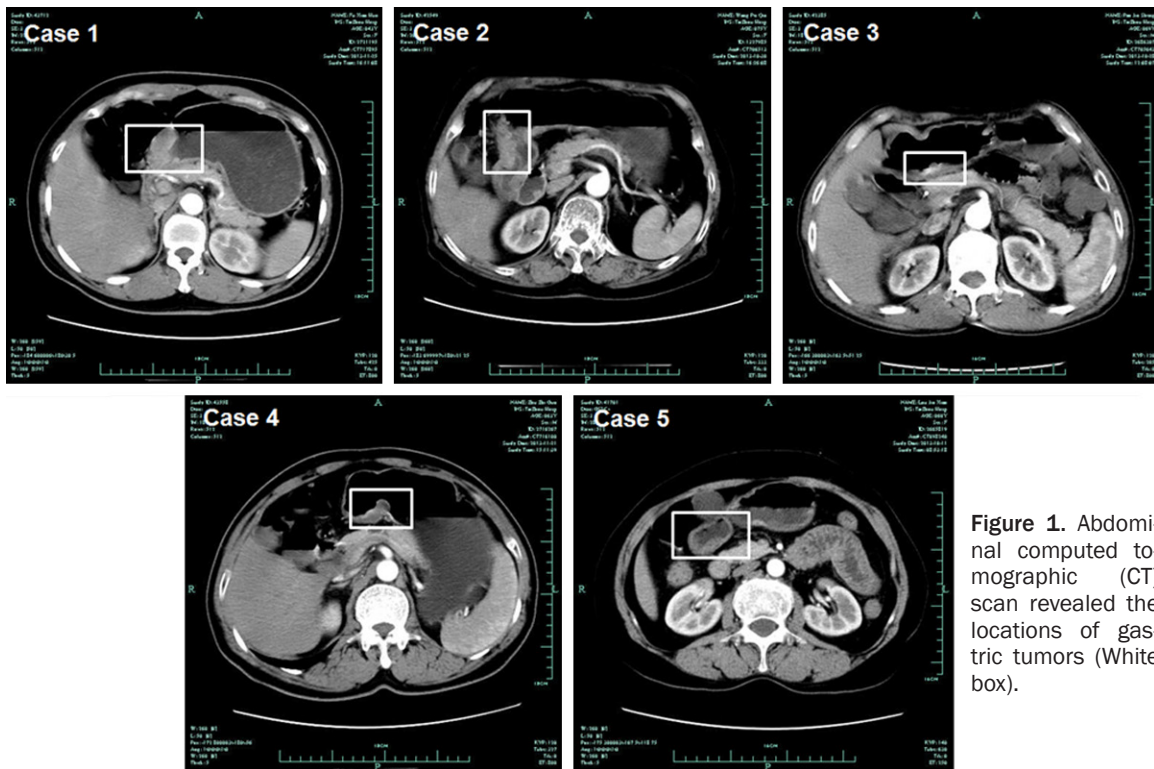


Figure 1. Abdominal computed tomographic (CT) scan revealed the locations of gastric tumors (White box).

characteristics of the patients are shown in **Table 1**. All operations were performed by a single surgeon (Feng Tao or Jieqing Lv) assisted by two of the authors (Ketao Jin or Huanrong Lan). Informed consent was obtained from each patient before surgery in all cases. The study was approved by the Institutional Review Board of Shaoxing Hospital of Zhejiang University. All patients were evaluated preoperatively using endoscopy, abdominal computed tomographic (CT) scan (**Figure 1**) and gastroscopic biopsy. The following clinical data were obtained from the medical and anesthesia records including patient age, gender, body mass index (BMI), operation time, time required for anastomosis, estimated blood loss, number of stapler cartridges used, blood transfusion, days of first flatus and liquid diet, times of analgesic administration except for patient-controlled analgesia, length of postoperative hos-

pital stay, postoperative complications, and pathological findings. Clinical and pathological staging were determined according to the American Joint Committee on Cancer (seventh edition), the tumor-node-metastasis (TNM) classification scheme.

Surgical procedure

After general anesthesia, the patient was put in supine position with the head elevated and legs apart. During the surgery, five trocars were inserted. CO₂ pneumoperitoneum of 12 to 14 mmHg was established. Standing on the left side of the patient, the surgeon divided the stomach and duodenum using an ultrasonic scalpel (UltracisionHarmonic Scalpel; Johnson & Johnson, Cincinnati, USA), and dissected the related lymph nodes according to the 2002 edition of the Gastric cancer treatment guidelines

Totally laparoscopic distal gastrectomy

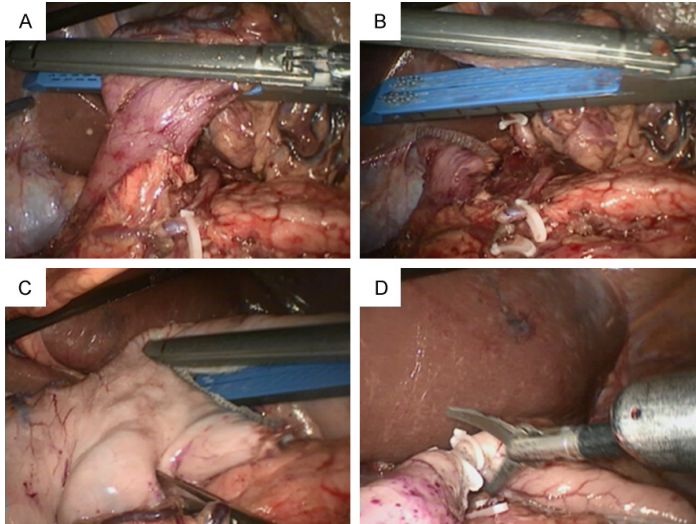


Figure 2. Diagrams showing a 45 mm gastroscopic linear stapler was inserted through the left upper trocar, positioned across the duodenum in the ventrodorsal direction (A) and fired (B); the stomach transected from the greater curvature to the lesser curvature with one (C) or two (D) 60 mm linear staplers.

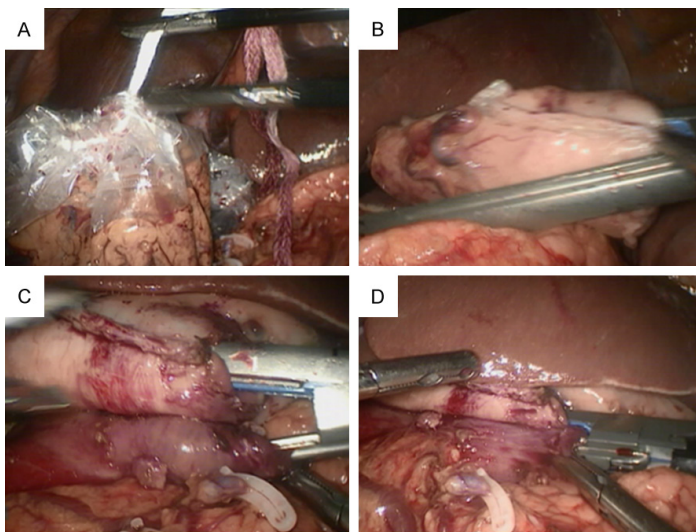


Figure 3. Diagrams showing the stomach and the surrounding tissue are put into a large plastic bag (A); the upper and lower anvils of a 60 mm linear stapler were inserted into one end respectively to close the posterior walls of the stomach (B) and the duodenum (C); the posterior wall of the stomach and that of the duodenum are put together, and the 60 mm linear stapler is closed and fired (D).

in Japan [11]. In brief, firstly, the left side of the gastrocolic ligament was dissected near the transverse colon through to the lower splenic pole and the pancreatic tail. Secondly, the origins of the left gastroepiploic vessels were ligated. The goal was the dissection of stations number 4sb and 4d lymph nodes. Thirdly, the

right side of the gastrocolic ligament was cut near the transverse ligament through to the hepatic flexure, and the hepatic flexure of the colon was separated from the duodenal bulb and the surface of the pancreatic head. In this way, the gastrocolic trunk formed by the right gastroepiploic vein, right colic vein and their confluence could be completely revealed. Fourthly, the right gastroepiploic vessels were transected. The goal was the dissection of stations number 6 lymph nodes. Fifthly, the gastroduodenal artery was exposed and the right gastric artery was transected. The goal was the dissection of stations number 12a and 5 lymph nodes. Sixthly, the three branches of the celiac trunk were divided and the left gastric artery was transected. The goal was dissection of stations number 7, 8a, 9 and 11p lymph nodes. Seventhly, the hepatogastric ligament and the anterior lobe of the hepatoduodenal ligament were transected close to the lower edge of the liver, and the right side of the cardia and the lesser curvature were fully separated. The goal was dissection of stations number 1 and 3 lymph nodes.

After mobilization of the gastroduodenum, a 45 mm gastroscopic linear stapler was inserted through the left upper trocar, positioned across the duodenum in the ventrodorsal direction and fired (**Figure 2A** and **2B**). Consequently, the transection line was rotated approximately 90 degrees from the usual position. The stomach was then transected by successively transecting from the greater curvature to the lesser curvature with one or two 60 mm linear staplers (**Figure 2C** and **2D**).

The resected specimen including the stomach and the surrounding tissue were put into a large plastic bag (**Figure 3A**) and placed beneath the umbilicus.

A small incision was created on the greater curvature side of the remnant stomach and the

Totally laparoscopic distal gastrectomy

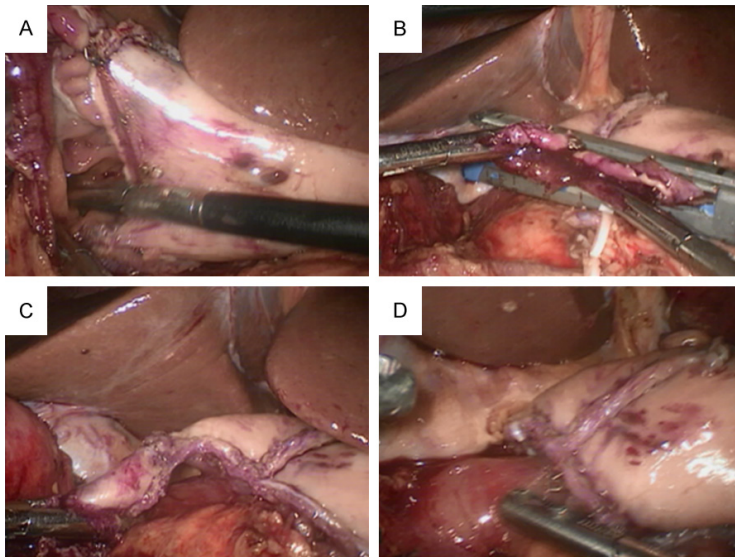


Figure 4. Diagram showing a V-shaped anastomosis is made on the posterior wall (A); the common stab incision closed using one (B) to two (C) of 60 mm endoscopic linear staplers; an intraabdominal Billroth I delta-shaped anastomosis accomplished (D).

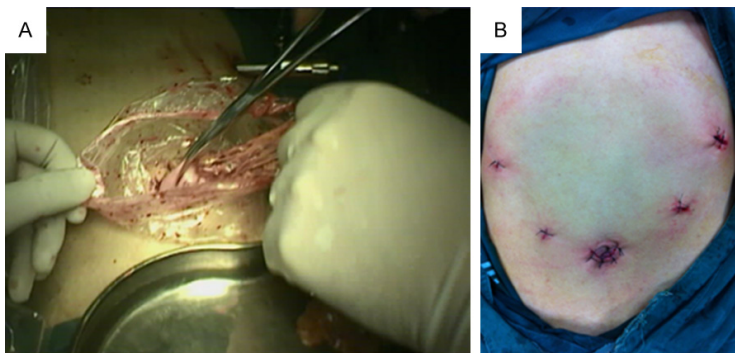


Figure 5. Diagram showing the resected specimen in the large plastic bag removed through the umbilical incision (A). Surgical wounds from totally laparoscopic D2 radical distal gastrectomy using delta-shaped anastomosis (TLG-DSA) (B).

posterior side of the duodenum respectively by the ultrasonic scalpel. The upper and lower anvils of a 60 mm linear stapler were inserted into one end respectively to close the posterior walls of the stomach and the duodenum (**Figure 3B** and **3C**). The posterior wall of the stomach and that of the duodenum were put together, and the 60 mm linear stapler was closed and fired (**Figure 3D**). A V-shaped anastomosis was made on the posterior wall (**Figure 4A**). Upon confirmation of no leakage and bleeding of the anastomosis, the gastric tube was inserted into the distal anastomotic end of the duodenum. Finally, the common stab incision was closed using one to two of 60 mm endoscopic linear

staplers (**Figure 4B** and **4C**). The intraabdominal Billroth I delta-shaped anastomosis was then accomplished (**Figure 4D**).

The resected specimen in the large plastic bag was removed through the umbilical incision extended by cutting the fascia longitudinally with the U-shaped skin incision (**Figure 5A**). Surgical wounds from TLG-DSA were shown in **Figure 5B**.

Results

We performed TLG-DSA in five patients with early gastric carcinoma. The characteristics of the patients reconstructed with delta-shaped anastomosis were summarized in **Table 1**. The surgical outcomes of the five patients were summarized in **Table 2**. The average operation time was 140 minutes, the average time required for the delta-shaped anastomosis was 19 minutes (range 10 to 25 minutes), and the average percentage of the anastomotic time to the operation time was 13.5%. The average number of staples used was six, the estimated blood loss was 56 ml, and no patients received blood transfusion. There was no case of conversion to an open procedure. The first flatus was observed at 4.4 days and liquid diet was started at 5.2 days. The average postoperative

analgesic use was 2.8 times, and the postoperative hospital stay was 9.8 days. There was no intraoperative mortality. None of the patients developed complications such as anastomotic leakage, postoperative hemorrhage, anastomotic stenosis, and delayed gastric emptying and all followed a satisfactory postoperative course (**Table 2**).

The average number of harvested lymph nodes was 24.8, and the average length of the proximal resected margin and distal resection margin were 4.0 cm and 3.8 cm, respectively. Two patients (20.0%) had lymph node metastasis (**Table 3**).

Totally laparoscopic distal gastrectomy

Table 2. Surgical outcomes of 5 patients underwent TLG-DSA

	Case 1	Case 2	Case 3	Case 4	Case 5	Mean ± SE
Operation time (min)	130	125	120	145	180	140.0±10.84
Anastomotic time (min)	15	20	15	20	25	19.0±1.87
Anastomotic time/operation time (%)	11.54	16.0	12.5	13.8	13.9	13.5±0.75
Lymph node dissection	D2	D2	D2	D2	D2	
No. of stapler cartridges used	6	7	6	6	6	6.2±0.20
Estimated blood loss (ml)	50	100	30	50	50	56.0±11.66
First flatus (days)	6	6	3	4	3	4.4±0.68
Liquid diet (days)	6	6	7	4	3	5.2±0.74
Analgesic use (times) ^a	3	3	3	3	2	2.8±0.20
Hospital stay (days)	11	9	9	10	10	9.8±0.37
Transfusion (Yes/No)	No	No	No	No	No	
Open conversion (Yes/No)	No	No	No	No	No	
Complications						
Anastomotic leakage (Yes/No)	No	No	No	No	No	
Postoperative hemorrhage (Yes/No)	No	No	No	No	No	
Anastomotic stenosis (Yes/No)	No	No	No	No	No	
Abdominal abscess (Yes/No)	No	No	No	No	No	
Pulmonary infection (Yes/No)	No	No	No	No	No	
Delayed gastric emptying (Yes/No)	No	No	No	No	No	
Reoperation (Yes/No)	No	No	No	No	No	
Lymphorrhea (Yes/No)	No	No	No	No	No	
Wound infection (Yes/No)	No	No	No	No	No	
Intraoperative mortality (Yes/No)	No	No	No	No	No	

TLG-DSA, totally laparoscopic D2 radical distal gastrectomy using delta-shaped anastomosis. SE, Standard Error of Mean. D2, including stations number 1, 3, 4sb, 4d, 5, 6, 7, 8a, 9, 11p, 12a and 14v lymph nodes. ^a, except for patient-controlled analgesia.

Table 3. Pathologic features of 5 patients underwent TLG-DSA

	Case 1	Case 2	Case 3	Case 4	Case 5	Mean ± SE
Tumor size (cm ²)	12.0	10.5	2.0	3.0	3.0	6.1±2.12
Histologic type						
Well differentiated	–	–	–	–	Well	
Moderately differentiated	–	Moderately	Moderately	Moderately	Moderately	
Poor differentiated	Poor	Poor	–	–	–	
Resected margin (cm)						
Proximal resection margin	4	4	4	4	4	4.0±0.00
Distal resection margin	2	2	6	3	6	3.8±0.92
Depth of wall invasion	Submucosa	Submucosa	Mucosa	Mucosa	Mucosa	
No. of harvested lymph nodes	24	25	30	22	23	24.8±1.39
No. of metastatic lymph nodes	6	3	0	0	0	1.8±1.20
TNM stage	T1bN2M0	T1bN2M0	T1aN0M0	T1aN0M0	T1aN0M0	
AJCC stage	IIA	IIA	IA	IA	IA	

TLG-DSA, totally laparoscopic D2 radical distal gastrectomy using delta-shaped anastomosis. SE, Standard Error of Mean. AJCC, American Joint Committee on Cancer.

Discussion

With less injury and faster postoperative recovery, laparoscopic techniques have been widely

applied in D2 radical gastrectomy for distal gastric cancer. Billroth I anastomosis is a common reconstruction procedure in D2 radical gastrectomy for distal gastric cancer. In 2002, Prof.

Totally laparoscopic distal gastrectomy

Seiichiro Kanaya from Japan Himeji Medical Center first introduced the delta-shaped anastomosis [8], which was a Billroth I side-to-side anastomosis of the posterior walls of the remnant stomach and the duodenum using a laparoscopic linear stapler. During the anastomosis, the staple line was in a “V” shape, which would turn into a triangular shape after the anastomosis was closed, hence the name “delta-shaped anastomosis”. With the advancement of devices for visualization, dissection, and anastomosis, totally intracorporeal procedures are likely to become more popular and used more than laparoscopically assisted techniques. With increasing application of laparoscopic techniques in the D2 radical treatment of distal gastric cancer, the delta-shaped anastomosis has been gradually adopted in China [9, 10].

The purpose of this study was to evaluate the effectiveness of TLG-DSA in terms of minimal invasiveness, technical feasibility, and safety for resection of early gastric cancer. In our initial experience, five consecutive patients who underwent delta-shaped anastomosis were analyzed. Delta-shaped anastomosis is simple and has a wide anastomosis lumen, and does not require an excessive time to be conducted [8, 12]. Oki et al. reported that delta-shaped anastomosis is a safe and feasible procedure, and it requires a shorter operation time and has no associated complications [12]. Our initial work obtained exciting results with a short operation time, a low estimated blood loss, a rapid recovery of gastrointestinal function, a short postoperative hospital stay and no postoperative complications. Our results were comparable with the results from others' clinical work [4, 13]. These initial results obtained mainly due to the surgeon's experience with a high volume of totally laparoscopic distal gastrectomy cases. And our initial results also demonstrated the technical feasibility and safety of TLG-DSA.

In conclusion, the application of delta-shaped anastomosis with a linear stapler as part of the intraperitoneal Billroth I reconstruction is safe and feasible, allowing satisfying postoperative recovery and outcomes. Our clinical experience indicated that the delta-shaped anastomosis is a simple, easy and safe method of intracorporeal gastroduodenostomy.

Acknowledgements

This work was supported by National Natural Science Foundation of China (Grant No. 81374014) and Zhejiang Provincial Medical and Healthy Science and Technology Projects (Grant No. 2013KYA228).

Disclosure of conflict of interest

None.

Address correspondence to: Drs. Ketao Jin and Feng Tao, Department of Gastrointestinal Surgery, Shaoxing People's Hospital, Shaoxing Hospital of Zhejiang University, 568 Zhongxing North Road, Shaoxing 312000, Zhejiang Province, P. R. China. E-mail: jinketao2001@zju.edu.cn (KTJ); dr.taofeng@aliyun.com (FT)

References

- [1] Kim HH, Hyung WJ, Cho GS, Kim MC, Han SU, Kim W, Ryu SW, Lee HJ, Song KY. Morbidity and mortality of laparoscopic gastrectomy versus open gastrectomy for gastric cancer: an interim report—a phase III multicenter, prospective, randomized Trial (KLASS Trial). *Ann Surg* 2010; 251: 417-420.
- [2] Mochiki E, Kamiyama Y, Aihara R, Nakabayashi T, Asao T, Kuwano H. Laparoscopic assisted distal gastrectomy for early gastric cancer: Five years' experience. *Surgery* 2005; 137: 317-322.
- [3] Kim YW, Baik YH, Yun YH, Nam BH, Kim DH, Choi IJ, Bae JM. Improved quality of life outcomes after laparoscopy-assisted distal gastrectomy for early gastric cancer: results of a prospective randomized clinical trial. *Ann Surg* 2008; 248: 721-727.
- [4] Ikeda O, Sakaguchi Y, Aoki Y, Harimoto N, Taomoto J, Masuda T, Ohga T, Adachi E, Toh Y, Okamura T, Baba H. Advantages of totally laparoscopic distal gastrectomy over laparoscopically assisted distal gastrectomy for gastric cancer. *Surg Endosc* 2009; 23: 2374-2379.
- [5] Guzman EA, Pigazzi A, Lee B, Soriano PA, Nelson RA, Benjamin Paz I, Trisal V, Kim J, Ellenhorn JD. Totally laparoscopic gastric resection with extended lymphadenectomy for gastric adenocarcinoma. *Ann Surg Oncol* 2009; 16: 2218-2223.
- [6] Song KY, Park CH, Kang HC, Kim JJ, Park SM, Jun KH, Chin HM, Hur H. Is totally laparoscopic gastrectomy less invasive than laparoscopy-assisted gastrectomy?: prospective, multicenter study. *J Gastrointest Surg* 2008; 12: 1015-1021.

Totally laparoscopic distal gastrectomy

- [7] Huscher CG, Mingoli A, Sgarzini G, Brachini G, Binda B, Di Paola M, Ponzano C. Totally laparoscopic total and subtotal gastrectomy with extended lymph node dissection for early and advanced gastric cancer: early and long-term results of a 100-patient series. *Am J Surg* 2007; 194: 839-844; discussion 844.
- [8] Kanaya S, Gomi T, Momoi H, Tamaki N, Isobe H, Katayama T, Wada Y, Ohtoshi M. Delta-shaped anastomosis in totally laparoscopic Billroth I gastrectomy: new technique of intraabdominal gastroduodenostomy. *J Am Coll Surg* 2002; 195: 284-287.
- [9] Zhang J. Delta-shaped anastomosis in totally laparoscopic D2 radical distal gastrectomy. *Chin J Cancer Res* 2013; 25: 463-464.
- [10] Huang CM, Lin JX, Zheng CH, Li P, Xie JW, Wang JB, Lu J, Chen QY. [Application of delta-shaped anastomosis in totally laparoscopic distal gastrectomy]. *Zhonghua Wei Chang Wai Ke Za Zhi* 2013; 16: 140-143.
- [11] Nakajima T. Gastric cancer treatment guidelines in Japan. *Gastric Cancer* 2002; 5: 1-5.
- [12] Oki E, Sakaguchi Y, Ohgaki K, Saeki H, Chinen Y, Minami K, Sakamoto Y, Toh Y, Kusumoto T, Maehara Y. Feasibility of delta-shaped anastomoses in totally laparoscopic distal gastrectomy. *Eur Surg Res* 2011; 47: 205-210.
- [13] Kanaya S, Kawamura Y, Kawada H, Iwasaki H, Gomi T, Satoh S, Uyama I. The delta-shaped anastomosis in laparoscopic distal gastrectomy: analysis of the initial 100 consecutive procedures of intracorporeal gastroduodenostomy. *Gastric Cancer* 2011; 14: 365-371.