Int J Clin Exp Med 2016;9(2):2961-2968
www.ijcem.com /ISSN:1940-5901/IJCEM0017129

Original Article

PFNA with reduction assisted with pointed clamp and cable cerclagefor select subtrochanteric fractures of the femur

Jinpeng Gong[1,2*], Yong Yang[1,3*], Pengcheng Liu[1*], Xiaoyang Nie[1,2], Renlong Li[1,2], Jiezhou Wu[1,4], Qi Sun[1], Wei Ge[1,4], Ming Cai[1]

[1]Department of Orthopedics, Shanghai Tenth People's Hospital, School of Medicine, Tongji University, Shanghai 200072, P. R. China; [2]Department of Medical, Soochow University, Suzhou 215123, Jiangsu, P. R. China; [3]Department of Traumatic Orthopedic, General Hospital of Ningxia Medical University, Yinchuan 750004, Ningxia, P. R. China; [4]Department of First Clinical Medical College, Nanjing Medical University, Nanjing 210029, Jiangsu, P. R. China. [*]Equal contributors.

Received September 30, 2015; Accepted December 19, 2015; Epub February 15, 2016; Published February 29, 2016

Abstract: Purpose: The purpose of this study was to evaluate a series of select subtrochanteric fractures who were treated with PFNA with reduction assisted with pointed clamp and cable cerclage and to determine the effect of this technique on reduction quality, and to provide our recommendations. Methods: Between August 2011 and February 2013, 13 patients with a subtrochanteric femoral fracture (six oblique fractures and seven spiral fractures) were treated with PFNA with reduction assisted with pointed clamp. If loss of reduction occurred after release the forceps, a supplementary cable cerclage was used to restore displacement. Radiographs were evaluated for the quality of the reduction and fracture union progress. The functional outcome was assessed by Harris hip score. All patients were followed up for at least 12 months. Results: All 13 fractures were healed at an average of 20 weeks (range 16-24 weeks). Five fractures occurred loss of reduction after release the forceps, and a single cable was used for each of those patients. The mean neck-shaft angle was restored to within 5°, and the average translation decreased from 2.05 cm preoperatively to 0.15 cm postoperatively. All patients achieved a good or excellent functional result with a mean Harris hip score of 90.7 (range 83-95). After follow-up of at least 12 months, no patient had a symptomatic leg length discrepancy or rotational malunion. Conclusion: Treatment of subtrochanteric fractures with reduction assisted with pointed clamp and cable cerclage and PFNA fixation techniques can result in preferable reductions and a high union rate.

Keywords: Limited incision, clamp-assisted reduction, cable cerclage, PFNA, subtrochanteric fracture

Introduction

Subtrochanteric fractures of the femur are defined as the fractures occurred in the region extending from the lesser trochanter to 5 cm distal to the lesser trochanter [1, 2]. Subtrochanteric fractures have been reported up to 7% to 34% of all femoral fractures [3, 4]. The incidence of subtrochanteric fractures shows a pattern of double-peaked age curve. Younger patients experience subtrochanteric fractures from high energy trauma, typically from axial compression and rotation. High-energy trauma has been reported to cause 77% of subtrochanteric fractures [5]. In elderly patients, falling from a standing height directly onto the hip can also lead to a subtrochanteric fracture. Subtrochanteric fractures of the femur that are caused by low-energy trauma are less common [6].

It has been reported by many authors [7-10] that subtrochanteric fractures may be the most challenging of all fractures of the femur. They have often been associated with complications of fracture healing and mechanical failures [11]. The basic reason for this is the complex mechanical function in this region of the femur where special mechanical stresses and strains are located [12]. There is normally good bal-

Figure 1. Preoperative antero-posterior images: A. A 58-year-old man with an oblique subtrochanteric fracture of the femur. B. A 76-year-old man with a spiral subtrochanteric fracture of the femur.

ance between body weight, gravity and the locomotion system in this particular region, allowing the force to be distributed distally [13]. Many authors have reported the intramedullary nail to be the most mechanically and biologically advantageous therapeutical modality in the treatment of subtrochanteric fractures [7, 14, 15]. While the reduction of oblique and spiral fractures in the subtrochanteric area still provide a technically difficult operative procedure if attempting to treat the fracture with intramedullary nailing [16]. Clamp-assisted reduction of high subtrochanteric fractures of the femur has been shown to result in excellent union and alignment. Loss of reduction also provide a challenge for this technique [17, 18], and cable cerclage has also been shown to result in excellent results of restoring displacement [19, 20]. The purpose of this study was to evaluate a series of oblique and spiral subtrochanteric fractures that were treated with reduction assisted with pointed clamp and cable cerclage and to determine the effect of this technique on reduction quality and functional outcome, and we would like to provide our recommendations of this technique.

Patients and methods

Between August 2011 and February 2013, we included 13 patients with a mean age of 61.2 years (range, 43-76 years) who underwent the technique of reduction assisted with pointed clamp and cable cerclage and intramedullary nail for oblique and spiral subtrochanteric fracture of the femur (AO class 32-A1.1, 32-B1.1 and 32-C1.1) at department of Orthopaedics Traumatology, Shanghai tenth people's hospital, Tongji University, Shanghai, China (**Figure 1**). We excluded the patients who had a transverse fracture or comminuted fracture (range, AO class 32-C1.2 to 32-C3.3), which could not captured by the pointed clamp. For obvious reasons, any patient whose fracture reduced anatomically with closed reduction was also excluded.

Of the 31 subtrochanteric fractures we treated between August 2011 and February 2013, only 13 patients met our inclusion criteria in terms of fracture configuration and incomplete anatomical reduction, following use of technique of reduction assisted with pointed clamp and cable cerclage and intramedullary nail.

Technique

The surgery was performed with the patient supine on a fracture table, after a muscle relaxant and a general anesthetic. Prophylactic antibiotics, typically a second generation cephalosporin (Cefuroxime, 1.5 g), were given. Gentle traction was placed on the limb, and the fracture was visualized in two planes fluoroscopically to evaluate the status of deformities of abduction, flexion, and rotation. Before draping, the length and rotation of the fracture was restored by using traction under fluoroscopy guidance. With this step, the alignment of fracture line should be achieved in at least one plane, often sagittal plane. This is critical since the alignment in one plane allows the reduction of fracture assisted by pointed clamp in the other plane.

After locating under fluoroscopy guidance, a 3-5 cm incision was made at the tip pointing towards the proximal fragment. The incision was extended deeper through the fascia lata through blunt dissection and the vastus latera-

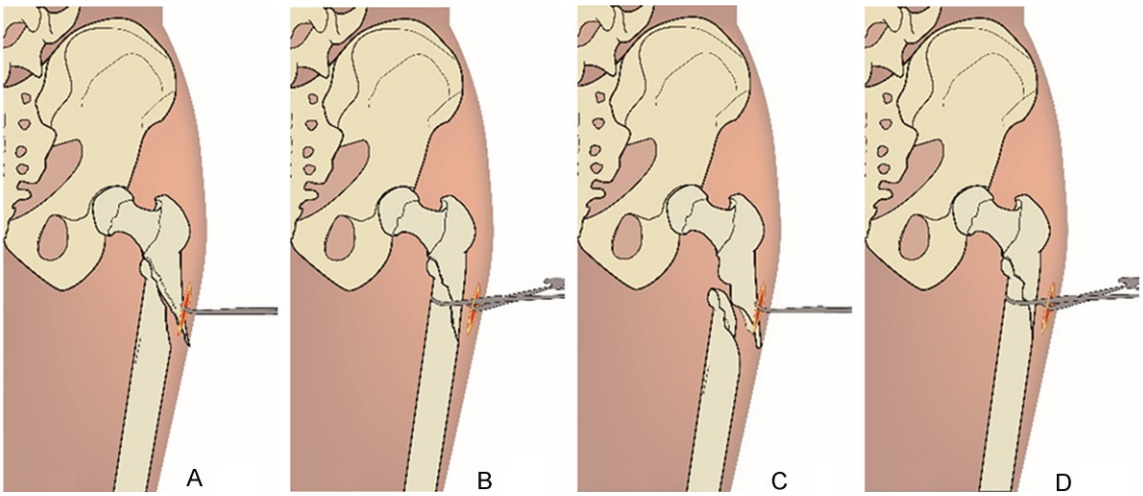

Figure 2. Diagram of reduction assisted with limited incision combined with pointed clamp: A, B. Reduction of oblique subtrochanteric fracture of the femur. C, D. Reduction of spiral subtrochanteric fracture of the femur.

Figure 3. A 58-year-old man with an oblique subtrochanteric fracture of the femur. Loss of reduction occurred after release the prongs; a supplementary cable cerclage was used.

lis muscle was split, the fracture margins were palpated to estimate the direction of displacement. If the lateral soft tissue was damaged by fracture trauma, then the approach was made through the space of damaged tissue to avoid additional tissue injury. With adjusting traction, anatomical reduction was achieved under palpating. Subsequently, a 180 mm AO pointed reduction clamp was inserted parallel to the femoral shaft, with the prongs closed, and then advanced until it reached the medial cortex. Then, the clamp was turned 90° and the prongs were opened slowly over the surface of the bone until they captured and compressed the fracture. The accuracy of reduction was evaluated by performing fluoroscopy in both coronal and sagittal planes (**Figure 2**).

Intramedullary nailing was performed while keeping the reduction forceps in place until distal locking was complete. If intramedullary nailing was failed to perform through the incision used for reduction, then an incision was made in the lateral aspect of the thigh just distal to the lateral prominence of the greater trochanter, and the incision used for reduction was gently tamped with gauzes to decrease bleeding. All nails were statically locked with one or two distal locking screws. We used theproximal femoral nail antirotation (PFNA, Synthes®, Oberdorf, Switzerland) device for all patients. The nails and proximal locking configuration were based on the fracture pattern.

If loss of reduction occurred after release the forceps, then, the incision was prolonged with 2 cm and a supplementary cable cerclage was applied to maintain reduction (**Figure 3**).

Patients were treated with administration of LMW-heparin 4000 u once a day to prevent thrombosis during staying in the hospital.

Table 1. Background information on the patients enrolled in the study

Case no.	Age	Injury cause	Associated injury	AO/OTA class	Oblique/ spiral	IM nail	Cable no.	Operation time (min)	Union time (weeks)	LLD (mm)	Coronal alignment	Sagittal alignment	Function*
1	46	Traffic accident	Tibial fracture	32-C 1.1	Oblique	PFNA	1	128	23	-8	3° varus	2° flexion	89
2	57	Fall	None	32-C 1.1	Spiral	PFNA	0	100	18	-3	Neutral	Neutral	91
3	71	Traffic accident	Radial fracture	32-A 1.1	Oblique	PFNA	0	104	17	0	Neutral	Neutral	95
4	69	Fall	None	32-B 1.1	Oblique	PFNA	1	120	19	0	2° varus	2° extension	90
5	54	Fall	None	32-B 1.1	Spiral	PFNA	0	85	20	0	Neutral	Neutral	92
6	43	Fall	None	32-B 1.1	Spiral	PFNA	0	90	16	-2	Neutral	Neutral	93
7	74	Traffic accident	None	32-C 1.1	Oblique	PFNA	1	135	24	0	Neutral	Neutral	95
8	76	Fall	Spine fracture	32-A 1.1	Spiral	PFNA	0	80	23	0	5° varus	3° flexion	85
9	58	Traffic accident	Pelvic injury & chest trauma	32-C 1.1	Oblique	PFNA	1	125	19	0	Neutral	Neutral	91
10	67	Fall	None	32-B 1.1	Spiral	PFNA	0	92	20	0	Neutral	Neutral	91
11	63	Fall	None	32-B 1.1	Spiral	PFNA	0	90	21	0	2° valgus	3° extension	83
12	70	Traffic accident	Foot fractures	32-C 1.1	Oblique	PFNA	1	119	22	-6	Neutral	Neutral	89
13	48	Fall	None	32-A 1.1	Spiral	PFNA	0	97	18	0	Neutral	3° flexion	95
Mean	61.2							105	20	-1.5			90.7

PFNA proximal femoral nail antirotation (PFNA, Synthes®, Oberdorf, Switzerland); *LLD* leg-length discrepancy. *Assessed by Harris hip score.

Patients were discharged after sutures were cut. For the first six weeks, patients were allowed to bear weight as tolerated with two-arm support. Then they were progressed to use a cane as tolerated. Radiographs were made immediately postoperatively, at six weeks, at three months, and as needed afterward if union had not occurred. All patients were followed up for 12 months or more. Final clinical outcomes were evaluated using the Harris hip score system (excellent > 90-100, good 80-89, fair 70-79, poor < 70), which is based on pain, function, deformity and range of motion assessments.

Results

Of all 13 cases included in this study, cause of injury was traffic accidents (5 patients) and falls (8 patients). Five patients suffered associated injury, which included tibial fracture, radial fracture, spine fracture, foot fractures, pelvic injury and chest trauma like rib fractures. No patient had an open fracture, and there was no major neurovascular injury. Numbers of fracture types (according to the AO/OTA classification) were: three of 32-A1.1, five of 32-B1.1, and five of 32-C1.1. There were six oblique fractures and seven spiral fractures.

Average operation time was 105 min (range 85-135 min). Proximal femoral nail antirotation (PFNA, Synthes®, Oberdorf, Switzerland) were used for all patients. Nail lengths ranged between 280 and 380 mm, and diameters between 9 and 11 mm. Five fractures occurred loss of reduction after release the forceps, and a single cable was used for each of those patients. All 13 fractures were healed at 24 weeks (mean 20 weeks, range 16-24 weeks). There was no major complication, such asinfection, implant failure, or nonunion encountered. At ultimate follow-up visits, the mean neck-shaft angle was restored to within 5°, and the average translation decreased from 2.05 cm preoperatively to 0.15 cm postoperatively.

All patients achieved a good or excellent functional result with a mean Harris hip score of 90.7 (range 83-95). After follow-up of at least 12 months, no patient had a symptomatic leg length discrepancy or rotational malunion at the time of follow-up (**Table 1**).

Discussion

Intramedullary nailing is considered the most preferred method in the treatment of subtrochanteric femoral fractures, especially in unstable fractures such as oblique and spiral trochanteric fractures [21-28]. It is well known that the nailing of subtrochanteric fractures should be performed after reduction of the proximal fragment in order to avoid malunion and nonunion [29]. However, the adherence of the strong muscles to the femoral proximal region in closed displacement causes major issues in cases of subtrochanteric fractures [30-33]. The proximal fragment is displaced to the anterior by the traction of the iliopsoas muscle, to the lateral by the effect of the gluteus medius muscle and the distal fragment is displaced to the medial by the influence of the adductor longus and magnus muscles. Therefore, the reduction and loss of reduction of the subtrochanteric fracture still provide a challenge.

Blocking screws were used to assist the reduction of subtrochanteric fractures [34, 35]. While blocking screws were also reported to maintaining the placement and increase fracture fixation [36, 37]. Cable cerclage was introduced to provide a more permanent effect for reduction [38]. This instrument was reported to warrant a larger incision and cause injury to the soft tissues and the periosteal circulation [39]. However, another study suggest that the periosteal vascular supply is circumferential, rather than longitudinal, with multiple musculo-periosteal vessels nourishing the periosteal layer [40]. Therefore, one cerclage cableshould have limited deleterious effect on the periosteal vascularity ofthe entire oblique or spiral subtrochanteric fracture [20, 41]. Thus, we used cable cerclage for our patients who met loss of reduction after release the prongs and the fractures healed well after 12 months. Afsari et al. [36] recommended reduction with a small incision at the lateral using a bone clamp, and Park and Young [37] recommended assisting reduction withlong hemostatic forceps.

For the selected cases in our study, we used pointed reduction clamp with a limited incision and achieved a preferable result (all fractures united and no patient had a symptomatic limb length discrepancy or rotational malunion). During operation, we made a limited incision

and a approach through damaged tissue to avoid additional tissue injury and fracture devascularization. Under fluoroscopy guidance and finger palpating, the traction was adjusted several times to achieve anatomic reduction. We used pointed clamp to assist reduction in order to avoid additional damage of periosteum and nonunion.

Loss of reduction after release the prongs cannot be surprised with this technique. This can be due to residual toggling movement between the screw and the nail or nail-entry portal mismatch [36]. The effect of the gluteus medius muscle also contributes to this displacement. For the five patients who med loss of reduction, the application of cable cerclages restored all those displacements. And all those fractures healed well without any symptomatic deformity.

In recent years, the AO/ASIF group improved the PFNA device to develop the angular and rotational stability. The spiral blade claims to compact the cancellous bone to increase stability and this has been biomechanically proven to retard rotation and medial bone cortex collapse. Biomechanical tests also demonstrated a higher cut out resistance in the osteoporotic bone compared to commonly used screw systems [42, 43]. Therefore, we used PFNA for our cases.

There are many limitations of this study. First, it was a case series without a control group and the number of the patients was small. Second, information on blood loss and intraoperative radiation exposure time were not available in sufficient detail to allow comparison of other techniques. Third, this technique we introduced cannot be used in cases with severely comminuted fractures and transverse fractures.

In summary, we would like to emphasise that reduction assisted withpointed clamp and cable cerclage and PFNA of oblique and spiral subtrochanteric fractures, which can improve the quality of reduction and fixation. Although the technique seems simple, to master this technique, surgeons need attentively analysis of the fracture status and attention to the details of the surgical technique described in this article. And we would like to provide our recommendations of this technique:

(1) Computed tomography with three dimensional reconstructions can be helpful in obtaining the fracture morphology and making a reasonable plane of operation.

(2) All potential material needed for reduction and fixation must be prepared (clamps, PFNA device, cerclage cable, etc.) prior to surgery.

(3) With traction, the reduction of length should be achieved firstly, the alignment of fracture line should be achieved in at least one plane.

(4) The approach could be made through the space of damaged tissue to avoid additional tissue injury if thelateral soft tissue is damaged by fracture trauma.

(5) Palpating with finger on the fracture margins can be helpful in guiding traction.

(6) If the incision used for performing intramedullary nailing is not same to the incision used for reduction, then, in order to decrease bleeding, one incision should be gently tamped with gauzes when the other is under operating.

(7) Reduction forceps should be kept in place until distal locking was complete.

(8) If loss of reduction occurs after release the forceps, a supplementary cable cerclage can beapplied to restore displacement.

(9) Following up is necessary. And additional procedures may be necessary, especially for nonunion.

Disclosure of conflict of interest

None.

Address correspondence to: Ming Cai, Department of Orthopaedics, Shanghai Tenth People's Hospital, No. 301, School of Medicine, Tongji University, Middle Yanchang Road, Shanghai 200072, China. E-mail: orthopedics_dsyy@163.com

References

[1] Chan K, MacDermid JC, Faber KJ, King GJ and Athwal GS. Can we treat select terrible triad injuries nonoperatively? Clin Orthop Relat Res 2014; 472: 2092-2099.

[2] Fardiazar Z, Hajizadeh K, Dinparvar S and Esmaili F. Thromboembolism and Thrombosis

during Pregnancy and After Delivery between 2009 and 2012 in Al-Zahra Educational Center. J Caring Sci 2014; 3: 221-226.
[3] Adib-Hajbaghery M, Lotfi MS, Rezaee-Shahsavarloo Z and Sadat Mousavi M. The Incidence of Hypertension and the Follow-Up Rate in A Sample of Population Over 30 Years Old in Kashan 2013. J Caring Sci 2014; 3: 211-219.
[4] Pirela-Cruz MA and Samocha Y. Posterolateral subluxation exposure of the elbow for injuries involving the lateral column. Hand (N Y) 2013; 8: 491.
[5] Charalambous CP, Stanley JK, Mills SP, Hayton MJ, Hearnden A, Trail I and Gagey O. Comminuted radial head fractures: aspects of current management. J Shoulder Elbow Surg 2011; 20: 996-1007.
[6] van Riet RP and Morrey BF. Documentation of associated injuries occurring with radial head fracture. Clin Orthop Relat Res 2008; 466: 130-134.
[7] Fowler JR and Goitz RJ. Radial head fractures: indications and outcomes for radial head arthroplasty. Orthop Clin North Am 2013; 44: 425-431, x.
[8] Zhang C, Zhong B and Luo CF. Treatment strategy of terrible triad of the elbow: Experience in Shanghai 6th People's Hospital. Injury 2014; 45: 942-948.
[9] Lill H, Korner J, Rose T, Hepp P, Verheyden P and Josten C. Fracture-dislocations of the elbow joint-strategy for treatment and results. Arch Orthop Trauma Surg 2001; 121: 31-37.
[10] Pugh DM and McKee MD. The "terrible triad" of the elbow. Tech Hand Up Extrem Surg 2002; 6: 21-29.
[11] Pugh DM, Wild LM, Schemitsch EH, King GJ and McKee MD. Standard surgical protocol to treat elbow dislocations with radial head and coronoid fractures. J Bone Joint Surg 2004; 86: 1122-1130.
[12] Lindenhovius AL, Jupiter JB and Ring D. Comparison of acute versus subacute treatment of terrible triad injuries of the elbow. J Hand Surg 2008; 33: 920-926.
[13] Rodriguez-Martin J, Pretell-Mazzini J, Andres-Esteban EM and Larrainzar-Garijo R. Outcomes after terrible triads of the elbow treated with the current surgical protocols. A review. Int Orthop 2011; 35: 851-860.
[14] Leigh WB and Ball CM. Radial head reconstruction versus replacement in the treatment of terrible triad injuries of the elbow. J Shoulder Elbow Surg 2012; 21: 1336-1341.
[15] Rotini R, Marinelli A, Guerra E, Bettelli G and Cavaciocchi M. Radial head replacement with unipolar and bipolar SBi system: a clinical and radiographic analysis after a 2-year mean follow-up. Musculoskelet Surg 2012; 96 Suppl 1: S69-79.
[16] Berschback JC, Lynch TS, Kalainov DM, Wysocki RW, Merk BR and Cohen MS. Clinical and radiographic comparisons of two different radial head implant designs. J Shoulder Elbow Surg 2013; 22: 1108-1120.
[17] Afsari A, Liporace F, Lindvall E, Infante A Jr, Sagi HC and Haidukewych GJ. Clamp-assisted reduction of high subtrochanteric fractures of the femur. J Bone Joint Surg Am 2009; 91: 1913-1918.
[18] Yoon YC, Jha A, Oh CW, Durai SK, Kim YW, Kim JH and Oh JK. The pointed clamp reduction technique for spiral subtrochanteric fractures: a technical note. Injury 2014; 45: 1000-1005.
[19] Kim JW, Park KC, Oh JK, Oh CW, Yoon YC and Chang HW. Percutaneous cerclage wiring followed by intramedullary nailing for subtrochanteric femoral fractures: a technical note with clinical results. Arch Orthop Trauma Surg 2014; 134: 1227-1235.
[20] Kennedy MT, Mitra A, Hierlihy TG, Harty JA, Reidy D and Dolan M. Subtrochanteric hip fractures treated with cerclage cables and long cephalomedullary nails: a review of 17 consecutive cases over 2 years. Injury 2011; 42: 1317-1321.
[21] Giannicola G, Sacchetti FM, Antonietti G, Piccioli A, Postacchini R and Cinotti G. Radial head, radiocapitellar and total elbow arthroplasties: a review of recent literature. Injury 2014; 45: 428-436.
[22] Herz-Ruelas ME, Gomez-Flores M, Moxica-Del Angel J, Miranda-Maldonado I, Gutierrez-Villarreal IM, Guerrero-Gonzalez GA, Villarreal-Rodríguez AO. Ulcerated Radiodermatitis Induced after Fluoroscopically Guided Stent Implantation Angioplasty. Case Rep Dermatol Med 2014; 2014: 768624.
[23] Herz-Ruelas ME, Gómez-Flores M, Moxica-Del Angel J, Miranda-Maldonado I, Gutiérrez-Villarreal IM, Guerrero-González GA, Villarreal-Rodriguez AO. Ulcerated Radiodermatitis Induced after Fluoroscopically Guided Stent Implantation Angioplasty. Case Rep Dermatol Med 2014; 2014: 768624.
[24] Reichel LM, Milam GS, Hillin CD and Reitman CA. Osteology of the coronoid process with clinical correlation to coronoid fractures in terrible triad injuries. J Shoulder Elbow Surg 2013; 22: 323-328.
[25] Adams JE, Sanchez-Sotelo J, Kallina CFt, Morrey BF and Steinmann SP. Fractures of the coronoid: morphology based upon computer tomography scanning. J Shoulder Elbow Surg 2012; 21: 782-788.
[26] Mellema JJ, Doornberg JN, Dyer GS and Ring D. Distribution of coronoid fracture lines by specific patterns of traumatic elbow instability. J Hand Surg Am 2014; 39: 2041-2046.
[27] Sormaala MJ, Sormaala A, Mattila VM and Koskinen SK. MDCT findings after elbow dislo-

cation: a retrospective study of 140 patients. Skeletal Radiol 2014; 43: 507-512.
[28] Yong WJ, Tan J, Adikrishna A, Lee HJ, Jung JW, Cho DW and Jeon IH. Morphometric analysis of the proximal ulna using three-dimensional computed tomography and computer-aided design: varus, dorsal, and torsion angulation. Surg Radiol Anat 2014; 36: 763-768.
[29] Kataoka T, Moritomo H, Miyake J, Murase T and Sugamoto K. Three-dimensional suitability assessment of three types of osteochondral autograft for ulnar coronoid process reconstruction. J Shoulder Elbow Surg 2014; 23: 143-150.
[30] Hartzler RU, Llusa-Perez M, Steinmann SP, Morrey BF and Sanchez-Sotelo J. Transverse coronoid fracture: when does it have to be fixed? Clin Orthop Relat Res 2014; 472: 2068-2074.
[31] Papatheodorou LK, Rubright JH, Heim KA, Weiser RW and Sotereanos DG. Terrible triad injuries of the elbow: does the coronoid always need to be fixed? Clin Orthop Relat Res 2014; 472: 2084-2091.
[32] Alolabi B, Gray A, Ferreira LM, Johnson JA, Athwal GS and King GJ. Reconstruction of the coronoid process using the tip of the ipsilateral olecranon. J Bone Joint Surg Am 2014; 96: 590-596.
[33] Ring D, Guss D and Jupiter JB. Reconstruction of the coronoid process using a fragment of discarded radial head. J Hand Surg Am 2012; 37: 570-574.
[34] Toros T, Ozaksar K, Sugun TS, Kayalar M, Bal E and Ada S. The effect of medial side repair in terrible triad injury of the elbow. Acta Orthop Traumatol Turc 2012; 46: 96-101.
[35] Fitzgibbons PG, Louie D, Dyer GS, Blazar P and Earp B. Functional outcomes after fixation of "terrible triad" elbow fracture dislocations. Orthopedics 2014; 37: e373-376.
[36] Chemama B, Bonnevialle N, Peter O, Mansat P and Bonnevialle P. Terrible triad injury of the elbow: how to improve outcomes? Orthop Traumatol Surg Res 2010; 96: 147-154.
[37] Rodriguez-Martin J, Pretell-Mazzini J, Andres-Esteban EM and Larrainzar-Garijo R. Outcomes after terrible triads of the elbow treated with the current surgical protocols. A review. Int Orthop 2011; 35: 851-860.
[38] McKee MD, Schemitsch EH, Sala MJ and O'Driscoll SW. The pathoanatomy of lateral ligamentous disruption in complex elbow instability. J Shoulder Elbow Surg 2003; 12: 391-396.
[39] Karuppiah SV and Knox D. Elbow dislocation with complete triceps avulsion. Case Rep Orthop 2014; 2014: 636504.
[40] Pazzaglia UE, Congiu T, Raspanti M, Ranchetti F and Quacci D. Anatomy of the intracortical canal system: scanning electron microscopy study in rabbit femur. Clin Orthop Relat Res 2009; 467: 2446-2456.
[41] Finsen V. The effect of cerclage wires on the strength of diaphyseal bone. Injury 1995; 26: 159-161.
[42] Mereddy P, Kamath S, Ramakrishnan M, Malik H and Donnachie N. The AO/ASIF proximal femoral nail antirotation (PFNA): a new design for the treatment of unstable proximal femoral fractures. Injury 2009; 40: 428-432.
[43] Simmermacher RK, Ljungqvist J, Bail H, Hockertz T, Vochteloo AJ, Ochs U and Werken C. The new proximal femoral nail antirotation (PFNA) in daily practice: results of a multicentre clinical study. Injury 2008; 39: 932-939.