Int J Clin Exp Med 2016;9(2):5068-5070
www.ijcem.com /ISSN:1940-5901/IJCEM0016496

Case Report

A secret path: severe deep neck space infection led to axilla and lateral chest abscesses

Fan Zeng[1,2*], Qi Zhou[3*], Peng Zhou[3], Min Wu[4], Hong Tang[1,2]

[1]Center of Infectious Diseases, West China Hospital of Sichuan University, Chengdu 610041, China; [2]Division of Infectious Diseases, State Key Laboratory of Biotherapy, Sichuan University, Chengdu 610041, China; [3]Department of Otorhinolaryngology, Head & Neck Surgery, West China Hospital, Sichuan University, China; [4]Medical Imaging Center, West China Hospital, Sichuan University, China. [*]Equal contributors.

Received September 20, 2015; Accepted December 4, 2015; Epub February 15, 2016; Published February 29, 2016

Abstract: Background: Deep neck space infections (DNSI) are significantly less common today than in the past. But acute severe neck abscesses are still associated with significant morbidity and mortality rates due to lack of seasonable diagnosis and treatment. Case Report: we present a rare patient with severe deep neck space infection, the abscesses spread a covert way led to axilla and lateral chest abscesses through the pre-vertebral space. Following multiple surgical procedure and antimicrobial therapy, the patient made a full recovery. Conclusion: Severe deep neck space infections usually spread to the mediastinum, anterior chest wall easily. However, because of the most insidious pre-vertebral space, the axilla and left lateral chest wall also should to be paid attention in clinical. Using corticosteroids on patient with deep neck space infections should be cautious, or else it will make the infection spread and deteriorate. Multidisciplinary of diagnosis and therapy in severe deep neck space infections may recognize again by Clinicians.

Keywords: Deep neck space infection, abscess, pre-vertebral space

Introduction

Although deep neck space infections (DNSI) are significantly less common today than in the past since the advent and widespread diffusion of antibiotics, acute severe neck abscesses are still associated with significant morbidity and mortality rates due to the lack of infrastructure and medical staff at the primary health level [1, 2].

DNSI can be caused by infections originating from the head, oral, dental, by primary or secondary infection of the cervical lymph nodes or thyroid gland, or by infected congenital cysts [3]. Without effective treatments for the infections, DNSI will spread rapidly through the anatomical structure, cause severe septic and even develop to the life threatening condition. When it was occurred, not only ENT doctors, but multiple departments, e.g., thoracic surgeon, infectious disease doctors, intensive care unit (ICU) doctors might join also.

We herein describe one extremely rare case of severe deep neck space infections. Its severity and diffusion path have limited been reported so far, it is worth being concerned by clinicians

Case presentation

A 51-year-old male was transferred to our hospital with the complaints of persistent fever, odynophagia, mild dyspnea, dysphagia and right-sided neck swelling. He had visited a remote county hospital next to our province and been prescribed penicillin and dexamethasone for 7 days. His disease was diagnosed by the local physician as acute epiglottitis. The patient was referred to our medical center emergency room when he had gradually developing trismus, odynophagia and dyspnea. After admission, the patient supplement complained to the left armpit and lateral chest pain significantly. On physical examination, the patient showed a fluctuating approximate 10*10-cm mass from submental to the edge of the sternum, with red and hot

Figure 1. Abscess in neck.

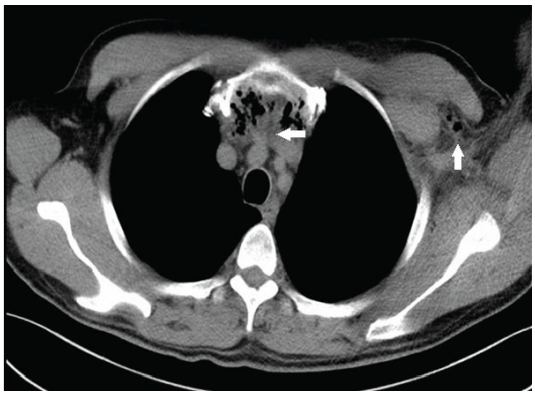

Figure 2. Abscesses in superior mediastinum and left axilla.

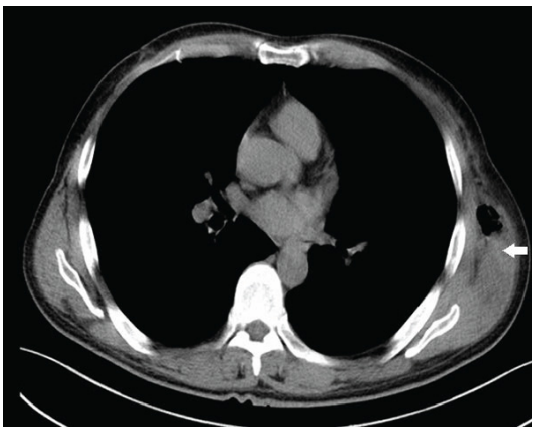

Figure 3. Abscess in lateral chest wall.

overlying skin and intense pain at palpation, local bulging, tenderness in the left lateral chest wall at the proximal axillary. Blood tests showed severe infection and slightly prolong clotting time. Emergency computerized tomography (CT) of the neck and chest showed: Parapharyngeal, retropharyngeal space, bilateral neck, superior mediastinum, left supraclavicular fossa, left axilla and lateral chest wall widely pneumatosis, flocculent shape shadow and effusion (**Figures 1**-**3**).

Considering the widespread infection, we performed surgical incision and drainage.

After the preoperative preparation finishing, the patient was taken to the operating room, in which under general anesthesia the abscess was drained via both submandibular and supraclavicular incisions. Thoracic surgeon helped to deal the lateral chest wall abscess via incision drainage. After operation, the patient stayed in surgery-intensive-care unit (SICU) 2 days to get symptomatic and supportive treatment. A regimen of intravenous piperacillin-tazobactam was begun at the same time. The patient was not on fever, but his laboratory test results didn't show improvement. On postoperative day 4, the culture taken from the submandibular-neck and from the left axilla-lateral chest wall abscess was positive for penicillin-resistant Streptococcus pneumonia. The antibiotic therapy was changed to ceftriaxone sodium based on the sensitivities of cultured organisms. Following another 14 days, the abscess drainage and laboratory tested items with infection were significantly reduced. The patient was transferred back to the region hospital for continue treatment. One month later we got a message that the patient fully recovered.

Discussion

Base on the evidence which was described by Grodinsky and Holyoke, infection may spread from one space to another. The various deep neck space infections may involve retropharyngeal space, parapharyngeal space, pre-vertebral space, submandibular space, etc [4]. If the spread of infection from retropharyngeal space occurs towards the mediastinum, due to the communication between media and deep facial layers with mediastinum, mortality rates will increase [5]. A patient with extension of a serious infection from the masticator space, retropharyngeal space communicates with parapharyngeal space to the mediastinum isn't rare indeed [6, 7]. However, spontaneous drainage of deep neck abscesses through the pre-vertebral space to axillary sheath and lateral chest wall, to our best knowledge, limited been described in literature and met in clinical [8]. The symptom and sign of axillary sheath and lateral chest wall from our reported case above are

less obvious than his neck's, it also reminded our physicians that carefully inquiry, physical examination as important as CT scan at any time.

Timely, effective use of antibiotics and early surgical intervention decreases morbidity and mortality in case of Deep neck abscess has been widely recognized [8, 9]. The microbiology of theses abscesses are involving aerobic and anaerobic bacteria. Predominant aerobic isolated are S, aureus (including MARSA), group A β-hemolytic streptococcus (GABHS) streptococcus spp, anaerobes organisms include porphyromonas, fusobacterium Spp, Prevotella [10]. Due to the irrational use of medicines in some rural areas, the resistance to antimicrobials has significantly increases that made the treatment of the infections more challenging. Early appropriate administration of antimicrobials is required. The choice of antimicrobials should consider the situation of resistant bacteria in the region and be adjusted once the identification of the causative organism(s).

Meanwhile, it is necessary to notice that the use of corticosteroids must be careful. Though it can relieve inflammation, anti-shock, prevent the airway compromise due to edema or abscess, but also may cause the spread of infections as the case we present before [9].

Learning point

Sever deep neck space infections usually spread to the mediastinum, anterior chest wall easily. However, because of the most insidious pre-vertebral space, the axilla and left lateral chest wall also should to be paid attention in clinical.

When choosing appropriate antimicrobial agents, the situation of resistant bacteria in the region should be considered.

Using corticosteroids on patient with deep neck space infections should be cautious, or it will make the infection spread and deteriorate.

Multidisciplinary of diagnosis and therapy in severe deep neck space infections may recognize again by Clinicians.

Acknowledgements

Thanks are due to professor Wen Li from ENT and attending Jia Hu from department of Thoracic and Cardiovas for assistance with the surgery.

Disclosure of conflict of interest

None.

Address correspondence to: Dr. Hong Tang, Center of Infectious Diseases, West China Hospital of Sichuan University, Chengdu 610041, China; Division of Infectious Diseases, State Key Laboratory of Biotherapy, Sichuan University, Chengdu 610041, China. Tel: +862885422650; Fax: +862885422650; E-mail: htang6198@hotmail.com

References

[1] Parhiscar A, Har-El G. Deep neck abscess: A retrospective review of 210 cases. Ann Otol Rhinol Laryngol 2001; 11: 1051-4.
[2] Meher R, Jain A, Sabharwal A, Gupta B, Singh I, Agarwal AK. Deep neck abscess: a prospective study of 54 cases. J Laryngol Otol 2005; 119: 299-302.
[3] Biron A, Halperin D, Sichel JY, Eliashar R. Deep neck abscess of dental origin draining through the external ear canal. Otolaryngol Head Neck Surg 2005; 133: 166-7.
[4] Kulkarni AH, Pai SD, Bhattarai B, Rao ST, Ambareesha M. Ludwig's angina and airway considerations: a case report. Cases J 2008; 201: 1759-1621.
[5] Smith JL 2nd, Hsu JM, Chang J. Predicting deep neck space abscess using computed tomography. Am J Otolaryngol 2006; 27: 244-7.
[6] Hazenberg AJ, Pullmann LM, Henke RP, Hoppe F. Recurrent neck abscess due to a bronchogenic cyst in an adult. J Laryngol Otol 2010; 124: 1325-8.
[7] Izzi-Engbeaya C, Zac-Varghese S, Palazzo F, Sanderson F, Meeran K, Dhillo WS. A young fit man presenting to the emergency department with a painful neck due to a thyroid abscess. QJM 2013; 106: 1041-2.
[8] Boyanova L, Kolarov R, Gergova G, Deliverska E, Madjarov J, Marinov M, Mitov I. Anaerobic bacteria in 118 patients with deep-space head and neck infections from the University Hospital of Maxillofacial Surgery, Sofia, Bulgaria. J Med Microbiol 2006; 55: 1285-19.
[9] Page C, Biet A, Zaatar R, Strunski V. Parapharyngeal abscess: diagnosis and treatment. Eur Arch Otorhinolaryngol 2008; 265: 681-6.
[10] Brook I. Anaerobic bacteria in upper respiratory tract and head and neck infections: microbiology and treatment. Anaerobe 2012; 18: 214-220.